

# Multiple Intra-Cranial Hemorrhages After Carotid Endarterectomy

Ashfaq Shuaib, K. Michael Hunter and Melvin A. Anderson

**ABSTRACT:** Intra-cerebral hemorrhage is an unusual and often fatal complication of endarterectomy (CEA). Previous cerebral infarction, intra-operative or post operative hypertension, and the use of anti-coagulants are some of the defined major risk factors. Hemorrhage usually occurs early after CEA, and a second hemorrhage has only once been reported. We wish to report a patient who developed three separate hemorrhages following CEA. This patient had a long history of poorly controlled hypertension. We believe that poorly controlled hypertension, in addition to other reported factors, may be an important separate risk factor for post-CEA hemorrhage.

**RÉSUMÉ:** Hémorragies intracrâniennes multiples après une endartérectomie carotidienne L'hémorragie intracérébrale est une complication rare et souvent fatale de l'endartérectomie (EAC). Un infarctus cérébral antérieur, de l'hypertension perou post-opératoire et l'utilisation d'anticoagulants sont considérés comme des facteurs de risque importants. L'hémorragie survient habituellement tôt après l'EAC et une deuxième hémorragie n'a été rapportée qu'une seule fois. Nous rapportons le cas d'un patient qui a présenté trois épisodes séparés d'hémorragie après EAC. Ce patient avait une longue histoire d'hypertension mal contrôlée. Nous croyons que l'hypertension mal contrôlée, en plus des autres facteurs de risque connus, peut constituer un facteur de risque indépendant important de l'hémorragie post-EAC.

*Can. J. Neurol. Sci. 1989; 16: 345-347*

Carotid endarterectomy (CEA) is a common procedure for management of symptomatic carotid disease.<sup>1</sup> Complications have decreased in recent years due to proper selection of patients and better surgical techniques. Post-CEA intra-cerebral hemorrhage is a rare complication that carries a grave prognosis.<sup>2,3</sup> Although the time interval between surgery and the hemorrhage may vary from a few hours to several months, most hemorrhages occur within 7 days of surgery. Most hemorrhages occur if surgery is performed within four weeks of cerebral infarction.<sup>2-6</sup> There are however cases with hemorrhage occurring up to 14 months after the cerebral infarction (Ref 3 case 4). Hypertension in the post-operative period has been proposed as a risk factor for post-CEA hemorrhage.<sup>7</sup> Post-CEA hypertension occurs in 29-56 percent of patients,<sup>8,9</sup> and unfortunately cannot be predicted, as it appears to have no relationship to pre-operative blood pressure, the timing of angiography, the angiographic or operative findings, the use of internal shunts, or the use of other features of the anesthesia or operation.<sup>9</sup> The hemorrhage commonly occurs within a previous infarction and the territory of the artery operated upon.

There is only a single report of a patient in whom two hemorrhages developed, two days and 8 weeks after CEA. In this communication we wish to report a patient who developed multiple intra-cerebral hemorrhages after CEA. Multiple intra-cerebral hemorrhages have not been previously reported with CEA.

## CASE REPORT

A 56 year old female was initially assessed by a neurologist at another hospital for right sided facial and arm weakness. There was a history of poorly controlled hypertension and a ilio-femoral bypass five years earlier. General examination showed mild hypertension and a bruit over the left carotid artery. Mild upper motor neuron weakness was present in the right arm, otherwise the neurological examination was normal. Three days later a cranial CT scan was done that showed a right parietal lobe infarction. Because of progressive right arm weakness, the patient was heparinized and later started on coumadin. Anti-coagulants were discontinued one month later.

The patient was initially seen by one of us (KMH) 8 weeks after the episode, and a carotid angiogram 13 weeks after the infarction showed 95 percent stenosis of the left carotid artery in a two centimeter segment of the internal carotid artery just distal to the bifurcation. Neurological examination remained unchanged from 13 weeks earlier.

From the Department of Clinical Neurosciences, Foothills Hospital and Calgary General Hospital, University of Calgary (A.S., K.M.H.); the Department of Pathology, Calgary General Hospital (M.A.A.)

This work was completed at the Calgary General Hospital, Calgary, AB, Canada. Dr. Shuaib is a fellow of the Medical Research Council of Canada, and the Alberta Heritage Foundation for Medical Research.

Received October 1, 1988. Accepted in final form March 1, 1989

Reprint requests to: Dr. Ashfaq Shuaib, Duke-VA Center for Cerebrovascular Research, VA Medical Center, Durham, NC 27705, U.S.A.

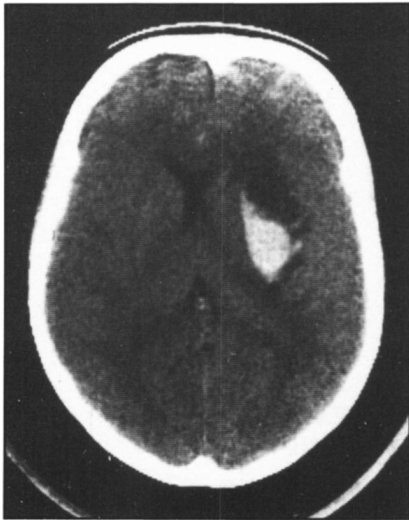


Figure 1 — This figure of the initial cranial CT scan done within 24 hours of the carotid endarterectomy shows a hemorrhage in the basal ganglion and internal capsule region.

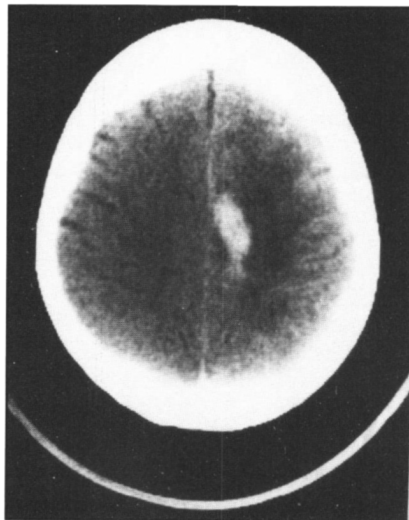

Figure 2 — This cranial CT scan reveals the second hemorrhage, involving the area adjacent to the inter-hemispheric fissure on the left side.

Carotid endarterectomy was done without complications. Post-operative examination showed no new deficits. One and a half hours later the patient developed a right hemiplegia and aphasia. Blood pressure was monitored during this period and had remained normal. Immediate return to surgery showed the carotid artery to be patent. Cranial CT scan done 24 hours later showed a hemorrhage in the left internal capsule and putamen region (see Figure 1). Gradual improvement in strength was followed by a second episode of weakness on the right side. Repeated CT scan showed a second hemorrhage in an area adjacent to the inter-hemispheric fissure, medial to the area of infarction (see Figure 2).

Four days after the CEA, the patient developed a seizure that began focally on the right side and then rapidly generalized. Cranial CT done after the seizure showed a third hemorrhage (see Figure 3), separate from the previous two hemorrhages, this time in the region of the old cerebral infarction. Because of a progressive decrease in the level of

consciousness, the hematomas in the left basal ganglion and the frontoparietal region were evacuated.

Subsequent course in the hospital was unfortunately downhill and the patient died 10 days after CEA. Terminally the course was complicated by diabetes insipidus and hypertension. The hypertension and associated bradycardia were felt to be secondary to the increased intracranial pressure.

At autopsy all three hemorrhages were clearly identified (see Figure 4). Only one hemorrhage involved the previous infarction. The other two hemorrhages were located in previously normal brain parenchyma. The right hemisphere was normal and the CEA site was patent. Intracerebral vasculature showed microscopic hypertensive changes in the normal parenchyma diffusely and in close proximity to the hemorrhages. No micro-aneurysms were found in any blood vessels. Blood vessel walls were negative for amyloid.

#### DISCUSSION

Post-CEA hemorrhage is uncommon with an incidence of 0.4-0.6 percent,<sup>2,15</sup> and its etiology remains poorly understood.

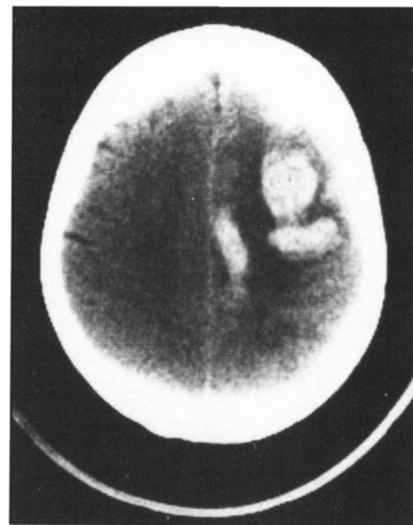

Figure 3 — Cranial CT scan after the third hemorrhage; this time the hemorrhage involves the area of the previous cerebral infarction.

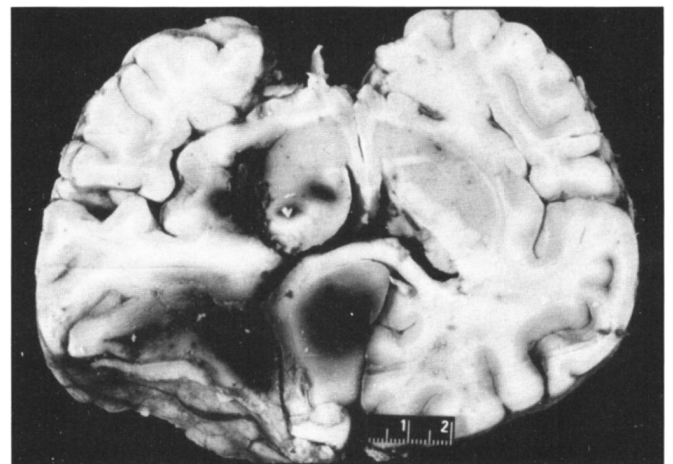


Figure 4 — This brain section shows the extent of the hematomas in the brain tissue at autopsy.

Factors that increase the risks for post-CEA hemorrhage include surgery soon after a stroke or a T.I.A.,<sup>1,2</sup> peri-operative hypertension,<sup>2,7,14,18</sup> hypertension after CEA,<sup>4,16</sup> the use of anti-coagulants<sup>10</sup> and the presence of severe long standing carotid stenosis prior to CEA.<sup>3</sup>

Several mechanisms have been proposed to explain the intra-cerebral hemorrhage after CEA. Most hemorrhages develop in regions of previously infarcted brain tissue. It has therefore been suggested that damaged blood vessels within this region are susceptible to rupture after blood flow is restored.<sup>2,6</sup> This has led to the practice of not performing CEA early in the post-infarction period. Caplan et al. in 1978 reviewed the literature on post-CEA hemorrhage.<sup>7</sup> They postulated that a sudden increase in the blood pressure in the immediate post-CEA may be an important factor leading to post-CEA hemorrhage. Therefore rigid control of blood pressure in the immediate post-operative period would help in decreasing the frequency of this complication. Several studies have shown an increase in blood flow, sometimes as much as 200% after CEA.<sup>15</sup> In many cases there is an increase in headache or the new onset of "vascular" headaches after CEA (Cluster{11}, Migraine{15}) and convulsions<sup>12,13</sup> and these are believed to be secondary to the increase in cerebral perfusion. More recently Bernstein et al.<sup>4</sup> reported a case where the post-CEA hemorrhage had occurred in previously normal brain tissue. Prior to the hemorrhage the patient had developed severe headaches, facial pain and convulsions immediately after the CEA. A break down in the auto-regulation similar to that seen with hypertensive encephalopathy was suggested as a possible mechanism. From the spectrum of neurological symptoms it would appear that there may be a continuum of severity with the mildly affected cases presenting with only headache while more seriously affected patients develop intra-cerebral hemorrhage. In cases developing hemorrhage the presence of a previous cerebral infarction, hypertension (peri or post operative), and the tightness of the carotid occlusion are additional risk factors.

Most reported cases have had a single hemorrhage after the CEA. In our patient, three separate hemorrhages, with two in previously normal parenchyma, were seen. We propose an additional possible risk factor that could explain this. Autopsy studies of intra-cerebral arteries in patients with long standing hypertension have shown the presence of multiple micro-aneurysms on the blood vessels. These are located on the 100-300 micron branches of the striate and cortical perforating branch arteries.<sup>19,20</sup> These aneurysms are commonly located in the basal ganglion and up to 30 percent may be found in the gray-white junction of the cerebral cortex.<sup>20</sup> In hypertensive subjects their numbers range from 15-25, and measure up to two mm in size. The walls of the aneurysms are composed of connective tissue only.<sup>19</sup> It has been previously suggested that deficiency of blood flow, accompanying high grade carotid stenosis, creates a situation where the resistance vessels of the cerebral circulation maximally dilate to increase local blood flow.<sup>3</sup> With time these blood vessels become atonic and lose their capacity for auto-regulation. After CEA there is a sudden rise in the intra-arterial pressure within these small vessels and the associated micro-aneurysms that had remained protected during the time of low blood flow. The increase in blood flow

could then possibly result in disruption of the aneurysm wall and subsequent hemorrhage. As patients with hypertension have multiple aneurysms, it is possible that more than one hemorrhage could also be seen. The presence of long standing poorly controlled hypertension prior to CEA may thus be an additional risk factor that in combination with other risk factors mentioned earlier may increase the potential for post-CEA hemorrhages. As was seen in our case, these hemorrhages could rarely be multiple. No aneurysms were however seen in our case, and therefore the possibility of multiple hemorrhages secondary to rupture of micro-aneurysm remains only a speculative hypothesis.

## REFERENCES

1. Wylie EJ, Ehrenfeld WK. Extra-cranial occlusive cerebrovascular disease. Philadelphia, WB Saunders Co 1970.
2. Breutman ME, Fields WS, Crawford ES, et al. Cerebral hemorrhage in carotid artery surgery. Arch Neurol 1963; 9: 458-467.
3. Solomon RA, Loftus CM, Quest DO, et al. Incidence and etiology of intracerebral hemorrhage following carotid endarterectomy. J Neurosurg 1986; 64: 29-43.
4. Bernstein M, Fleming JFR, Deck JHN. Cerebral hyperfusion after carotid endarterectomy. A cause of cerebral hemorrhage. Neurosurgery 1984; 15: 50-56.
5. Hass WK, Clauss RH, Goldberg AF, et al. Special problems associated with surgical and thrombolytic treatments of strokes. Arch Surg 1966; 92: 27-31.
6. Wylie EJ, Hein MF, Adams JE. Intracranial hemorrhage following surgical revascularization for the treatment of acute strokes. J Neurosurg 1964; 21: 212-215.
7. Caplan LR, Skillman J, Ojemann R, et al. Intra-cerebral hemorrhage following carotid endarterectomy. A hypertensive complication. Stroke 1978; 9: 457-460.
8. Wade JG, Larson CP Jr, Hickey RF, et al. Effects of carotid endarterectomy on carotid chemoreceptors and baroreceptors in man. N Eng J Med 1970; 282: 823-828.
9. Lehv MS, Salzman EW, Silen W. Hypertension complicating carotid endarterectomy. Stroke 1970; 1: 307-313.
10. Spetzler RF, Wilson CB, Weinstein P, et al. Normal perfusion pressure breakthrough theory. Clin Neurosurg 1978; 25: 651-672.
11. Messert B, Black JA. Cluster headache, hemicrania, and other head pains: Morbidity of carotid endarterectomy. Stroke 1978; 9: 559-562.
12. Wilkinson JT, Adams HP, Wright CB. Convulsions after carotid endarterectomy. J.A.M.A. 1980; 244: 1827-1828.
13. Dolan JG, Mushlin AI. Hypertensive vascular headaches and seizures after carotid endarterectomy. Arch Int Med 1984; 144: 1489-1491.
14. Towne JB, Bernhard VM. Relationship of post-operative blood pressure to complications of carotid endarterectomy. Surgery 1980; 88: 575-580.
15. Sundt TM Jr, Sharbrough FW, Piepgras DG, et al. Correlation of cerebral blood flow and electroencephalographic changes during carotid endarterectomy: With results of surgery and hemodynamics of cerebral ischemia. Mayo Clin Proc 1981; 56: 533-543.
16. Sundt TM Jr. The ischemic tolerance of neural tissue and the need for monitoring and selective shunting during carotid endarterectomy. Stroke 1983; 14: 93-98.
17. Cosgrove GR, Leblanc R, Meager-Villemure K, et al. Cerebral amyloid angiopathy. Neurology 1985; 35: 625-631.
18. Bland JE, Chapman RD, Wylie EJ. Neurological complication of carotid artery surgery. Ann Surg 1970; 171: 459-464.
19. Russel RWR. Observations on intra-cerebral aneurysms. Brain 1963; 86: 425-442.
20. Cole FM, Yates PO. Intra-cerebral micro-aneurysms and small cerebrovascular lesions. Brain 1967; 90: 759-768.