

# Monoamniotic Twins: What Should Be the Optimal Antenatal Management?

Ashis K. Sau<sup>1</sup>, Kate Langford<sup>1</sup>, Catherine Elliott<sup>1</sup>, Lin L. Su<sup>2</sup>, and Darryl J. Maxwell<sup>1</sup>

<sup>1</sup>Fetal Medicine Unit, St. Thomas' Hospital, London, UK

<sup>2</sup>National University Hospital, Singapore

Monoamniotic twinning is a rare event with an incidence of 1% of all monozygotic twins and associated with a high fetal morbidity and mortality. Confident early diagnosis is possible, but optimal management is not yet established. This article presents the experience of a single centre in managing all monoamniotic twins diagnosed during 1994–2000. Seven pairs of monoamniotic twins were identified for analysis. All were managed in accord with a unit protocol that involved early diagnosis, serial ultrasound examination and elective early delivery. In four cases, the detection of monoamnioticity was made during a first trimester nuchal scan. Discordance for structural abnormality was found in three cases where the co-twin was normal. Cord entanglement was detected antenatally in four cases. Two pairs of twins died before 20 weeks. One of these had early onset twin–twin transfusion syndrome. In five cases, the pregnancy continued beyond 20 weeks. A live birth rate of 90% and intact survival of 70% were achieved in this group. We believe that ultrasound is reliable in diagnosing monoamniotic twins and the detection of cord entanglement. Timing of elective delivery is a balance between the risks of preterm birth at a specific gestational age in an individual centre compared with the unquantifiable risks of fetal death if an expectant policy were pursued. The decision to deliver and at which gestational age should combine input from the parents, neonatologist, fetal medicine consultant and the obstetrician.

Monoamniotic twinning is a rare event, with an incidence of 1% of all monozygotic twins, and is associated with a high fetal morbidity and mortality (Allen et al., 2001; Salerno, 1959; Tessen & Zlantic, 1991). Causes of fetal morbidity and mortality include cord entanglement, twin–twin transfusion syndrome (TTTS) and an increased incidence of fetal structural abnormalities. Increasingly, monoamniotic twinning is being identified at the time of first trimester scan, which allows these pregnancies to be closely monitored. While this has increased our knowledge of prognosis in this condition, outcome measures are still poor and optimal management has not yet been established. In this article we present the outcome of 7 consecutive cases of monoamniotic twinning. Our review illustrates the range of problems, which may be found in this condition, and we attempt to define clinical parameters important in managing these pregnancies.

## Methods

All cases in this series presented to and were scanned in the tertiary referral fetal medicine unit at our institution between 1994 and 2000. Our local population is inner

London with a high proportion of socially deprived and black, Asian or mixed race peoples. Management protocols employed were those of early detection of chorionicity and amnioticity, 2-weekly serial ultrasound surveillance and early delivery by elective cesarean section at around 32 weeks gestation. From 1997, a formal twin ultrasound surveillance clinic was established and first trimester nuchal translucency screening was performed. The same fetal medicine consultant had clinical input into the management of all cases. A summary of the cases can be seen in Table 1.

## Case 1

A 36-year-old woman in her third pregnancy was referred to our unit at 23 weeks with a suspected cardiac problem in one of the twins. Scans performed in the fetal medicine (FMU) and fetal cardiology units (FCU) confirmed the diagnosis of transposition of the great arteries with ventriculo-septal defect in twin B of monochorionic monoamniotic twins. The umbilical cords of both twins were inserted about 4 cm apart into an anterior placenta. An amniocentesis was performed at 24 weeks and confirmed a normal karyotype. At 26 weeks, the parents requested private medical care, which necessitated transfer to a fetal medicine unit in another hospital. A scan later in pregnancy demonstrated cord entanglement over most of their length except for the last 10 cm or so prior to the fetal insertion. Management was thereafter as an in-patient with daily CTG (cardiotocograph) and twice-weekly measurement of umbilical artery Doppler. Prophylactic Sulindac was used to achieve borderline oligohydramnios to lessen the risk of cord entanglement. She was delivered by elective cesarean section at 32 weeks gestation in the presence of mature Lecithin Sphingomyelin ratio (L/S ratio).

Marked cord entanglement was noted at delivery with the cords wrapped and knotted around each other several times. The baby with the cardiac defect (Twin B) weighed 1580g and the normal twin (Twin A) weighed 1700g. Twin A did well and had a normal neonatal echocardiogram. Twin B had banding of the pulmonary trunk and ligation of the large arterial duct at 3 weeks of age. A balloon atrial septostomy was required two days later. A stormy post-operative

*Address for correspondence: A.K. Sau, Fetal Medicine Unit, 8th Floor, North wing, St. Thomas' Hospital, London, SE1 7EH, UK. Email: ashis@sau3.freeserve.co.uk*

**Table 1**

Outcomes of Prenatally Detected Monoamniotic Twins

Case No.	Maternal age (years)	Gestational age at diagnosis (weeks)	Scan findings	Gestational age at delivery (weeks)	Indication for delivery	Delivery findings	Perinatal outcome
1	36	23	Cord entanglement at 23 weeks Twin B — cardiac defect	32	Elective	Marked cord entanglement Cardiac defect of Twin B	Twin A — well Twin B — Infant death
2	33	20	Bladder exstrophy of one twin	34	Elective	Bladder exstrophy confirmed	Both twins alive and well
3	23	17	Cord entanglement at 28 wks	32	Elective	Cord entanglement	1 alive 1 IUFD at 31 <sup>6</sup> weeks
4	27	13	No cord entanglement	14	IUFD	TTTS	IUFD × 2
5	33	12	Cord entanglement at 19 wks	30	Elective	Marked cord entanglement	Both twins alive and well
6	28	12	No cord entanglement	19	IUFD	Cord entanglement present	IUFD x 2
7	28	13	Cord entanglement at 18 weeks, Twin A -CHB of twin	32	Elective	Marked cord entanglement	Twin A neonatal death Twin B alive and well

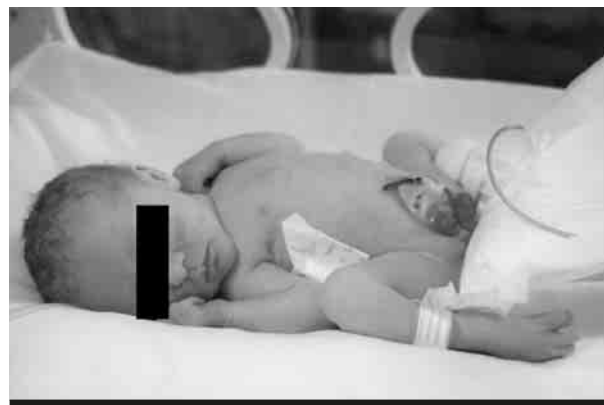Note: IUFD = Intrauterine fetal death, CHB = Congenital heart block

course was followed by recovery. This baby died later as a result of pneumococcal meningitis.

### Case 2

A 33-year-old woman in her first ongoing pregnancy was referred to FMU at 20 weeks after one twin was thought to have an exomphalos. A scan in the FMU confirmed a diagnosis of monoamniotic twins with one twin having a choroid plexus cyst on the right side and the other twin an echogenic focus in the left ventricle plus a small anterior abdominal wall defect. This defect was initially thought to be an exomphalos containing small bowel only. Fetal blood sampling was performed from the intra-hepatic vein of the twin with exomphalos and the karyotype was that of a normal female. Serial monitoring persistently failed to demonstrate fetal bladder filling over several weeks. A cautious presumptive diagnosis of bladder exstrophy was made. The parents were referred to a paediatric surgeon for prenatal discussion of postnatal management.

The pregnancy continued to be monitored for adequate fetal growth and to look for evidence of cord entanglement. No cord entanglement was identified. An amniocentesis was performed at 33 weeks to ascertain the L/S ratio, which indicated fetal lung maturity. Delivery by elective cesarean section was undertaken at 34 weeks on 26th November 1996. Both babies weighed around 1900g. A diagnosis of monoamniotic twins was confirmed at cesarean section and by placental histology. The twin with exomphalos was confirmed to have bladder exstrophy (Figure 1) and was operated on at one week of age. Both twins were discharged in good condition and did well.



**Figure 1**  
Newborn with bladder exstrophy.

### Case 3

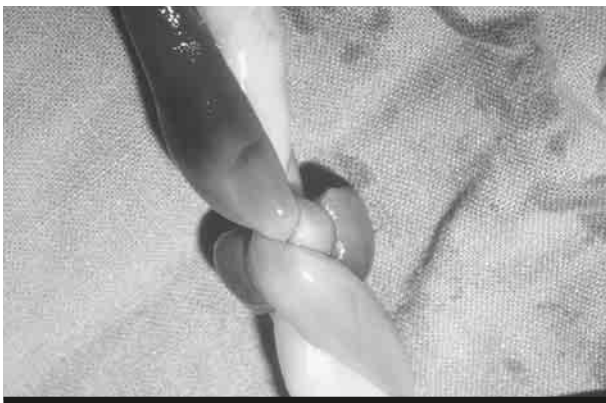
Monoamniotic twinning was diagnosed at 17 weeks in a 23-year-old woman in her fourth pregnancy. Two-weekly scans were performed to check fetal growth and look for evidence of cord entanglement. Fetal growth was adequate with cord entanglement first noted at 28 weeks. Joint discussion between parents, fetal medicine consultant and neonatologist resulted in delivery by elective cesarean section at 32 weeks following administration of steroids. Unfortunately, when the mother was admitted the evening before the planned cesarean one twin was found to be dead.

Uncertainty with regard to the risk of neurological sequelae in the surviving twin was discussed but elective delivery was performed since it was considered that there was still a

risk of death to the surviving twin from cord entanglement. At delivery the cord of the stillborn twin was noted to be tightly knotted around the cord of the live twin (Figure 2) but still allowing full perfusion in the survivor. The birthweight of the live twin was 1880g and that of the stillborn 1530g. The live born baby was initially admitted to the Special Care Baby Unit and discharged later without complication.

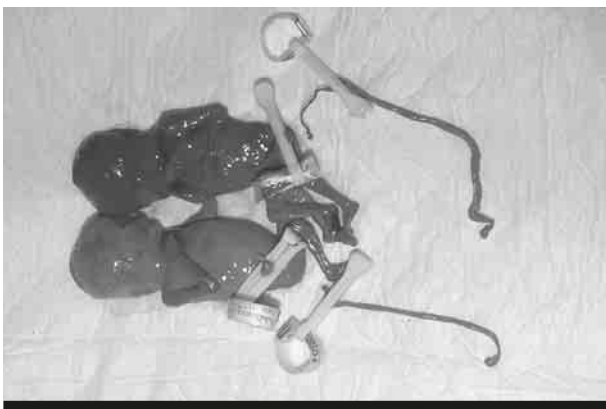
#### Case 4

A 27-year-old woman in her fourth pregnancy presented for nuchal translucency screening at 13 weeks gestation. A monoamniotic twin pregnancy was diagnosed. Crown rump length (CRL) was within the range for dates (CRL 75.5 mm with NT of 1.2 mm and CRL 78.2 mm with NT of 0.6 mm). The risk for trisomy 21 was 1 in 4200 for each twin. She was referred to the Twin Surveillance Clinic where a second scan at 14 weeks demonstrated intrauterine fetal death (IUID) of both twins. The delivery was induced with Mifepristone followed by Misoprostol. Two female fetuses were delivered. Post-mortem of the foetuses showed one to be pale in colour while the other was plethoric (Figure 3). The heart of the plethoric twin was around twice the size of that of the co-twin. There were no developmental malformations. The morphological examination of the placenta



**Figure 2**

Photograph showing the cord of stillborn twin tightly knotted around that of live twin.



**Figure 3**

14 weeks twin fetuses with one twin pale in colour and the other was plethoric.

confirmed the diagnosis of monoamniotic twins with evidence of arterio-venous anastomoses suggesting twin-twin transfusion syndrome (TTTS).

#### Case 5

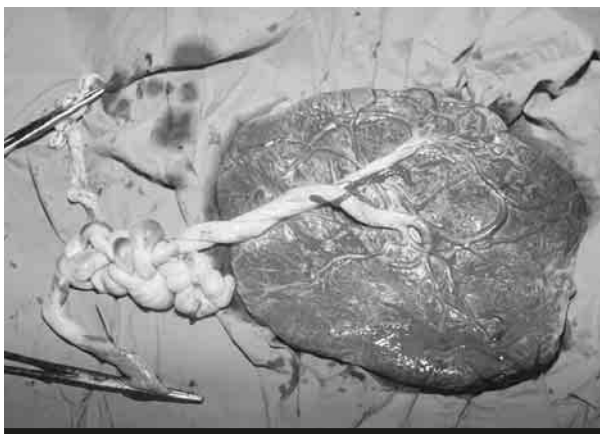
A 33-year-old woman in her first ongoing pregnancy presented for nuchal translucency screening and was found to have a monoamniotic twin pregnancy. The umbilical cords were first seen to cross at 19 weeks. The cord mass was observed to become gradually more complex as the pregnancy progressed. Elective delivery by cesarean section at 32 weeks was planned. Fetal surveillance was continued with weekly Doppler and liquor volume and fortnightly growth measurements after 24 weeks. Earlier delivery than 32 weeks was considered. After consultation between fetal medicine consultant, neonatologist and the parents, the twins were delivered electively by cesarean section at 30 weeks following maternal steroid administration 2 weeks earlier than originally planned. The birthweights were 1290g and 1220g. Several-fold cord entanglement between the two umbilical cords was confirmed at delivery (Figure 4). Both babies were discharged well from SCBU.

#### Case 6

A 28-year-old in her first pregnancy was found to have a monoamniotic twin pregnancy during a scan for nuchal translucency screening at 12 weeks. At 15 weeks, a second scan showed that both fetuses were normal size for gestation and there was no evidence of cord entanglement. However, the next scan at 19 weeks demonstrated IUID of both twins. The delivery was induced with Mifepristone followed by Misoprostol. Cord entanglement close to the placental insertions was noted at delivery.

#### Case 7

A 28-year-old woman in her first pregnancy presented for nuchal translucency screening at 13 weeks gestation and was diagnosed to have a monoamniotic twin pregnancy. A fetal cardiac scan at 20 weeks confirmed a diagnosis of congenital heart block of twin A in a structurally normal heart. There was no structural abnormality of twin B. All investigations, including anti Ro antibodies in maternal serum, were negative. Cord entanglement was detected at



**Figure 4**

Placenta and cord showing several folds of cord entanglement.

18 weeks. Serial 2-weekly scans ensued. With consensus from fetal medicine consultant, neonatologist and the parents, an elective cesarean section was performed at 32 weeks. Marked cord entanglement was confirmed at delivery. The baby girl with congenital heart block (Twin A) weighed 1835g and the normal twin (Twin B) weighed 2002g. Twin B required phototherapy for one day on day 5 and was discharged on day 9. Twin A required artificial ventilation at 3 hours of age and Isoprenalin was initiated due to profound bradycardia. Fulminant necrotising enterocolitis led to a neonatal death at 7 days of age.

## Discussion

Monoamniotic twins result from separation of the embryonic cell mass between the 7th and 13th day after fertilisation. This condition has been known since the 17th century (Quigley, 1935). Improvements in ultrasonographic resolution have led to an increasing number of reports of monoamniotic twins. A literature search by Arabin et al. (1999) revealed a report of 230 sets of monoamniotic twins between the periods of 1968 to June 1998. Ultrasound has also allowed antenatal prediction of cord entanglement. This was detected after 18 weeks of gestation using colour Doppler in 15 twin sets in this series. Cord entanglement was correctly predicted in four out of five cases in our series.

The suggested criteria for antenatal diagnosis of monoamniotic twins are absence of dividing membrane, a single placental mass, twins of same sex and enough amniotic fluid to allow free movements of both fetuses (Rodis et al., 1987). Cord intertwining, which can only occur in twins that share the same amniotic sac, is 100% specific for the diagnosis (Townsend & Filly, 1988). Bromley and Benacerraf (1995) concluded from their studies that presence of only one yolk sac in the first trimester was also characteristic of monoamniotic twin pregnancy.

Perinatal mortality in monoamniotic twins is reported to range from 30–70% (Quigley, 1935; Timmons & DeAlvarez, 1963), although more recent series suggest a lower perinatal mortality (Rodis et al., 1997). The most significant contributor to the high perinatal morbidity and mortality rate is umbilical cord accident. Constriction due to entanglement or true knotting in one or both of the cords leads to vascular occlusion and asphyxia of one or both twins. The true incidence of cord entanglement per se is difficult to assess. In one of the surveys (Salerno, 1959) the incidence was reported to be as high as 71.4%. The authors thought this might be falsely high as twisted cords might alert the obstetrician to monoamniotic twinning. We found similar incidence (5 of 7 cases) of cord entanglement in our small series.

In monoamniotic twinning, both fetuses can move around the intrauterine environment. Given the absence of a membranous barrier and the constant fetal mobility that occurs, particularly in the first trimester, we think that cord entanglement should be anticipated as an integral part of the natural history of these twins. Therefore, although important to document, the primary management issue is not whether entanglement has occurred. We believe the core focus should be on anticipating and avoiding the consequences of sudden

occlusion, which may complicate entangled umbilical cords, whether successfully diagnosed or not. Abnormally high systolic/diastolic ratio and presence of a notch in the umbilical artery velocity wave form will probably reflect circulatory compromise, secondary to narrowing of the umbilical vessels involved in the cord entanglement, which may be an indication of delivery (Abuhamad et al., 1995; Tongsong & Chanprapaph, 1999).

Some criteria were suggested for diagnosis of cord entanglement by the use of colour Doppler ultrasound. Apparent branching of the umbilical artery, with evidence of two different heart rates in the two segments of the branch will probably confirm the diagnosis (Rodis et al., 1987). As mentioned earlier, presence of a notch in the umbilical artery waveform and abnormally high systolic/diastolic ratio are late signs of cord entanglement.

Other factors contributing to the sombre prognosis include congenital anomalies, twin–twin transfusion syndrome, intrauterine growth retardation and preterm delivery. About half of our monoamniotic twin sets had fetal abnormality in one of the fetuses. This is similar to the findings of Baldwin (1994) and Sebire et al. (2000) who found that 40–50% of all non-conjoint monoamniotic twin sets were associated with structural defects of one or both fetuses.

There are conflicting opinions as to whether or not twin–twin transfusion syndrome (TTTS) occurs in monoamniotic twin pregnancies. Many authors (Lumme & Saarikoski, 1986; Wharton et al., 1968) believe that the common amniotic cavity may function as a buffer for difference in intrauterine pressure preventing twin-to-twin transfusion. It was also hypothesized that, in case of circulatory imbalance, both fetuses can swallow and thus restore their volume without the occurrence of hydramnios (Dubeq et al., 1996). Bajoria (1998) found that monochorionic monoamniotic placentas had significantly more vascular anastomoses (arterio-arterial, veno-venous, and arterio-venous) than did uncomplicated monochorionic diamniotic pregnancies. Abundance of these vascular anastomoses probably prevents circulatory imbalance and suggests a vascular basis for the rarity of TTTS in monoamniotic pregnancies. Other authors reported that the rate of TTTS in monoamniotic twins might be as high as 20–46% (Bromley & Benacerraf, 1995; Carr et al., 1990). Post mortem of Case 4 in the present series confirmed a diagnosis of TTTS with presence of A-V anastomoses in the placenta.

Antenatal management of monoamniotic twins remains controversial. There is no consensus regarding optimal fetal surveillance or timing of delivery. Some authors have suggested delivery after fetal lung maturity (Aisenbrey et al., 1995; Rodis et al., 1987). Others have commented that there is no advantage of prophylactic preterm delivery and have claimed that the risk of such delivery outweighs the risk of fetal death (Carr et al., 1990; Tessen & Zlatnic, 1991). Even when cord entanglement was diagnosed prenatally, the conclusion regarding surveillance and timing of delivery varied (Arabin et al., 1999). However most authors (Aisenbrey et al., 1995; Beasley et al., 1999) feel that delivery by cesarean section at 32 weeks is appropriate. Close serial ultrasound surveillance would appear to offer the potential for reasonable accuracy in predicting the absence

of cord entanglement. An unresolved issue is whether a non-interventional policy beyond 32 weeks can be safely adopted in these circumstances. At present, there are no data to inform clinical management and the decision is made on an individual case basis.

In managing our cases, the cornerstones of management were early diagnosis of chorionicity and amnionicity, serial ultrasound surveillance and early delivery by cesarean section. Against this background management of each woman was individualized after full consultation between the parents, fetal medicine consultants, consultant obstetricians and neonatologists. The parents were counselled regarding the risks and benefits of various strategies and management individualized accordingly. As a result, delivery was deferred to 34 weeks in case 2, and in case 5 brought forward to 30 weeks. In case 2, there was no evidence of cord entanglement at 32 weeks; furthermore it was felt that the outcome of surgical correction of the congenital malformations would be improved in a more mature baby.

Intensive fetal surveillance in the form of inpatient or outpatient CTG monitoring was not performed in any case except case 1, which was largely managed at another hospital. It is difficult to speculate as to whether more aggressive monitoring would have prevented the fetal death of one twin in case 3. Many authors (Beasley, 1999; Rodis et al., 1997) believe that antepartum fetal heart trace monitoring should be initiated at viability. However, the nature of cord accidents is that they may cause death to one or both twins suddenly and without warning signs. This cannot be detected on biophysical monitoring studies (Tongsong & Chanprapaph, 1999). The death in case 3 seems just such an event. Early delivery, once reasonable maturity has been achieved, is the most proactive way of dealing with this risk. The gestation at which this is achieved is for individual units to decide.

With our policy of individualized management supported by an overall protocol, we have achieved a live birth rate of 90% and an intact survival of 70% in pregnancies progressing beyond 20 weeks (see Table 1). We think that ultrasound is reliable in detecting monoamniotic twins and predicting the complication of cord entanglement. Timing of an elective delivery should be based on the risks of prematurity at various gestational ages compared with the unquantifiable risks of fetal death if the pregnancy were not interrupted. The decision of when to deliver must reflect the opinions of the parents, neonatologist, the fetal medicine consultant and the obstetrician.

## References

- Abuhamad, A. Z., Mari, G., Copel, J. A., Cantwell, C. J., & Evans, A. T. (1995). Umbilical artery flow velocity waveforms in monoamniotic twins with cord entanglement. *Obstetrics & Gynecology*, *86*, 674–677.
- Aisenbrey, G. A., Catanzarite, V. A., Hurley, T. J., Spiegel, J. H., Schrimmer, D. B., & Mendoza, A. (1995). Monoamniotic and pseudomonoamniotic twins: Sonographic diagnosis, detection of cord entanglements, and obstetric management. *Obstetrics & Gynecology*, *86*, 218–222.
- Allen, V. M., Windrim, R., Barrett, J., & Ohlsson, A. (2001). Management of monoamniotic twin pregnancies: A case series and review of the literature. *British Journal of Obstetrics & Gynaecology*, *108*, 931–936.
- Arabin, B. R., Laurini, R. N., & Van Eyck, J. (1999). Early prenatal diagnosis of cord entanglement in monoamniotic multiple pregnancies. *Ultrasound in Obstetrics & Gynecology*, *13*, 165–181.
- Baldwin, V. J. (1994). The pathology of monochorionic monozygosity. In V. J. Baldwin (Ed.), *Pathology of multiple pregnancy* (pp. 199–214). New York: Springer Verlag.
- Bajoria, R. (1998). Abundant vascular anastomoses in monoamniotic versus diamniotic monochorionic placentas. *American Journal of Obstetrics & Gynecology*, *179*, 788–793.
- Beasley, E., Megerian, G., Gerson, A., & Roberts, N. (1999). Monoamniotic twins: Case series and proposal for antenatal management. *Obstetrics & Gynecology*, *93*(1), 130–134.
- Bromley, B., & Benacerraf, B. (1995). Using the number of yolk sacs to determine amniocytosis in early first trimester monochorionic twins. *Journal of Ultrasound Medicine*, *14*, 415–419.
- Carr, S. R., Aronson, M. P., & Couston, D. R. (1990). Survival rates of monoamniotic twins do not decrease after 30 weeks gestation. *American Journal of Obstetrics & Gynecology*, *163*, 719–722.
- Dubeq, F., Dufour, P. H., Vinaitier, D., Thibault, D., Lefebvre, C., Tordjeman, N. (1996). Monoamniotic twin pregnancies. Review of the literature, and a case report with vaginal delivery. *European Journal of Obstetrics, Gynecology & Reproductive Biology*, *66*, 183–186.
- Lumme, R. H., & Saarikoski, S. V. (1986). Monoamniotic twin pregnancy. *Acta Geneticae Medicae et Gemellologiae*, *35*, 99–105.
- Quigley, J. K. (1935). Monoamniotic twin pregnancy. *American Journal of Obstetrics & Gynecology*, *29*, 832–834.
- Rodis, J. F., Vintzelos, A. M., Campbell, W. A., Dearson, J. L., Fumia, F., & Nochinson, D. J. (1987). Antenatal diagnosis and management of monoamniotic twin. *American Journal of Obstetrics & Gynecology*, *157*, 1255–1257.
- Rodis, J. F., McIlveen, P. F., Egan, J. F. X., Borgida, A. F., Turner, A. F. & Campbell, W. A. (1997). Monoamniotic twins: Improved perinatal survival with accurate prenatal diagnosis and antenatal fetal surveillance. *American Journal of Obstetrics & Gynecology*, *177*, 1046–1049.
- Salerno, L. J. (1959). Monoamniotic twinning: A survey of the American literature since 1935 with a report of four new cases. *Obstetrics & Gynecology*, *14*, 205–213.
- Sebire, N. J., Souka, A., Skentou, H., Geerts, L., & Nicolaides, K. H. (2000). First trimester diagnosis of monoamniotic twin pregnancies. *Ultrasound in Obstetrics & Gynecology*, *16*, 223–225.
- Tessen, J. A., & Zlatnic, F. I. (1991). Monoamniotic twins: A retrospective controlled study. *Obstetrics & Gynecology*, *77*, 832–834.
- Timmons, J. D., & DeAlvarez, R. R. (1963). Monoamniotic twin pregnancy. *American Journal of Obstetrics & Gynecology*, *86*, 875–879.
- Townsend, R. R., & Filly, R. A. (1988). Sonography of non-conjoined monoamniotic twin pregnancy. *Journal of Ultrasound Medicine*, *7*, 665–670.
- Tongsong, T., & Chanprapaph, P. (1999). Evaluation of umbilical cord entanglement in monoamniotic twins. *Ultrasound in Obstetrics & Gynecology*, *14*, 75–78.
- Wharton, B., Edwards, J. H., & Cameron, A. H. (1968). Monoamniotic twins. *Journal of Obstetrics & Gynecology of British Commonwealth*, *75*, 158–163.