

LETTERS TO THE EDITOR**TO THE EDITOR****Rapidly Progressive Dementia in a Chinese Patient due to C9ORF72 Mutation**

Frontotemporal dementia (FTD) represents a dementia syndrome with a high frequency of familial occurrence. A significant proportion of patients with FTD develop symptoms of amyotrophic lateral sclerosis (ALS) during the course of their disease and vice versa. Moreover, some families show autosomal dominant inheritance of both FTD and ALS. We have recently identified an expanded GGGGCC hexanucleotide repeat in a non-coding region of the *C9ORF72* gene on chromosome 9p to be the most common cause of familial FTD and ALS.¹ To date, this genetic abnormality has only been described in patients of European descent.² Here we report a Chinese patient with FTD due to the *C9ORF72* mutation with a strong family history of the FTD/ALS syndrome.

CASE REPORT

A 45-year-old right handed woman presented to a tertiary dementia clinic with behavioural changes. The patient and her family are of pure ethnic Chinese Han ancestry and were born in Singapore. She initially developed symptoms of anxiety three years earlier. A year later, she had behavioural change with excessive spending that was out of character, unreasonable suspiciousness, and fear of being left alone. Her family also noted decline in table manners and craving for sweets. Eight months prior to her first assessment, she developed language difficulties with paraphasic errors and word finding difficulties. Concurrently, she began having difficulty with cooking and meal preparation. By the time of her first specialist assessment, she needed assistance with all her activities of daily living.

Her mother had been diagnosed with a dementing disorder in her late 60s and passed away several years later. Four of the patient's nine siblings also developed features of neurodegenerative disease and died at a young age: an older

sister died in her 50s after developing significant behavioral changes, another sister died at the age of 55 with a diagnosis of ALS, and two of her older brothers also died of ALS in their 40s.

Examination of the patient was difficult as she was restless and needed to be constantly comforted by her husband. She replied using monosyllables and could only follow simple instructions. Cranial nerves were unremarkable with no evidence of tongue fasciculation. She had full power of all limbs but there was bilateral cog-wheeling at the wrist and elbow. Deep tendon reflexes were 2+ and symmetrical and plantar responses were flexors. Her Mini Mental State Examination Score was 15/30, Montreal Cognitive Assessment score was 9/30 and the Frontal Assessment Battery score was 6/18. Cognitive examination demonstrated predominant deficits in executive function and expressive language, with relative preservation of her semantic knowledge on confrontational naming, consistent with a diagnosis of behavioural variant FTD as well as features of non-fluent aphasia.

Electromyogram did not demonstrate any evidence of motor neuron disease. Magnetic resonance imaging (MRI) brain demonstrated moderate to severe frontal temporal atrophy with left sided predominance. (Figure 1) Despite treatment with memantine and quetiapine, her condition deteriorates. She was near mute at her last clinical assessment. Repeat-primed PCR analysis of her DNA revealed an expanded GGGGCC hexanucleotide repeat in *C9ORF72*,¹ which also includes the rs3849942 risk allele A associated with FTD-ALS.³ (Figure 2; DNA from an unaffected sibling is also shown for comparison).

DISCUSSION

Our patient developed behavioural changes and rapid cognitive decline over a period of two years. Her clinical diagnosis is consistent with FTD, and she was found to have the expanded hexanucleotide repeat in *C9ORF72*. This mutation is now recognized as the most common genetic cause of both FTD and ALS, and the basis in most families in which both conditions are inherited in an autosomal dominant pattern. This finding,

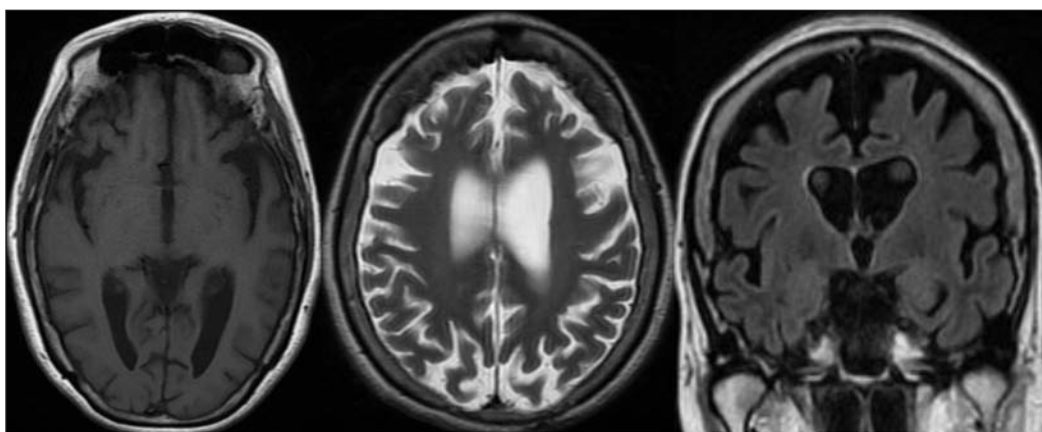


Figure 1: Axial T1, T2, and coronal FLAIR images of the patient's brain 18 months after the onset of symptoms.

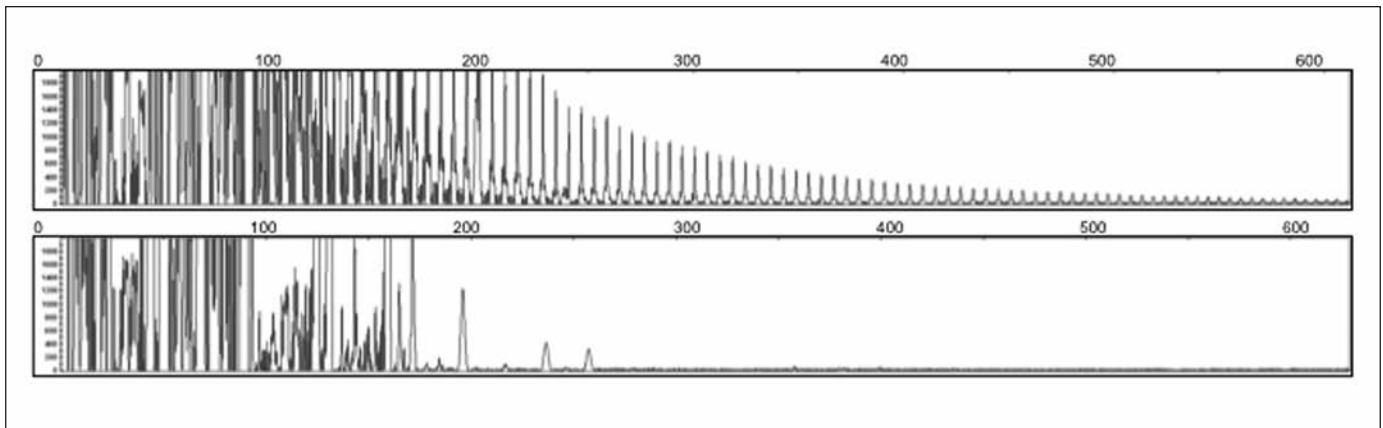


Figure 2: Upper panel - Repeat primed PCR of the patient demonstrating the PCR products of the GGGGCC hexanucleotide repeats on an ABI3730 DNA Analyzer and visualized by GENEMAPPER software. Lower panel - no hexanucleotide repeat was found in an unaffected sibling.

along with the recognition of TDP-43 as the pathological protein in most cases of both FTD and ALS, suggests that these two conditions represent a clinicopathological spectrum of disease with a shared pathogenetic mechanism. Until now, the *C9ORF72* mutation has only been reported in patients of European ancestry. The frequency of FTD in Asian populations has not been well-studied. One study examined dementia distribution in California suggested that FTD is as frequent in Asian and Pacific Islanders as in Caucasians.⁴ Whereas for ALS, a recent systematic review found that the incidence is lower in Asians than in Caucasians.⁵ The degree to which this difference in disease frequency can be explained by variations in genetic background is not known. A previous study of the haplotype on chromosome 9p, associated with ALS and FTD suggested that the mutation was likely derived from a single founder from Northern Europe.³ Our finding that the *C9ORF72* mutation exists in an ethnic Chinese family with no known Western lineage would argue otherwise, and highlights the need to study this mutation in more diverse ethnic populations.

ACKNOWLEDGEMENT

The study is in part supported by the Canadian Institutes of Health Research (CIHR) Operating Grants #179009 and #74580 (IRM), the Pacific Alzheimer's Research Foundation (PARF) Center Grant #C06-01, and NIH grants R01 NS065782 and R01 AG06251 (to R.R). G-YRH is supported by a Clinical Genetics Investigatorship award from the CIHR.

Nagaendran Kandiah
National Neuroscience Institute, Singapore

Pheth Sengdy, Ian R. A. Mackenzie, Ging-Yuek R. Hsiung
University of British Columbia, Vancouver, BC, Canada
Email: hsiang@mail.ubc.ca

Mariely DeJesus-Hernandez, Rosa Rademakers
Mayo Clinic Jacksonville, Jacksonville, Florida, USA

REFERENCES

1. DeJesus-Hernandez M, Mackenzie IR, Boeve BF, et al. Expanded GGGGCC hexanucleotide repeat in noncoding region of *C9ORF72* causes chromosome 9p-linked FTD and ALS. *Neuron*. 2011;72(2):245-56.
2. Hodges J. Familial frontotemporal dementia and amyotrophic lateral sclerosis associated with the *C9ORF72* hexanucleotide repeat. *Brain*. 2012;135:652-5.
3. Mok K, Traynor BJ, Schymick J, et al. The chromosome 9 ALS and FTD locus is probably derived from a single founder. *Neurobiol Aging*. 2012;33(1):209 e3-8.
4. Hou CE, Yaffe K, Perez-Stable EJ, Miller BL. Frequency of dementia etiologies in four ethnic groups. *Dement Geriatr Cogn Disord*. 2006; 22(1): 42-7.
5. Cronin S, Hardiman O, Traynor BJ. Ethnic variation in the incidence of ALS: a systematic review. *Neurology*. 2007; 68(13): 1002-7.