

# Interhemispheric Subdural Hematoma

Neville A. Russell, Raquel del Carpio-O'Donovan, K.B. Mallya,  
Brien G. Benoit and Gary Belanger

**ABSTRACT:** Although relatively uncommon, interhemispheric subdural hematoma (ISDH) occurs more frequently than was suspected before the advent of computerized tomographic (CT) scanning. When its mass is sufficiently large to compress the medial cerebral hemisphere, specific focal neurological abnormalities may occur. These include weakness of the contralateral leg, or contralateral hemiparesis with the leg being weaker than the arm. On the unenhanced CT scan ISDH is seen as a crescent shaped, midline hyperdensity. Treatment is dictated by the clinical course. Evacuation of the hematoma by parasagittal craniotomy is recommended if the symptoms are pronounced.

**RÉSUMÉ:** Hématome sous-dural interhémisphérique Même si cette entité est relativement rare, l'hématome sous-dural interhémisphérique (HSDI) survient plus fréquemment qu'on ne le soupçonnait avant l'avènement de la tomographie axiale assistée par ordinateur. Quand la masse de l'hématome est suffisamment importante pour comprimer la face interne de l'hémisphère, des anomalies neurologiques focales spécifiques apparaissent. Parmi celles-ci, notons la faiblesse de la jambe contralatérale ou l'hémi-parésie contralatérale, la jambe étant plus faible que le bras. A la tomographie axiale sans perfusion de produit de contraste, l'HSDI apparaît comme une zone d'hyperdensité médiane en forme de croissant. Le traitement est déterminé par l'évolution clinique. Si la symptomatologie est importante, il est recommandé de procéder à l'évacuation de l'hématome par crâniotomie parasagittale.

*Can. J. Neurol. Sci. 1987; 14:172-174*

Interhemispheric subdural hematoma (ISDH) was first described at autopsy by Airing and Evans<sup>1</sup> in 1940 and first recognized during life by Jacobsen<sup>2</sup> in 1955. Prior to the advent of computerized tomographic (CT) scanning this lesion was very difficult to detect, a fact which accounts for the paucity of cases reported before 1974,<sup>1-6</sup> and for the persistent belief that it is very rare<sup>8,11</sup>. In this paper we report two additional cases of ISDH and discuss the unique features of this lesion.

## CASE REPORTS

### *Patient 1*

An 80-year-old man fractured the neck of his right femur and struck his head in a fall. He did not lose consciousness. His past history included chronic obstructive lung disease and a myocardial infarction. Because of the latter he had been receiving oral anti-coagulant therapy. Upon admission to hospital he was alert and without neurologic deficit. Three days later he was noted to be disoriented and at examination was found to have a right hemiplegia with right facial weakness. Shortly afterwards he developed focal right sided seizures, which involved his leg more than his arm. Prothrombin time was 28 seconds (normal range 10-12), and partial thromboplastin time was 48 seconds (normal range 25-30). A nonenhanced CT scan showed a large left ISDH (Figure 1). Craniotomy was performed via a left sided parasagittal bone flap. The brain was swollen but no other abnormalities noted upon its surface. One small bridging vein was coagulated and divided. The medial left cerebral hemisphere was retracted with some difficulty because of

brain swelling. A large hematoma was encountered in the subdural space deep between the hemispheres, extending onto the tentorium. Approximately 70 cc's of semi-liquid blood were removed with irrigation and suction. He awakened immediately after surgery, but remained confused and hemiplegic, with the leg being weaker than the arm. He continued in this state for 12 days, after which pneumonia developed. He died of this on the 14th postoperative day. Autopsy revealed no residual clot in the interhemispheric subdural space. No source of hemorrhage was detected.

### *Patient 2*

An 81-year-old woman fell and struck her head. She did not lose consciousness. She had longstanding diabetes mellitus and had been having oral anti-coagulant therapy for several years, because of a cerebrovascular thrombosis. Twenty-four hours after injury she complained of headache and seemed drowsy. Over several subsequent hours she became unconscious. At examination she was comatose, with spontaneous movements of her right limbs: the left limbs moved only to deep pain, with the arm moving better than the leg. Prothrombin time was 14 seconds (normal range 10-12). Partial thromboplastin time was 54 seconds (normal range 25-30). A nonenhanced CT scan, showed a large right ISDH which was virtually identical to that in Case 1 (Figure 1). The blood had also tracked posteriorly to outline the tentorium. Craniotomy via a large parasagittal bone flap gave easy access to a subdural hematoma situated deep between the cerebral hemispheres and extending onto the tentorium. Approximately 55 cc's of semi liquid blood were removed using irrigation and suction. The bridging veins were not disturbed. In the immediate postoperative period she remained stuporous with focal seizures involving the left leg. These were controlled by anti-convulsant therapy and she gradually recovered to be

From the Division of Neurosurgery and the Department of Diagnostic Radiology, Ottawa Civic Hospital and the University of Ottawa, Ottawa, Ontario  
Received September 24, 1986. Accepted December 16, 1986

Reprint requests to: Dr. N.A. Russell, Suite 606, 1081 Carling Avenue, Ottawa, Ontario K1Y 4G2

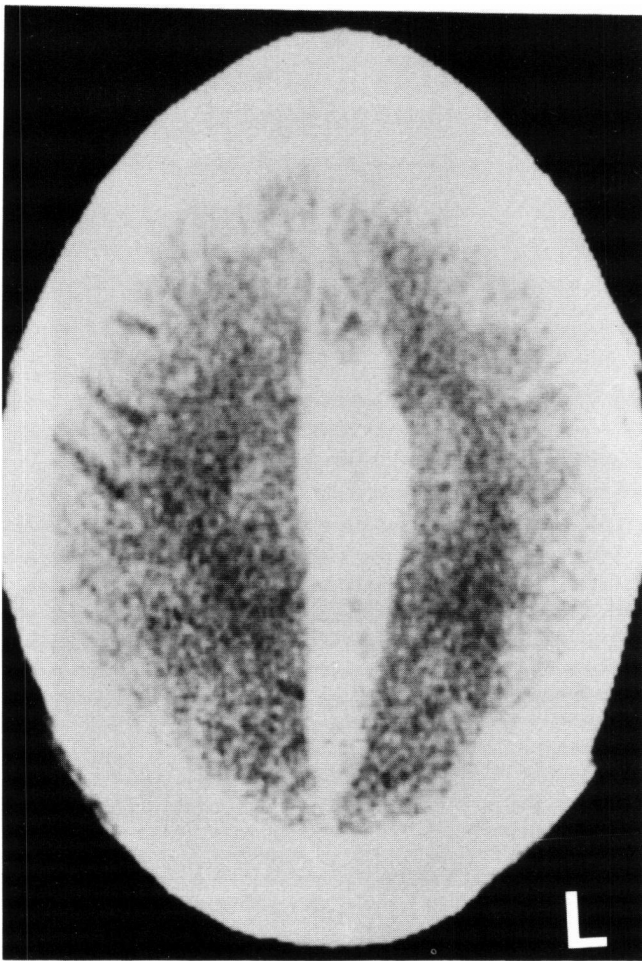


Figure 1 — ISDH in Patient 1. The midline hyperdensity has a flat medial margin -falx- and a convex lateral border where the lesion bulges into the ipsilateral hemisphere.

able to sit in a chair and feed herself. Recovery continued until the sixth postoperative week, when she was discovered unconscious in her bed. Her blood glucose level was 20 mg%. Resuscitation was unsuccessful. Permission for autopsy was refused.

#### DISCUSSION

A total of 99 cases of ISDH have been reported in the literature. All but ten of these have appeared since 1974,<sup>8-28</sup> coinciding with the widespread use of CT scanning. Two large series deal primarily with the CT features of the hematoma.<sup>25,28</sup> All other papers except one that describes three cases,<sup>23</sup> and three, each describing two cases,<sup>11,19,20</sup> consist of single case reports.

ISDH is usually caused by blunt direct head injury,<sup>10,12,20</sup> or by indirect head injury in young children abused by violent shaking.<sup>24,25</sup> It has also been described following penetrating wounds of the falx,<sup>28</sup> aneurysm rupture,<sup>5,13,18</sup> and in association with anti-coagulant therapy,<sup>7,11,16,23</sup> blood dyscrasias<sup>14,17,21</sup> and shunted hydrocephalus.<sup>10</sup>

The hemorrhage occurs when torsion forces rupture the large fixed bridging veins between the parieto-occipital cortex and the superior sagittal sinus.<sup>9,11,13,24-28</sup> Thus it is largest in the posterior superior part of the interhemispheric fissure, above and behind the splenium of the corpus callosum.<sup>26-28</sup> Firm arachnoidal attachments separate the two sides of the interhemispheric fissure from each other and from the convexity

subdural space.<sup>26-28</sup> Therefore, ISDH is usually unilateral. Associated convexity subdural hematomas were present in a number of the cases reported.<sup>1-3,6,8,11,17,26,28</sup> Some authors consider these to represent an extension of the hematoma from the interhemispheric fissure,<sup>8,10,19</sup> while others believe they originate from separate bleeding sources.<sup>26-28</sup>

Major trauma was implicated in only a few of the cases occurring after blunt head injury.<sup>1,6,11,12,17,24</sup> These patients were unconscious from the time of injury or shortly thereafter. More frequently the associated injury was minor, with or without a brief period of unconsciousness. Both of our patients had minor head injuries, but they were also receiving anti-coagulant therapy. Usually the onset of symptoms and signs is delayed, with the delay varying from days,<sup>2,7,8,10,19</sup> to weeks,<sup>4,16,21,22</sup> to months.<sup>10</sup>

Focal neurological abnormalities have been reported in association with ISDH, and were observed in both of our patients. These include weakness of the contralateral leg<sup>2,5,7,20</sup> or contralateral hemiparesis with the leg being weaker than the arm,<sup>6,7,8,12,14,16,18,19,23</sup> or seizures involving the contralateral leg.<sup>1,14,19,23</sup> Paraparesis has also been described.<sup>10,23</sup> These signs indicate a medial cerebral hemisphere lesion, have also been described in patients with interhemispheric subdural empyema<sup>29,30</sup> and with occlusion of the anterior cerebral artery.<sup>19</sup> This clinical picture has been referred to as the falx syndrome.<sup>19,30</sup>

Prior to CT scanning, carotid angiography was the investigation of choice for ISDH.<sup>2,3,5,6,7,19</sup> In the anterior-posterior view it shows a midline avascular space, which is produced by displacement of the callosomarginal arteries without a similar displacement of the pericallosals. Angiography has been replaced by CT scanning, and need only be considered if an aneurysm is suspected.

CT scanning gives an immediate and precise diagnosis, defining the exact location, extent and pattern of the ISDH.<sup>8-10,12,16,19,23,24-28</sup> On the nonenhanced CT scan, its hallmark is a midline, parafalcial, crescent shaped hyperdense mass. Its flat medial border is formed by the falx and its convex lateral border by the hematoma mass bulging into the ipsilateral hemisphere. It is differentiated from subarachnoid hemorrhage<sup>31</sup> and intracerebral hematoma<sup>16</sup> by its size and shape, and from interhemispheric empyema<sup>21</sup> by its density.

Zimmerman et al<sup>26,28</sup> suggest that most of these hematomas resolve spontaneously and that surgical treatment is rarely necessary. We believe this to be true only if the hematoma is very small. If it is large enough to cause mass effect, it should be treated promptly. If the patient's condition is stable, continuous monitoring of the intracranial pressure and its control by conservative measures may be adequate.<sup>8</sup> However, acute or progressive neurological deterioration requires surgical intervention. Craniotomy is preferable to simple burr holes for adequate exploration of the interhemispheric space.<sup>9,12,28</sup> Since the hematoma does not present upon the surface, the hemisphere must be retracted in order to achieve a satisfactory removal. The bone flap must cross the midline and the exposure must be large enough to allow retraction of the hemisphere, without injuring important draining veins.

#### ACKNOWLEDGEMENTS

The authors acknowledge the expert secretarial assistance of Miss Donna Headrick.

## REFERENCES

1. Aring CD, Evans JP. Aberrant location of subdural hematoma. *Arch Neurol Psychiat (Chicago)* 1940; 44: 1296-1306.
2. Jacobsen HH. An interhemispherically situated hematoma: Case report. *Acta Radiol (Stockh.)* 1955; 43: 235-36.
3. Campbell JA, Campbell RL. Angiographic diagnosis of head and neck lesions. *JAMA* 1962; 175: 761-68.
4. Clein LJ, Bolton CF. Interhemispheric subdural hematoma: A case report. *J Neurol Neurosurg Psychiat* 1969; 32: 389-92.
5. Fein JM, Rovit RL. Interhemispheric subdural hematoma secondary to hemorrhage from a callosal-marginal artery aneurysm. *Neuroradiology* 1970; 1: 83-86.
6. Gannon WE. Interhemispheric subdural hematoma. Case Report. *J Neurosurg* 1961; 18: 829-30.
7. Wooschlaeger PB, Wooschlaeger G. The interhemispheric subdural or falx hematoma. *AJR* 1964; 92: 1252-54.
8. Fruin AH, Juhl GL, Taylor C. Interhemispheric subdural hematoma. *J Neurosurg* 1980; 60: 1300-1302.
9. Glista GC, Reichman OH, Brumlik J, et al. Interhemispheric subdural hematoma. *Surg Neurol* 1978; 1: 119-22.
10. Kasdon DL, Macgruber MR, Steven EA, et al. Bilateral interhemispheric subdural hematoma. *Neurosurgery* 1979; 5: 57-9.
11. Pozzati E, Gaist G, Vinci, et al. Traumatic interhemispheric subdural hematoma. *J Trauma* 1982; 22: 241-43.
12. Fearnside MR, Hall K, Sengupta RP. Interhemispheric subdural hematoma following head injury. *Aust N J Surg* 1979; 49: 679-80.
13. Friedman MB, Brant-Zawadzki M. Interhemispheric subdural hematoma from ruptured aneurysm. *Computerized Radiol* 1983; 7: 129-134.
14. Gardeur D, Metzger J. Tomodensitometre intra-cranienne. Livre IV. Pathologie traumatique cranio-cerebrale. Paris Ellipses, 1982: 43.
15. Handel SF, Perpetuo FUL, Handel CH. Subdural hematomas due to ruptured cerebral aneurysms: Angiographic diagnosis and potential pitfalls for CT. *Am J Roentgenol* 1978; 130: 507-509.
16. Ho SU, Spehlmann R, Ho HT. CT scan in interhemispheric subdural hematoma: Clinical and pathological correlation. *Neurology* 1977; 27: 1097-98.
17. Izawa M, Takahashi K, Sentoh S. A case of interhemispheric subdural hematoma associated with thrombocytopenia. *Neurolog Surg (Tokyo)* 1982; 10: 557-60.
18. New PFJ, Scott WR, Schnur JA, et al. Computerized axial tomography with the EMI scanner. *Radiology* 1974; 110: 109-23.
19. Ogsbury JS, Schneck SA, Lehman RAW. Aspects of interhemispheric chronic subdural hematoma including the falx syndrome. *J Neurol Neurosurg Psychiat* 1978; 41: 72-5.
20. Satoh T, Yamamoto Y, Asari S, Sadamoto K. Traumatic interhemispheric subdural hematoma. Report of a case and analysis of 7 cases. *Neurolog Surg (Tokyo)* 1982; 10: 667-72.
21. Shigimori M, Tomoyuki K, Shirahama M, et al. Acute interhemispheric subdural hematoma: Report of 2 cases. *Neurolog Surg (Tokyo)* 1982; 10: 647-52.
22. Sibayan RI, Gurdjian ES, Thomas LM. Interhemispheric chronic subdural hematoma. *Neurology* 1970; 20: 1215-54.
23. Woimant F, Thurel C, Roux FX, et al. Hematomes susduraux aigus interhemispheriques. *Rev Neurol (Paris)* 1983; 139: 299-303.
24. Zimmerman RA, Bilaniuk LT, Bruce D, et al. Interhemispheric acute subdural hematoma: A computed tomographic manifestation of child abuse by shaking. *Neuroradiology* 1978; 16: 39-40.
25. Zimmerman RA, Bilaniuk LT, Bruce D, et al. Computed tomography of craniocerebral injury in the abused child. *Radiology* 1979; 130: 687-690.
26. Zimmerman RD, Danziger A. Extracerebral trauma. *Radiol Clin of NA* 1982; 20: 105-122.
27. Zimmerman RD, Yurberg E, Russell EJ, et al. Falx and interhemispheric fissure on axial CT: I Normal Anatomy. *AJNR* 1982; 3: 103-115.
28. Zimmerman RD, Russell EJ, Yurberg E, et al. Falx and interhemispheric fissure on axial CT: II Recognition and differentiation of interhemispheric subarachnoid and subdural hemorrhage. *Neuroradiology* 1982; 3: 635-642.
29. Kristainsen K, Zimmer J. Interhemispheric subdural abscess. *Brit J Rad* 1958; 31: 278-79.
30. List CF. Diagnosis and treatment of acute subdural empyema. *Neurology* 1955; 5: 665-70.
31. Osborn AG, Anderson RE, Wing SD. The false falx sign. *Radiology* 1980; 134: 421-425.