

Research Article

Cite this article: Hall LM, Munasinghe VS, Vella NGF, Ellis JT, Stark D (2024). Observations on the transmission of *Dientamoeba fragilis* and the cyst life cycle stage. *Parasitology* **151**, 337–345. <https://doi.org/10.1017/S0031182024000076>

Received: 20 July 2023

Revised: 20 November 2023

Accepted: 11 January 2024

First published online: 22 January 2024

Keywords:



cyst; *Dientamoeba fragilis*; electron microscopy; transmission

Corresponding author:

Luke M. Hall;

Email: Luke.Hall@uts.edu.au

Observations on the transmission of *Dientamoeba fragilis* and the cyst life cycle stage

Luke M. Hall^{1,2} , Varuni S. Munasinghe¹, Nicole G. F. Vella³, John T. Ellis¹  and Damien Stark²

¹School of Life Sciences, University of Technology Sydney, Broadway, NSW 2007, Australia; ²Division of Microbiology, Sydpath, St Vincent's Hospital, Darlinghurst, NSW 2010, Australia and ³Macquarie University Microscopy Unit, Faculty of Science and Engineering, Macquarie University, North Ryde, NSW 2109, Australia

Abstract

Little is known about the life cycle and mode of transmission of *Dientamoeba fragilis*. Recently it was suggested that fecal–oral transmission of cysts may play a role in the transmission of *D. fragilis*. In order to establish an infection, *D. fragilis* is required to remain viable when exposed to the pH of the stomach. In this study, we investigated the ability of cultured trophozoites to withstand the extremes of pH. We provide evidence that trophozoites of *D. fragilis* are vulnerable to highly acidic conditions. We also investigated further the ultrastructure of *D. fragilis* cysts obtained from mice and rats by transmission electron microscopy. These studies of cysts showed a clear cyst wall surrounding an encysted parasite. The cyst wall was double layered with an outer fibrillar layer and an inner layer enclosing the parasite. Hydrogenosomes, endoplasmic reticulum and nuclei were present in the cysts. Pelta-axostyle structures, costa and axonemes were identifiable and internal flagellar axonemes were present. This study therefore provides additional novel details and knowledge of the ultrastructure of the cyst stage of *D. fragilis*.

Introduction

Dientamoeba fragilis is a pathogenic protozoan parasite which causes diarrhoea and gastrointestinal disease in humans (Barratt *et al.*, 2011; Stark *et al.*, 2016). It belongs to the family Trichomonadidae and close relatives are *Histomonas* and *Trichomonas* species. This organism was discovered a century ago but its life cycle is yet to be elucidated. Until recently, trophozoites were the recognized *D. fragilis* life cycle stage, and it degenerates quickly once passed from the host in stool. Several theories suggest how *D. fragilis* could survive outside the host for a short period of time to allow transmission. One possibility is that *Dientamoeba* is transmitted *via* a helminth vector, or through a resistant pseudocyst or a cyst stage (Barratt *et al.*, 2011; Stark *et al.*, 2006).

Jepps and Dobell (1918) described the fragile nature of the trophozoite stage of *D. fragilis* but were unable to find a cyst stage in human stool samples. It was suggested that *D. fragilis* may form cysts in an unidentified animal species (Jepps and Dobell, 1918) indicating the potential for zoonotic transmission. *Dientamoeba fragilis* has been reported in several animal species including non-human primates, budgerigars, rats, cattle, sheep and pigs (Chan *et al.*, 2016; Galán-Puchades *et al.*, 2021; Stark *et al.*, 2008; Yetismis *et al.*, 2022; Yildiz and Erdem Aynur, 2022). Knowles and Das Gupta (1936) detected *Dientamoeba* in stool of a captive macaques using iron haematoxylin staining methods (Knowles and Gupta, 1936). Another study reported *Dientamoeba* infections in wild monkeys in the Philippines (Hegner and Chu, 1930). Two studies showed the presence of *Dientamoeba* in the stools of western lowland gorilla by microscopy with further confirmation by polymerase chain reaction (PCR) (Lankester *et al.*, 2010; Stark *et al.*, 2008).

Evidence for a cyst stage has not only been elusive, but also controversial. However, several authors described long ago what appears to be a cyst-like or a pre-cyst stage of *D. fragilis* (Knoll and Howell, 1946; Piekarski, 1948; Silard *et al.*, 1979). A pseudocyst stage was described as a small individual with a finely granular cytoplasm with distinct endosomes (Wenrich, 1936). A more recent report dismissed these studies and suggested that these forms were degenerating trophozoites (Johnson *et al.*, 2004). Therefore, the general perception until recently was that a cyst stage was absent in *D. fragilis* (Barratt *et al.*, 2011). However, recent studies found cyst forms of the parasite in clinical samples, albeit at very low levels (Abd, 2021; Garcia, 2016; Stark *et al.*, 2014a).

There have been several attempts to induce experimental infections in a range of animals which have been largely unsuccessful (Dobell, 1940; Kean and Malloch, 1966; Knoll and Howell, 1946; Lankester *et al.*, 2010; Wenrich, 1944). Wenrich (1944) tried to infect laboratory rats with cultured *D. fragilis* trophozoites orally and *via* rectal inoculation; however, these attempts were unsuccessful (Wenrich, 1944). Latter attempts to infect laboratory rats mention that there was damage to the underlying cells where *D. fragilis* attached to the caecal mucosa in

© The Author(s), 2024. Published by Cambridge University Press. This is an Open Access article, distributed under the terms of the Creative Commons Attribution-NonCommercial licence (<http://creativecommons.org/licenses/by-nc/4.0/>), which permits non-commercial re-use, distribution, and reproduction in any medium, provided the original article is properly cited. The written permission of Cambridge University Press must be obtained prior to any commercial use.

which oedema was evident, however no actual ulceration was detected (Kean and Malloch, 1966). The failure to develop a reproducible animal model of infection with *D. fragilis* has hindered research into many aspects of this parasite.

Recently, it was reported that Balb/C mice can be infected orally with culture derived from trophozoites (Munasinghe *et al.*, 2013). Cysts were detectable in stool samples by light microscopy and cross-transmission studies with Sprague Dawley rats showed them to be also susceptible to infection by *D. fragilis* (Munasinghe *et al.*, 2013). *Dientamoeba fragilis* got its name because of the fragile nature of the trophozoite when outside their host. This fragile nature leads us to hypothesize that human-to-human transmission of the trophozoite would be impractical. Thus, we hypothesize that cysts play some role in *D. fragilis* transmission. As such, excystation and encystation must be features of the *D. fragilis* life cycle. This process must involve oral ingestion and transversal of the parasites across the hostile environment of the mammalian stomach and other parts of the gastrointestinal track since trophozoites are commonly found in stool samples. In this study, we investigated the ability of cultured trophozoites to withstand the extremes of pH and we provide evidence that trophozoites of *D. fragilis* are susceptible to highly acidic conditions. We also investigated further the ultra-structure of *D. fragilis* cysts obtained from mice and rats by transmission electron microscopy (TEM).

Materials and methods

Ethics statement

All animal-based research was approved by the Animal Care and Ethics Committee (ACEC) at the University of Technology, Sydney. Use of clinical samples derived from humans was approved by the Human Research Ethics Committee at St Vincent's Hospital Sydney.

Parasite culture

Strain F of *D. fragilis* was isolated and cultured from a symptomatic patient at St. Vincent's Hospital Sydney. The trophozoites were grown microaerophilically at 37 °C in M^cCartney Bottles containing Loeffler's slopes overlaid with phosphate-buffered saline (PBS) as described (Barratt *et al.*, 2010). The presence of *D. fragilis* was initially determined in the symptomatic patient and the parasite culture using the EasyScreenTM Enteric Protozoan Detection Kits (Genetic Signatures, Australia) according to the manufacturer's instructions (Stark *et al.*, 2014b). Identification of parasites in the culture was confirmed by Sanger Sequencing a region of the small subunit ribosomal DNA (SSU rDNA) at the Australian Genome Research Facility using the novel primers SSUF3 5'-CCG GGT AGT TCC TAC CTT AAA C-3' and SSUR3 5'-GGA CAT CAC GGA CCT GTT ATT-3' (Genbank: OR826038). Cycling conditions were denaturation at 95 °C, annealing at 60 °C and extension at 72 °C each for 1 min for a total of 40 cycles.

Resistance of trophozoites to pH conditions

Six solutions of PBS were adjusted using concentrated HCl to cover a pH range of 1–6. PBS (pH 7.0) was used as the negative control with and without a Loeffler's slope. *Dientamoeba fragilis* trophozoites from the log phase culture (48 h post inoculation of cultures) were centrifuged at 500 g for 10 min. The supernatant was removed and the cell pellet containing the trophozoites was resuspended in the pH-adjusted PBS (pH 1–7). The trophozoite (pH 1–7) suspensions were sampled at time intervals: 0, 2, 4

and 6 h and at each sampling time, the trophozoites resistance to treatment was determined using cell counts with a viability stain (1% trypan blue). These data were used to calculate a total cell count relative to time point 0 (T0), viability (percentage) and viable cell count relative to T0.

Animal experiments

Six-week-old specific pathogen-free Balb/C female mice and Sprague Dawley rats were obtained from the Animal Resource Centre (Perth, WA) and housed in filter top cages in separate rooms. The mice were given sterile rodent chow as standard diet and sterile water to drink *ad libitum*. The cage bedding was changed every day to avoid any possible cross-contamination. Prior to infection with *D. fragilis* trophozoites, the animals were surveyed for the presence of intestinal parasites. Two methods were used. Feces was tested daily for 7 days by light microscopy using a modified iron haematoxylin stain as previously described (Stark *et al.*, 2010) to identify any enteric parasites. PCR was also undertaken using *D. fragilis*-specific primers as previously described (Stark *et al.*, 2010). A tandem multiplex RT-PCR for the detection of *Cryptosporidium* spp., *D. fragilis*, *Entamoeba histolytica* and *Giardia intestinalis* (Stark *et al.*, 2011) was also used as a final screen to confirm these animals were free of *D. fragilis* (along with other protozoa) prior to experimental infection. All these methods showed that the animals were free of any protozoal parasites, including *D. fragilis*, prior to study.

Mice and rats were infected with approximately 100 µL PBS (pH 7.0) containing 10³–10¹⁰ trophozoites orally using a 1 mL syringe. Fecal pellets were collected every day from each mouse into vials containing sodium acetic acid formalin and the presence of *D. fragilis* was investigated by light microscopy of iron haematoxylin stained fecal smears. The weight, stool consistency and the data on the pattern of shedding were recorded every day during the study (summarized in Supplementary information).

Sprague Dawley rats were given (by a 1 mL syringe) a fecal suspension containing *D. fragilis* cysts obtained from infected Balb/C mice. The fecal suspension was prepared from feces of infected Balb/C mice where the presence of cysts was confirmed *via* iron haematoxylin staining. Fecal samples containing *D. fragilis* cysts were suspended in PBS and thoroughly mixed into a suspension that was administered orally to rats. Fecal samples of infected rats were collected every day post infection, pooled and used for TEM (described below).

Transmission electron microscopy

The methods used are as follows (Munasinghe *et al.*, 2013). Pooled fecal pellets from infected mice or rats were collected and resuspended in PBS. Fecal debris was removed by centrifugation at 500 g for 10 min. The supernatant containing cysts was centrifuged at 1500 g for 10 min to pellet the cysts which were washed 3 times with PBS by centrifugation and resuspension in PBS. The pellets containing cysts were fixed in 3% glutaraldehyde in PBS (pH 7.2) at room temperature overnight from all animals where shedding of *D. fragilis* could be confirmed by light microscopy of iron haematoxylin stained fecal smears. The fixed fecal specimens containing cysts were centrifuged at 500 g for 10 min. The fixatives were removed and PBS added. This washing step with PBS was repeated 3 times for 15 min for each wash. Cell pellets were then embedded in 2% low melt agarose. The agar blocks were cut into 1 mm cubes and post fixed in 1% osmium tetroxide in PBS for 1 h at room temperature. Following post fixation, the samples were washed in distilled water 3 times for 15 min each and subsequently immersed in 2% aqueous uranyl acetate for 30 min. The pellets were dehydrated through a graded series of

ethanols (50–100%), infiltrated in mixtures of ethanol and L.R. White Resin (London Resin) and subsequently embedded in LR White Resin. Semi-thin and ultra-thin sections were cut using a Reichert Ultracut S ultramicrotome (Leica Microsystems, North Ryde, NSW, Australia). Semi-thin sections (1 μm thickness) were stained with 1% methylene blue and observed by transmitted light microscopy (Olympus BH2, Olympus, Japan). Ultra-thin sections (70 nm) were mounted onto pioloform coated, 300-mesh, thin-bar copper grids, stained with saturated aqueous uranyl acetate (7.7%) for 30 min and Reynold's lead citrate (Reynolds, 1963) for 4 min, rinsed with milliQ H_2O after each stain. Ultrathin sections were examined using a Philips CM10 transmission electron microscope (Eindhoven, Netherlands).

Results

Resistance of trophozoites to acid pH

Infection of mice with *D. fragilis* trophozoites led to the presence of cysts in stool. These observations suggest that cultured trophozoites could survive the pH conditions found in the mouse stomach which is typically pH 3 (fed) and pH 4 (fasted) and higher than that found in the human stomach (McConnell *et al.*, 2008). In order to investigate the ability of trophozoites to withstand exposure to extremes of pH, cultured trophozoites were resuspended in PBS adjusted to different pH levels and incubated for periods of time up to 6 h. After incubation, the viability of the cells was assessed by cell counts with a trypan blue viability stain. Our main conclusion was that trophozoites were unable to withstand acidic pH conditions below pH 3 for 2 h, as judged by viable cell counts (Fig. 1). The susceptibility of trophozoites to extremes of pH suggests that *D. fragilis* cannot easily survive the pH conditions found in the human which typically range from 1 to 3 (Hong *et al.*, 2005).

Transmission electron microscopy of cysts

The ultrastructure of the cell wall and other organelles including nuclei and flagellar axonemes was examined. *Dientamoeba fragilis* cysts had a well-developed cyst wall and the parasite was enclosed within. Twenty *D. fragilis* cysts from the rats were measured and the cyst diameter fell within range 4–6 μm . The cyst diameter of the 5 cysts from the mice was 4–5 μm , with the range found in the rat model.

Nuclei

Cysts contained either 1 (Fig. 2A; 80% of cysts seen) or 2 nuclei (Fig. 2A; 20% of cysts seen) in the TEM planes analysed. The nuclear membrane was not visible in some cysts (Fig. 2A). The nucleolus was located centrally in the nucleus (Figs 2A and 3A).

The nucleus as far as it existed in the cutting plane showed an ovoid or an irregular shape. In all cysts with a single nucleus observed, no nuclear membrane was visible (Fig. 2A) which could be due to the difficulty in distinguishing the membrane from the often dense cytoplasmic contents. In contrast, cysts with 2 observed nuclei contained a nuclear membrane that was visible as described previously (Munasinghe *et al.*, 2013). A clear nucleolus was seen which is electron dense, fragmented, irregular in shape and lacks a membrane.

Cyst wall

The cyst wall consisted of an outer layer and an inner layer (Munasinghe *et al.*, 2013). The outer cyst wall contained fibrillar elements which appeared to be dense and had a uniform thickness (approximately 0.2 μm) (Figs 2A and 3A). The outer cyst

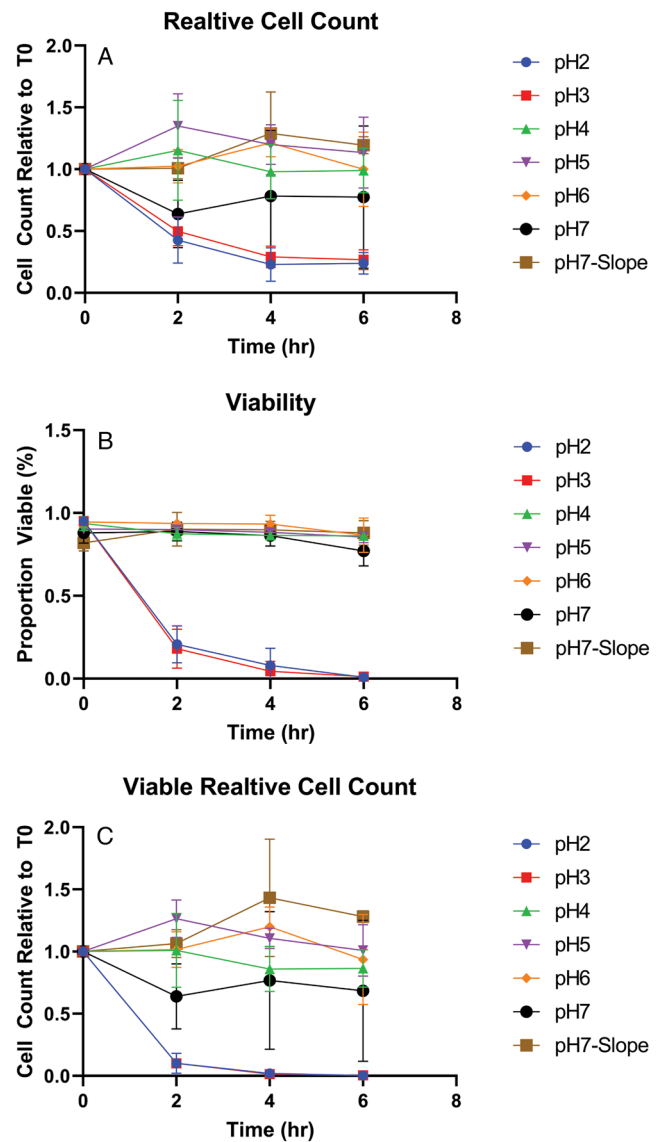


Figure 1. Viability of *D. fragilis* *in-vitro* following incubation at acid pH. *Dientamoeba fragilis* trophozoites were incubated in PBS at different pH levels (2–7) and negative control condition with a Loeffler slope (pH7-Slope) for 0–6 h. The graphs show the resulting total cell counts relative to T0 (a), viable proportion (b) and relative viable cell counts (c). The error bars represent standard error of mean cell counts, performed in triplicate.

wall was coated by a glycocalyx (Fig. 3D). There were dark striations along the outer fibrillar cyst wall (Fig. 3D). The inner cyst wall consists of 2 layers which collectively appear as a dark margin outlining the parasite (Fig. 2D).

Encystation specific vesicles (ESVs)

The presence of ESV-like structures in the cyst was described previously (Munasinghe *et al.*, 2013). A weakening in the inner membrane of the encysted parasite occurs which is surrounded by vesicles in the peritrophic space (Fig. 3B, F). These weakened areas of the inner cyst membrane resemble areas which liberate the ESV-like structures from the encysted parasite into the peritrophic space. This is similar to that process which occurs in *Giardia* cysts where the ESVs are exported from inside the cyst to the periphery of the cell for deposition (Carpenter *et al.*, 2012).

Cytoplasm

Other organelles were not as visible in the cyst as in the trophozoite stage of *D. fragilis*, although the endoplasmic reticulum (ER)

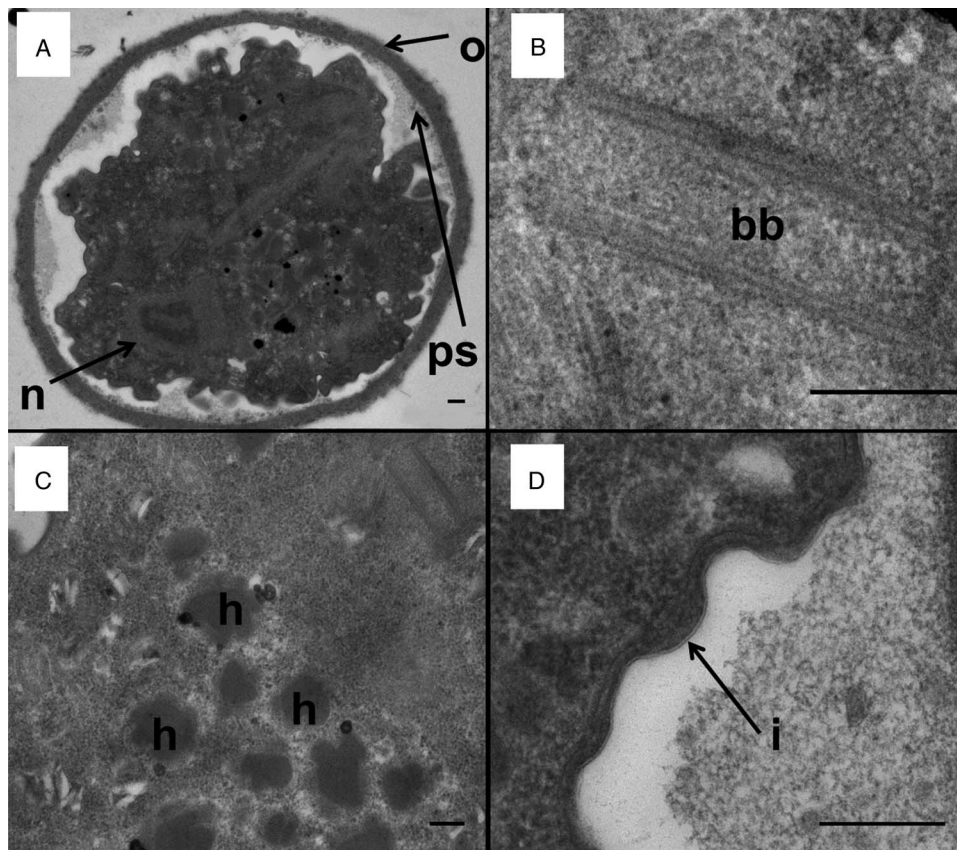


Figure 2. Transmission electron micrographs of a *D. fragilis* cyst showing the cyst wall and other organelles. (A) Transverse section across a mononucleated cyst showing the outer fibrillar cyst wall (o), peritrophic space (ps) and the nucleus of the encysted parasite (n). (B) Basal body structure (bb). (C) Developing hydrogenosomes which contain a dense core and a less electron-dense outer layer (h). (D) The inner membrane of the cyst wall (i). Scale bar represents 200 nm.

and structures that are morphologically similar to Golgi bodies were easily identifiable (Fig. 3E, F). Electron-dense particles that measure 0.1–0.2 μm could be seen scattered across the cytoplasm which are similar in appearance to glycogen granules reported in the trophozoites of *D. fragilis* (Banik *et al.*, 2012) and other trichomonads (Munsch *et al.*, 2009) (Fig. 3C). ER was scattered around the cytoplasm (Fig. 3E).

Hydrogenosomes

Hydrogenosomes are double layered membrane bound, electron-dense organelles located in the cytoplasm of the *D. fragilis* cyst. They ranged in size from 0.3 to 0.4 μm and the number present in cysts ranged from 10 to 12 (Fig. 3C). The hydrogenosomes in some cysts were spherical in shape, bound with a double membrane, electron dense and located in the cytoplasm. In some cysts, the hydrogenosomes had an appearance of a ‘cauliflower shape’, the size ranging from 0.33 to 0.38 μm ($n=6$) and the number present varied from 4 to 20 (Fig. 2C). These ‘cauliflower-type’ hydrogenosomes possessed an outer layer which was less electron dense and an inner core which was more electron dense. Some of these had an outer membrane (Fig. 2C). The hydrogenosomes in some cysts contained a homogeneous matrix (Fig. 3C). Glycogen granules were also often observed near both types of hydrogenosomes.

Basal body structure

A structure that looks similar to a basal body was present in *D. fragilis* cysts (Fig. 2B). The cysts also possessed an axostyle, flagellar axonemes, pelta and a costa (Munasinghe *et al.*, 2013).

Discussion

To our knowledge, our report of a cyst stage in the life cycle of *D. fragilis* and the successful establishment of an animal model to study infection and transmission was important in providing evidence that transmission of *D. fragilis* may occur through a fecal–oral process *via* a cyst stage (Munasinghe *et al.*, 2013). In this study, we extend these observations by showing that trophozoites are susceptible to acid exposure, and so are unlikely to be able to withstand the extremes of pH found in the human gastrointestinal tract (discussed below). We also provide a description of the cyst stage as studied by TEM. These studies also complement and extend those of the trophozoite stage of *D. fragilis* (Banik *et al.*, 2012).

The treatment of trophozoites with PBS of pH less than 7 was carried out to determine the effect of extreme acid pH on the survival of *D. fragilis* trophozoites. The results showed that *D. fragilis* trophozoites were unable to survive for 2 h in pH 3 or less. This represents an important finding since it demonstrates that *D. fragilis* is not tolerant of environmental extremes, supporting the long-held dogma of the ‘fragile’ nature of this organism. After ingestion *via* the fecal–oral route, *D. fragilis* must travel through the stomach into the gut where it has to survive an acidic pH which is usually 1.8–2.0 in a healthy human (Hong *et al.*, 2005) for 1–6 h depending on stomach content (Feldman *et al.*, 1984; Meyer *et al.*, 1988; Pal *et al.*, 2007). Trophozoites were infrequently found in the feces of infected mice and rats compared to the relative abundance of cysts, suggesting that *D. fragilis* cysts may play a role in zoonotic transmission of this organism. Alternatively, this could indicate that the development of cysts is upregulated when conditions are not favourable for the multiplication of *D. fragilis*, such as finding itself in the wrong host. In

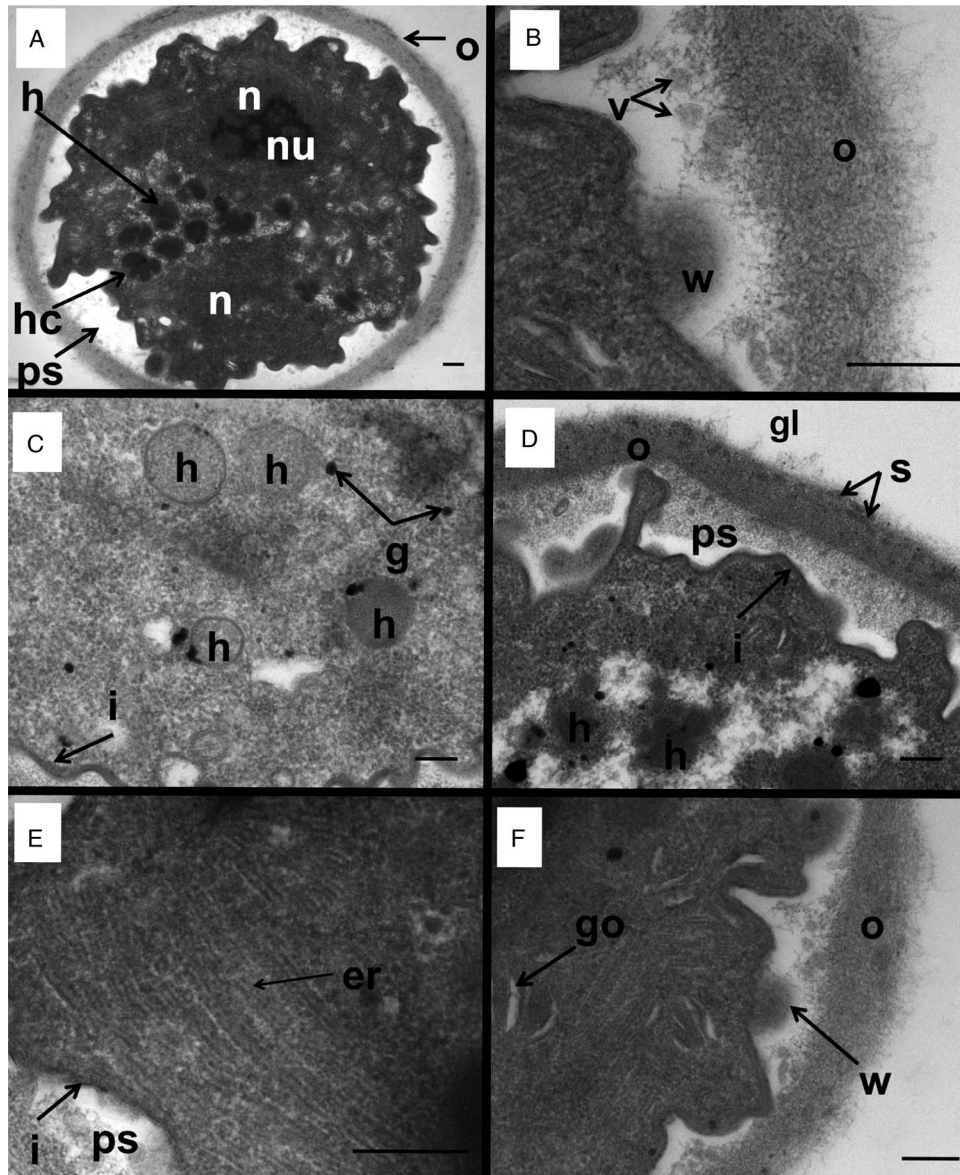


Figure 3. Transmission electron micrographs of a *D. fragilis* cyst showing the whole cyst and other organelles and structures. (A) Transverse section across a binucleated cyst showing the outer cyst wall (o), the peritrophic space (ps), the 2 nuclei (n) nucleolus (nu). Note the hydrogenosomes (h) and the ‘cauliflower-like’ hydrogenosomes (hc) that lie in the space between the margins of the 2 nuclei. (B) A closer view of the outer cyst wall (o). Note the weakened area of the inner membrane (w) lying directly next to the ESV-like structures (v). (C) Hydrogenosomes (h), glycogen granules (g) and the inner membrane of the cyst (i). (D) Electron micrograph of the outer cyst wall (o) showing the dark striations (s) and coated in a glycocalyx (gl), the inner membrane (i), the peritrophic space (ps). Note the developing hydrogenosomes with the darker inner core and less electron-dense outer layer (h). (E) Smooth endoplasmic reticulum (er), inner cyst membrane (i) and peritrophic space (ps). (F) Golgi complex of *D. fragilis* cyst: weakening of the inner membrane (w); outer cyst wall (o).

contrast, in humans the major morphological forms found are trophozoites (Stark *et al.*, 2010). Precystic forms are rarer and cyst forms almost never seen (Stark *et al.*, 2014a). Recent studies confirmed the identification of cysts from human clinical samples which are morphologically similar to the cysts that were found in this study (Abd, 2021; Garcia, 2016; Stark *et al.*, 2014a). The frequency in which cysts are reliably found in human clinical samples leads us to believe that human-to-human transmission may not be the dominant form of transmission for *D. fragilis* and that transmission from animals may be a significant contributor to human infection.

The observation that the trophozoite of *D. fragilis* is unable to resist acidic conditions might appear to be in contradiction to the establishment of a *D. fragilis* model in mice using cultured trophozoites (Munasinghe *et al.*, 2013). It is important to note, that cultured trophozoites were unable to establish infections in rats; in contrast, a suspension of mouse feces containing cysts

was able to result in infection. After the establishment of the mouse model, a study determined that a dose of 10^5 trophozoites per mouse was required for a 37% chance to establish infections in mice using the oral route and showed a 100% infection with a dose of 4×10^6 trophozoites per mouse (El-Gayar *et al.*, 2016). This is higher than in our experiments as the minimum infectious dose was 10^5 and 10^3 in our second experiment. This impact could be a result of how *D. fragilis* adapts to growing in culture. The isolate that we selected for this study was the one that we were culturing which grew most readily (data not shown). Compared to the infective dose of other gastrointestinal protozoa, this is potentially higher: greater than 1 cyst for *Entamoeba coli* (Rendtorff, 1954), greater than 1000 cysts for *E. histolytica* (Ryan *et al.*, 2004), 30–1000 oocysts for *Cryptosporidium parvum* (DuPont *et al.*, 1995) and 10–10 000 cysts for *G. intestinalis* (Schaefer *et al.*, 1991). Compared to the healthy pH range of 1.8–2.0 in the stomach of humans (Hong *et al.*, 2005), the pH

range of the stomach in a mouse is 3.0–4.0 (McConnell *et al.*, 2008). It is important to note that the pH range of the rat stomach is 3.2–3.9, which is similar to a mouse, so the pH of the stomach cannot solely explain the failure to establish an infection in a rat using trophozoites (McConnell *et al.*, 2008). Mice have a shorter gut transit time than rats which may limit the exposure of *D. fragilis* trophozoites to acid in their stomach in comparison (Giron *et al.*, 2016). We speculate these differences have allowed for the establishment of the mouse model.

Our observations that trophozoites cannot withstand acid pH treatments are consistent with the mechanisms of transmission involving either the pre-cyst, cyst stage or *E. vermicularis* vector. Evidence for the role of *E. vermicularis* as a vector of *D. fragilis* infection includes detecting *D. fragilis* DNA inside pinworm ova (Clark *et al.*, 2014; Ögren *et al.*, 2013; Roser *et al.*, 2013). While these results are certainly compelling, this still does not indicate that the organisms within are viable or transmissible, as previously suggested (Clark *et al.*, 2014). In previous studies on the use of hypochlorite to destroy DNA, a 2.5–3% solution (w/v) was recommended for at least 15–40 min (Greenstone *et al.*, 2012; Kemp and Smith, 2005). It is likely that this sterilization procedure employed in those studies on *D. fragilis* may have been insufficient to remove DNA (Ögren *et al.*, 2013; Roser *et al.*, 2013). A final step of DNAase treatment appears preferable to ensure that all exogenous DNA had been completely removed. Indeed, a similar experiment which employed DNase treatment found that DNA of *D. fragilis* was not detected within *E. vermicularis* ova (Menghi *et al.*, 2005). Additionally, *E. vermicularis* is a human-specific Oxyurid nematode, with rare identifications in captive chimpanzees (Murata *et al.*, 2002). The identification of *D. fragilis* in a variety of non-human hosts (Chan *et al.*, 2016; Galán-Puchades *et al.*, 2021; Hegner and Chu, 1930; Knowles and Gupta, 1936; Lankester *et al.*, 2010; Stark *et al.*, 2008; Yetismis *et al.*, 2022; Yildiz and Erdem Aynur, 2022) indicates that a model of transmission using *E. vermicularis* as a vector responsible for its transmission is unlikely. In our study, rodents were not infected with pinworm. Notably, rodent pinworms belong either to the *Syphacia* and *Aspicularis* genera, not *Enterobius* like the human pinworm (Meade and Watson, 2014). For the helminth vector model to remain, a non-species-specific helminth must be involved which has yet to be identified, or the mechanism by which *D. fragilis* enter the ova must not be species-specific. The variety of *D. fragilis* hosts supports the importance of the cyst model of transmission. Further studies are required to ascertain the exact life cycle and mode of transmission of this parasite.

TEM of the *D. fragilis* cysts showed they had a spherical to ovoid shape with a thick cyst wall that is filamentous in appearance. The overall structure of the cysts observed in this paper and our previous study shows remarkable similarity to the cysts of *Trichomonitus batrachorum* and *Trichomonitus sanguisugae* including the presence of a peritrophic space and axoneme (Brugerolle, 1973; Munasinghe *et al.*, 2013). The cyst wall contained 2 layers: an outer dense fibrillar layer and a double-membrane bilayer enclosing the encysted parasite. Thus, the cyst wall of *D. fragilis* is similar to that of *T. batrachorum*, *T. sanguisugae*, *Honigbergiella sp.* and *Giardia* which also has an outer fibrillar layer and an inner double layer which is continuous with the plasma membrane of the trophozoite (Brugerolle, 1973; Coggins and Schaefer, 1986; Hampl *et al.*, 2007). The outer cyst wall consisted of a meshwork of fibrillar elements whereas the inner bilayer encloses the parasite. There is a space between the cyst wall and the encysted parasite which is similar to the peritrophic space reported in *Giardia* cysts (Coggins and Schaefer, 1986). Similar to the cyst of *Honigbergiella sp.*, the outer cyst wall is coated with a glycocalyx (Hampl *et al.*, 2007). This space

shrinks in mature *D. fragilis* cysts where the plasma membrane is closely attached to the cyst wall as seen in *Entamoeba* species (García-Zapién *et al.*, 1999).

Despite these similarities, there were some structural differences in the cyst wall of *Giardia* and *D. fragilis*. The cyst wall of *Giardia* contains a filamentous outer layer and 2 cell membranes separated from the plasma membrane of the parasite by a peritrophic space (Chávez-Munguía *et al.*, 2004). In *D. fragilis*, the cyst wall contains an outer filamentous portion and an inner bilayer membrane enclosing the parasite. The peritrophic space was present between the outer layer and the inner bilayer. Fibrillar material is also present in the cyst wall of *Entamoeba* species (García-Zapién *et al.*, 1999). In *Entamoeba invadens*, the cyst wall is a single continuous fibrillar layer which is closely associated with the plasma membrane (Chávez-Munguía *et al.*, 2007). In *Acanthamoeba castellanii* which is a free-living amoeba, the cyst wall is a double-layered structure which includes the ectocyst and endocyst (Chávez-Munguía *et al.*, 2007) which is not seen in *D. fragilis*. The cyst wall of *D. fragilis* was different to the precyst stage described in *Histomonas meleagridis* which is a close relative of *D. fragilis* (Barratt *et al.*, 2011) where a fibrillar-dense cyst wall was absent instead it contained only an outer amorphous zone (Zaragatzki *et al.*, 2010).

Immediately beneath the cyst wall as well as inside the peritrophic space, there were numerous double-membrane vesicles which are similar to the ESVs described in *Giardia* cysts (Chávez-Munguía *et al.*, 2007). Some of these vesicles were also seen embedded in the cyst wall. It has been suggested that in *Giardia* cysts, these ESVs contain material that forms the fibrillar component of the cyst wall (Reiner *et al.*, 1990). These ESVs were described as spherical and electron dense in *Giardia* which contain condensed material that goes on to form the cyst wall (Hehl and Marti, 2004). Formation and maturation of large ESVs (up to 1 µm in diameter) is functionally linked to the regulation of cyst wall proteins and evidence suggests that ESVs represent a novel Golgi equivalent in *Giardia* (Hehl *et al.*, 2000; Marti *et al.*, 2003). In *Entamoeba* species, similar forms of small vesicles are present close to the plasma membrane which is involved in a process of depositing granular material to the cell wall (Chávez-Munguía and Martínez-Palomo, 2011). In *Acanthamoeba*, vesicles with a similar appearance are present in the cytoplasm of mature cysts and the fibrillar content inside these vesicles resembles the appearance of the endocyst and ectocyst wall (Chávez-Munguía *et al.*, 2005). Overall, we speculate that ESVs are present in the *D. fragilis* cyst. We also speculate that the mechanisms of cyst wall formation are probably *Giardia*-like, mainly because of the morphological similarities seen by TEM between this species and *D. fragilis*.

The enclosed parasite within the cyst wall was amoeboid in appearance. There were small spherical particles that appeared across the cytoplasm which are deemed to be free ribosomes. These are also apparent in *Histomonas* pseudocysts (Mielewczik *et al.*, 2008). The ER was scattered throughout the cytoplasm and around the nuclear region and glycogen granules were present which has also been described in *H. meleagridis* (Munsch *et al.*, 2009). Although the nuclear membrane was often not visible, a clear nucleolus was present at the centre of the nucleus.

Hydrogenosomes are found in several trichomonad species and other anaerobic protozoa living in oxygen-poor environments. The hydrogenosome contains enzymes that participate in pyruvate metabolism and formation of ATP (Benchimol, 2009). The gene for pyruvate : ferredoxin oxidoreductase was identified in the transcriptome of *D. fragilis* along with other hydrogenosomal ATP synthases (Barratt *et al.*, 2015). Therefore, the hydrogenosomes are the main energy-producing organelles in *D. fragilis* cysts. Hydrogenosomes were present in all the

cysts observed. Some of these were spherical in shape which was similar to those seen in the trophozoite stage (Banik *et al.*, 2012). In some cysts, hydrogenosomes were irregular in shape ('cauliflower-like') with irregular inclusions. These irregular-shaped hydrogenosomes do not appear to have been reported before in any other protozoa. Other irregular hydrogenosomes have been identified in *Tritrichomonas foetus*, having a 'heart'-shaped morphology (Benchimol, 2009). We suggest the unusual appearance of the hydrogenosomes we describe is linked to a reorganization of membranous structures that occur during cyst development or a division process similar to that described in Benchimol (2009).

A basal body structure containing an axostyle and costa was observed in *D. fragilis* trophozoites. Additionally, the cyst of *D. fragilis* contains a pelta and flagella which were not found in the trophozoite (Banik *et al.*, 2012). Previous phylogenetic studies resulted in the inclusion of *D. fragilis* in the Parabasalia purely on the presence of hydrogenosomes (Cepicka *et al.*, 2010; Silberman *et al.*, 1996). The loss of the pelta axostyle complex was seen as a derived trait. The results presented here and in Munasinghe *et al.* (2013) of the presence of internal flagella and pelta in the encysted parasite are therefore important. The pelta is a crescent-shaped sheet which could be found along the periphery of the nucleus (Munasinghe *et al.*, 2013). The pelta apparently supports the periflagellar canal from which the flagella emerge in the trichomonads (Benchimol *et al.*, 2000). The costa is found only in trichomonads which possess an undulating membrane and it is assumed that its function is to provide mechanical support to the undulating membrane (Benchimol, 2010). Although the costa and pelta structure are visible in *D. fragilis*, no external flagella, undulating membrane or axonemes are seen in the peritrophic space. Therefore, although these structures may be remnants derived from an evolutionary ancestor, they do provide further ultrastructural evidence for *D. fragilis* to be classified as a trichomonad. In the *H. meleagridis* life cycle, however, an amoeboid stage, cyst-like stage and a flagellated stage have been identified (Munsch *et al.*, 2009). As *D. fragilis* is a close relative of *Histomonas* sp., we wonder whether there is a further life cycle stage of *D. fragilis* waiting to be discovered.

During encystment, many biochemical and cellular changes occur in the cell including the production of a cyst wall (Chávez-Munguía *et al.*, 2007). In *E. invadens*, *Giardia* and *Acanthamoeba* species that have been studied extensively, encystation can be divided into several phases. The observations reported here suggest that *D. fragilis* undergoes similar reorganization of its internal structures. For example, the loss of the nuclear membranes and the presence of hydrogenosomes with unusual shape and structure suggest that cyst formation involves extensive cellular remodelling, which includes reorganization of membrane-bound organelles. In *Giardia* cysts, a similar process of remodelling occurs where the nuclei membranes fuse and disappear and exchange genetic information during encystation (Carpenter *et al.*, 2012). We presume similar processes may be occurring in *D. fragilis*.

The identification of cysts containing 1 or 2 nuclei suggests the cyst probably contains a single cell. The most prominent change that occurs during the encystation of protozoan parasites is the synthesis of cyst wall components and their transport to the cell membrane *via* ESVs which release their contents to the cell surface through exocytosis (Chávez-Munguía *et al.*, 2003). ESVs do not occur in non-encysting trophozoites of *Giardia* (Benchimol, 2002). In *Giardia*, ESVs fuse with the plasma membrane and release their contents to the exterior leaving behind empty vesicles that are found in the peritrophic space (Hehl and Marti, 2004). In *D. fragilis*, numerous ESV-like structures were present in the peritrophic space. These preliminary observations of a cyst wall and

the presence of ESV-like structures suggest a mechanism for cyst wall formation in *D. fragilis* similar to that in *Giardia*.

Conclusion

The current study demonstrated that *D. fragilis* trophozoites cannot withstand extreme pH conditions present in the human stomach, showing that fecal–oral transmission *via* the trophozoite to humans is possible but improbable. This highlights the need for further studies into both the cyst stage and *Enterobius vermicularis* ova vector models of transmission. Cyst forms are the dominant morphological form found in experimentally infected rodent feces; it is possible that the cyst form plays an important role in the zoonotic transmission. The transmission electron microscopic studies revealed the close similarity of the cysts ultrastructure of *D. fragilis* and other trichomonads, especially *Histomonas* which further highlights the presence of a cyst stage in the life cycle. All these findings have important implications for dientamoebiasis and advance our knowledge on the recurrent nature and transmission of the disease.

Supplementary material. The supplementary material for this article can be found at <https://doi.org/10.1017/S0031182024000076>

Data availability statement. The authors confirm that the data supporting the findings of this study are available within the article and its supplementary materials.

Acknowledgements. We thank Debra Birch (Macquarie University) for her advice and assistance in specimen processing and image interpretation. This work was supported by Sydpath, St. Vincent Hospital, Darlinghurst and the University of Technology Sydney. This research was performed by L. M. H. and V. S. M. in partial fulfilment of a PhD at UTS. The graphical abstract was created in BioRender under agreement number ED26486CAW.

Author contributions. L. M. H.: methodology, data curation, investigation, writing – original draft, review and editing. V. S. M.: conceptualization, investigation, writing – original draft. N. G. F. V.: investigation, supervision. J. T. E.: conceptualization, methodology, supervision, writing – review and editing. D. S.: conceptualization, supervision, writing, resources

Financial support. The research was supported by St Vincent's Hospital, SydPath, Department of Microbiology.

Competing interest. None.

Ethical standards. These experiments were completed to the standards of the Australian Research Council Codes and Guidelines. HREC approval was obtained through the HREC at St Vincent's Hospital Sydney for the establishment of cultures from clinical specimens. ACEC approval was obtained through UTS.

References

- Abd H (2021) *Dientamoeba fragilis* trophozoites undergoing encystation, apoptosis and necrosis as human parasitic amoeba in clinical stool samples. *European Academic Research* IX, 4633–4649.
- Banik GR, Birch D, Stark D and Ellis JT (2012) A microscopic description and ultrastructural characterisation of *Dientamoeba fragilis*: an emerging cause of human enteric disease. *International Journal for Parasitology* 42, 139–153.
- Barratt JLN, Banik GR, Harkness J, Marriott D, Ellis JT and Stark D (2010) Newly defined conditions for the in vitro cultivation and cryopreservation of *Dientamoeba fragilis*: new techniques set to fast track molecular studies on this organism. *Parasitology* 137, 1867–1878.
- Barratt JL, Harkness J, Marriott D, Ellis JT and Stark D (2011) The ambiguous life of *Dientamoeba fragilis*: the need to investigate current hypotheses on transmission [review]. *Parasitology* 138, 557–572.
- Barratt JL, Cao M, Stark DJ and Ellis JT (2015) The transcriptome sequence of *Dientamoeba fragilis* offers new biological insights on its metabolism,

- kinome, degradome and potential mechanisms of pathogenicity. *Protist* **166**, 389–408.
- Benchimol M** (2002) A new set of vesicles in *Giardia lamblia*. *Experimental Parasitology* **102**, 30–37.
- Benchimol M** (2009) Hydrogenosomes under microscopy. *Tissue & Cell* **41**, 151–168.
- Benchimol M** (2010) The mastigont system in trichomonads. In de Souza W (ed.), *Structures and Organelles in Pathogenic Protists*, vol. 17. Berlin: Springer Berlin Heidelberg, pp. 1–26.
- Benchimol M, Diniz JA and Ribeiro K** (2000) The fine structure of the axostyle and its associations with organelles in trichomonads. *Tissue & Cell* **32**, 178–187.
- Brugerolle G** (1973) Sur 'existence de vrais kystes chez les trichomonades intestinales. Ultrastructure des kystes de *Trichomitus batrachorum* Perty 1852, *Trichomitus sanguisugae* Alexeff 1911, et *Monocercomonas tipulae* Mackinnon 1910. *Comptes Rendus de l'Académie des Sciences. Paris* **277**, 2193–2196.
- Carpenter ML, Assaf ZJ, Gourguechon S and Cande WZ** (2012) Nuclear inheritance and genetic exchange without meiosis in the binucleate parasite *Giardia intestinalis*. *Journal of Cell Science* **125**, 2523–2532.
- Cepicka I, Hampf V and Kulda J** (2010) Critical taxonomic revision of parabasalids with description of one new genus and three new species. *Protist* **161**, 400–433.
- Chan D, Barratt J, Roberts T, Phillips O, Šlapeta J, Ryan U, Marriott D, Harkness J, Ellis J and Stark D** (2016) Detection of *Dientamoeba fragilis* in animal faeces using species specific real time PCR assay. *Veterinary Parasitology* **227**, 42–47.
- Chávez-Munguía B and Martínez-Palomo A** (2011) High-resolution electron microscopical study of cyst walls of *Entamoeba* spp. *Journal of Eukaryotic Microbiology* **58**, 480–486.
- Chávez-Munguía B, Cristóbal-Ramos AR, González-Robles A, Tsutsumi V and Martínez-Palomo A** (2003) Ultrastructural study of *Entamoeba invadens* encystation and excystation. *Journal of Submicroscopic Cytology and Pathology* **35**, 235–243.
- Chávez-Munguía B, Cedillo-Rivera R and Martínez-Palomo A** (2004) The ultrastructure of the cyst wall of *Giardia lamblia*. *Journal of Eukaryotic Microbiology* **51**, 220–226.
- Chávez-Munguía B, Omaña-Molina M, González-Lázaro M, González-Robles A, Bonilla P and Martínez-Palomo A** (2005) Ultrastructural study of encystation and excystation in *Acanthamoeba castellanii*. *Journal of Eukaryotic Microbiology* **52**, 153–158.
- Chávez-Munguía B, Omaña-Molina M, González-Lázaro M, González-Robles A, Cedillo-Rivera R, Bonilla P and Martínez-Palomo A** (2007) Ultrastructure of cyst differentiation in parasitic protozoa. *Parasitology Research* **100**, 1169–1175.
- Clark CG, Röser D and Stensvold CR** (2014) Transmission of *Dientamoeba fragilis*: pinworm or cysts? *Trends in Parasitology* **30**, 136–140.
- Coggins JR and Schaefer III FW** (1986) *Giardia muris*: ultrastructural analysis of in vitro excystation. *Experimental Parasitology* **61**, 219–228.
- Dobell C** (1940) Researches on the intestinal protozoa of monkeys and man: X. The life-history of *Dientamoeba fragilis*: observations, experiments, and speculations. *Parasitology* **32**, 417–461.
- DuPont HL, Chappell CL, Sterling CR, Okhuysen PC, Rose JB and Jakubowski W** (1995) The infectivity of *Cryptosporidium parvum* in healthy volunteers. *New England Journal of Medicine* **332**, 855–859.
- El-Gayar EK, Mokhtar AB and Hassan WA** (2016) Study of the pathogenic potential of *Dientamoeba fragilis* in experimentally infected mice. *Parasite Epidemiology Control* **1**, 136–143.
- Feldman M, Smith HJ and Simon TR** (1984) Gastric emptying of solid radiopaque markers: studies in healthy subjects and diabetic patients. *Gastroenterology* **87**, 895–902.
- Galán-Puchades MT, Treliis M, Sáez-Durán S, Cifre S, Gosálvez C, Sanxis-Furió J, Pascual J, Bueno-Marí R, Franco S, Peracho V, Montalvo T and Fuentes MV** (2021) One health approach to zoonotic parasites: molecular detection of intestinal protozoans in an urban population of Norway rats, *Rattus norvegicus*, in Barcelona, Spain. *Pathogens* **10**, 311. <https://doi.org/10.3390/pathogens10030311>
- García-Zapién AG, González-Robles A and Mora-Galindo J** (1999) Congo red effect on cyst viability and cell wall structure of encysting *Entamoeba invadens*. *Archives of Medical Research* **30**, 106–115.
- Garcia LS** (2016) *Dientamoeba fragilis*, one of the neglected intestinal protozoa [review]. *Journal of Clinical Microbiology* **54**, 2243–2250.
- Giron R, Perez-Garcia I and Abalo R** (2016) X-ray analysis of gastrointestinal motility in conscious mice. Effects of morphine and comparison with rats. *Neurogastroenterology and Motility* **28**, 74–84.
- Greenstone MH, Weber DC, Coudron TA, Payton ME and Hu JS** (2012) Removing external DNA contamination from arthropod predators destined for molecular gut-content analysis. *Molecular Ecology Resources* **12**, 464–469.
- Hampf V, Cepicka I, Flegr J, Tachezy J and Kulda J** (2007) Morphological and molecular diversity of the Monocercomonadid genera *Monocercomonas*, *Hexamastix*, and *Honigbergiella* gen. nov. *Protist* **158**, 365–383.
- Hegner R and Chu HJ** (1930) A comparative study of the intestinal protozoa of wild monkeys and man*. *American Journal of Epidemiology* **12**, 62–108.
- Hehl AB and Marti M** (2004) Secretory protein trafficking in *Giardia intestinalis*. *Molecular Microbiology* **53**, 19–28.
- Hehl AB, Marti M and Köhler P** (2000) Stage-specific expression and targeting of cyst wall protein-green fluorescent protein chimeras in *Giardia*. *Molecular Biology of the Cell* **11**, 1789–1800.
- Hong W, Jiao W, Hu J, Zhang J, Liu C, Fu X, Shen D, Xia B and Chang Z** (2005) Periplasmic protein HdeA exhibits chaperone-like activity exclusively within stomach pH range by transforming into disordered conformation. *Journal of Biological Chemistry* **280**, 27029–27034.
- Jepps MW and Dobell C** (1918) *Dientamoeba fragilis*. A new intestinal amoeba from man. *Parasitology* **10**, 352–367.
- Johnson EH, Windsor JJ and Clark CG** (2004) Emerging from obscurity: biological, clinical, and diagnostic aspects of *Dientamoeba fragilis* [review]. *Clinical Microbiology Reviews* **17**, 553–570, table of contents.
- Kean BH and Malloch CL** (1966) The neglected amoeba: *Dientamoeba fragilis*. A report of 100 'pure' infections. *The American Journal of Digestive Diseases* **11**, 735–746.
- Kemp BM and Smith DG** (2005) Use of bleach to eliminate contaminating DNA from the surface of bones and teeth. *Forensic Science International* **154**, 53–61.
- Knoll EW and Howell KM** (1946) Studies on *Dientamoeba fragilis*; its incidence and possible pathogenicity. *Med* **53**, 40–46.
- Knowles R and Gupta B** (1936) Some observations on the intestinal protozoa of macaques. *The Indian Journal of Medical Research* **24**, 547–556.
- Lankester F, Kiyang JA, Bailey W and Unwin S** (2010) *Dientamoeba fragilis*: initial evidence of pathogenicity in the western lowland gorilla (*Gorilla gorilla gorilla*). *Journal of Zoo and Wildlife Medicine* **41**, 350–352.
- Marti M, Li Y, Schraner EM, Wild P, Köhler P and Hehl AB** (2003) The secretory apparatus of an ancient eukaryote: protein sorting to separate export pathways occurs before formation of transient Golgi-like compartments. *Molecular Biology of the Cell* **14**, 1433–1447.
- McConnell EL, Basit AW and Murdan S** (2008) Measurements of rat and mouse gastrointestinal pH, fluid and lymphoid tissue, and implications for in-vivo experiments. *Journal of Pharmacy and Pharmacology* **60**, 63–70.
- Meade TM and Watson J** (2014) Characterization of rat pinworm (*Syphacia muris*) epidemiology as a means to increase detection and elimination. *Journal of the American Association for Laboratory Animal Science* **53**, 661–667.
- Menghi C, Makiya R, Gatta C and Méndez OC** (2005) *Dientamoeba fragilis*: molecular biology techniques for the elucidation of its mode of transmission. *Parasitología Latinoamericana* **60**, 25–31.
- Meyer JH, Elashoff J, Porter-Fink V, Dressman J and Amidon GL** (1988) Human postprandial gastric emptying of 1-3-millimeter spheres. *Gastroenterology* **94**, 1315–1325.
- Mielewicz M, Mehlhorn H, Al-Quraishy S, Grabensteiner E and Hess M** (2008) Transmission electron microscopic studies of stages of *Histomonas meleagridis* from clonal cultures. *Parasitology Research* **103**, 745–750.
- Munasinghe VS, Vella NG, Ellis JT, Windsor PA and Stark D** (2013) Cyst formation and faecal-oral transmission of *Dientamoeba fragilis* – the missing link in the life cycle of an emerging pathogen. *International Journal for Parasitology* **43**, 879–883.
- Munsch M, Lotfi A, Hafez HM, Al-Quraishy S and Mehlhorn H** (2009) Light and transmission electron microscopic studies on trophozoites and cyst-like stages of *Histomonas meleagridis* from cultures. *Parasitology Research* **104**, 683–689.
- Murata K, Hasegawa H, Nakano T, Noda A and Yanai T** (2002) Fatal infection with human pinworm, *Enterobius vermicularis*, in a captive chimpanzee. *Journal of Medical Primatology* **31**, 104–108.
- Ögren J, Dienus O, Löfgren S, Iveroth P and Matussek A** (2013) *Dientamoeba fragilis* DNA detection in *Enterobius vermicularis* eggs. *Pathogens and Disease* **69**, 157–158.

- Pal A, Brasseur JG and Abrahamsson B (2007) A stomach road or 'Magenstrasse' for gastric emptying. *Journal of Biomechanics* **40**, 1202–1210.
- Piekarski G (1948) Zur Frage der Cystenbildung bei *Dientamoeba fragilis*. *Medical Microbiology and Immunology* **127**, 496–500.
- Reiner DS, McCaffery M and Gillin FD (1990) Sorting of cyst wall proteins to a regulated secretory pathway during differentiation of the primitive eukaryote, *Giardia lamblia*. *European Journal of Cell Biology* **53**, 142–153.
- Rendtorff RC (1954) The experimental transmission of human intestinal protozoan parasites. I. *Endamoeba coli* cysts given in capsules. *American Journal of Hygiene* **59**, 196–208.
- Reynolds ES (1963) The use of lead citrate at high pH as an electron-opaque stain in electron microscopy. *Journal of Cell Biology* **17**, 208–212.
- Roser D, Nejsum P, Carlsgart AJ, Nielsen HV and Stensvold CR (2013) DNA of *Dientamoeba fragilis* detected within surface-sterilized eggs of *Enterobius vermicularis*. *Experimental Parasitology* **133**, 57–61.
- Ryan K, Kenneth J, Ray C and Sherris J (2004) *Sherris Medical Microbiology: An Introduction to Infectious Diseases*, 4th Edn. United States: McGraw-Hill. <https://doi.org/10.1036/0838585299>.
- Schaefer FW, Johnson CH, Hsu CH and Rice EW (1991) Determination of *Giardia lamblia* cyst infective dose for the Mongolian gerbil (*Meriones unguiculatus*). *Applied and Environmental Microbiology* **57**, 2408–2409.
- Silard R, Colea A, Panaitescu D, Florescu P and Roman N (1979) Studies on *Dientamoeba fragilis* in Romania. I. *Dientamoeba fragilis* isolated from clinical cases. Problems of diagnosis, incidence, clinical aspects. *Archives Roumaines de Pathologie Experimentales et de Microbiologie* **38**, 359–372.
- Silberman JD, Clark CG and Sogin ML (1996) *Dientamoeba fragilis* shares a recent common evolutionary history with the trichomonads. *Molecular and Biochemical Parasitology* **76**, 311–314.
- Stark DJ, Beebe N, Marriott D, Ellis JT and Harkness J (2006) *Dientamoebiasis*: clinical importance and recent advances. *Trends in Parasitology* **22**, 92–96.
- Stark D, Phillips O, Peckett D, Munro U, Marriott D, Harkness J and Ellis J (2008) Gorillas are a host for *Dientamoeba fragilis*: an update on the life cycle and host distribution. *Veterinary Parasitology* **151**, 21–26.
- Stark D, Barratt J, Roberts T, Marriott D, Harkness J and Ellis J (2010) Comparison of microscopy, two xenic culture techniques, conventional and real-time PCR for the detection of *Dientamoeba fragilis* in clinical stool samples. *European Journal of Clinical Microbiology & Infectious Diseases* **29**, 411–416.
- Stark D, Al-Qassab SE, Barratt JLN, Stanley K, Roberts T, Marriott D, Harkness J and Ellis JT (2011) Evaluation of multiplex tandem real-time PCR for detection of *Cryptosporidium* spp., *Dientamoeba fragilis*, *Entamoeba histolytica*, and *Giardia intestinalis* in clinical stool samples. *Journal of Clinical Microbiology* **49**, 257–262.
- Stark D, Garcia LS, Barratt JLN, Phillips O, Roberts T, Marriott D, Harkness J and Ellis JT (2014a) Description of *Dientamoeba fragilis* cyst and precystic forms from human samples. *Journal of Clinical Microbiology* **52**, 2680–2683.
- Stark D, Roberts T, Ellis JT, Marriott D and Harkness J (2014b) Evaluation of the EasyScreen™ enteric parasite detection kit for the detection of *Blastocystis* spp., *Cryptosporidium* spp., *Dientamoeba fragilis*, *Entamoeba complex*, and *Giardia intestinalis* from clinical stool samples. *Diagnostic Microbiology and Infectious Disease* **78**, 149–152.
- Stark D, Barratt J, Chan D and Ellis JT (2016) *Dientamoeba fragilis*, the neglected trichomonad of the human bowel. *Clinical Microbiology Reviews* **29**, 553–580.
- Wenrich D (1936) Studies on *Dientamoeba fragilis* (Protozoa). I. Observations with special reference to nuclear structure. *The Journal of Parasitology* **22**, 76–83.
- Wenrich DH (1944) Studies on *Dientamoeba fragilis* (Protozoa). IV. Further observations, with an outline of present-day knowledge of this species. *The Journal of Parasitology* **30**, 322–338.
- Yetismis G, Yildirim A, Pekmezci D, Duzlu O, Ciloglu A, Onder Z, Simsek E, Ercan N, Pekmezci GZ and Inci A (2022) First report and genotyping of *Dientamoeba fragilis* in pet budgerigars (*Melopsittacus undulatus*), with zoonotic importance. *Zoonoses and Public Health* **69**, 572–578.
- Yildiz İ and Erdem Aynur Z (2022) First detection and molecular characterization of *Dientamoeba fragilis* in cattle. *Zoonoses and Public Health* **69**, 897–903.
- Zaragatzki E, Hess M, Grabensteiner E, Abdel-Ghaffar F, Al-Rasheid KA and Mehlhorn H (2010) Light and transmission electron microscopic studies on the encystation of *Histomonas meleagridis*. *Parasitology Research* **106**, 977–983.