

Distal Sciatic Nerve Compression by a Popliteal Artery Aneurysm

Yves Beaudry, John D. Stewart and Lee Errett

ABSTRACT: A 77-year-old man developed progressive sensory and motor symptoms in the right lower leg. Examination showed neurological deficits in the distribution of the right tibial and common peroneal nerves. Swellings in both popliteal fossae were palpated. Investigation showed these to be large thrombosed aneurysms. On surgical examination on the right, the aneurysm was found to be compressing the distal sciatic nerve.

RÉSUMÉ: Compression distale du nerf sciatique par un anévrisme de l'artère poplitée Des symptômes sensitifs et moteurs se sont développés progressivement au niveau de la partie inférieure de la jambe droite chez un homme âgé de 77 ans. L'examen a montré un déficit neurologique dans le territoire des nerfs sciatique poplitée interne et externe droits, ainsi qu'une tuméfaction à la palpation des creux poplités droit et gauche. Une investigation a montré que ces tuméfactions étaient de gros anévrismes trombosés. À la chirurgie, il s'est avéré que l'anévrisme du creux poplitée droit comprimait le segment distal du nerf sciatique.

Can. J. Neurol. Sci. 1989; 16: 352-353

Masses in the popliteal fossa can produce neurological symptoms by compressing the distal sciatic nerve, the tibial and/or the common peroneal nerves. Of these, the tibial nerve is usually affected, and the most frequent causes are ganglia and Baker's cysts.^{1,2,3} Popliteal aneurysms also cause swelling in this area, but apart from one brief mention,⁴ nerve compression by such aneurysms appears not to have been described in detail before.

CASE REPORT

A 77-year-old man with diffuse atherosclerosis and claudication in both legs presented with paresthesias in the sole of his right foot and leg weakness of two months duration. He denied back pain or sciatica. On examination, the right iliopsoas, quadriceps and hamstring muscles were normal but the muscles supplied by the tibial and common peroneal nerves were weak: the tibialis anterior, peroneal and extensor digitorum muscles, tibialis posterior and intrinsic foot muscles were all grade 4/5; the extensor hallucis longus was 2/5; the gastrocnemius was 4+/5. Sensation was decreased over the dorsum and the sole of the right foot, and the right ankle jerk was absent. There were no neurological abnormalities in the left leg. The right foot was cool and had no palpable pulses. There was a 4 cm diameter non-pulsatile mass in the superior aspect of the right popliteal fossa, and a pulsatile mass in the inferior aspect of the left popliteal fossa (Figure 1).

Investigations Motor nerve conduction studies of the right posterior tibial and common peroneal nerves showed marked reduction of the compound motor action potential amplitudes (100 µV each), and mild-moderate slowing of conduction (knee-ankle motor conduction velocities of 36.5 and 30.5 m/sec respectively). The right sural sensory action potential was absent. Concentric needle electromyography of the hamstring muscles was normal, while the weak muscles listed above showed varying degrees of denervation and neurogenic changes. Thus the clinical and electrophysiological findings indicated incomplete

damage to either the distal sciatic nerve or both the tibial and common peroneal nerves.

Ultrasound and doppler studies of the popliteal fossae showed 4 x 4 cm masses containing calcification and thrombus, and no flow in the popliteal artery, suggestive of thrombosed aneurysms (Figure 2). Arteriograms showed the same but with some flow into a single small distal artery on the right and adequate distal blood flow on the left.

Treatment At surgery a thrombosed popliteal artery aneurysm (10 x 7 cm) was found in the upper portion of the right popliteal fossa. The sciatic nerve, which had a low bifurcation, was severely compressed just proximal to its bifurcation into the tibial and peroneal nerves; resection of the aneurysm entailed dissecting the nerve from the wall of the aneurysm. A saphenous vein graft was inserted with restoration of excellent blood flow. Unfortunately, the patient had a fatal myocardial infarction six days later.

DISCUSSION

Most sciatic neuropathies occur in the proximal portion of the nerve, at the level of the hip; damage in the mid-thigh or upper popliteal fossa is much less common.⁵⁻⁷ The differential diagnosis of a popliteal swelling includes Baker cysts, ganglia, intra-neural cysts, tumors of peripheral nerves and popliteal artery aneurysms. To our knowledge, this is the first detailed report of sciatic nerve involvement by a popliteal artery aneurysm. The nerve damage presumably was the result of compression but occlusion of vasa nervora arising from the popliteal artery is another possible mechanism. These uncommon aneurysms usually present in one of four ways: sudden occlusion with ischemic damage distally, thrombosis and distal embolization, rupture or venous obstruction.⁸ Although nerve damage appears to be rare, this adds a fifth way in which popliteal aneurysms may produce symptoms.

From the Departments of Medicine and Surgery, McGill University and The Montreal General Hospital, Montreal

Received August 25, 1988. Accepted in final form May 16, 1989

Reprint requests to: Dr. John D. Stewart, The Montreal Neurological Institute, 3801 University, Montreal, Quebec, Canada H3A 2B4

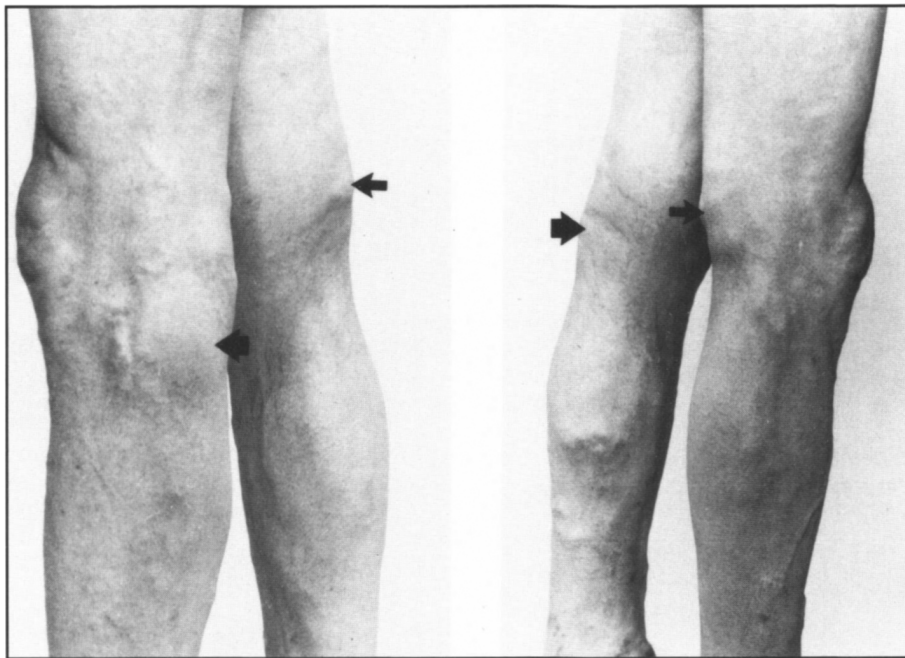

Figure 1 – Photographs of both legs from an oblique view to show the swelling in the right (smaller arrow) and left (larger arrow) popliteal fossae.

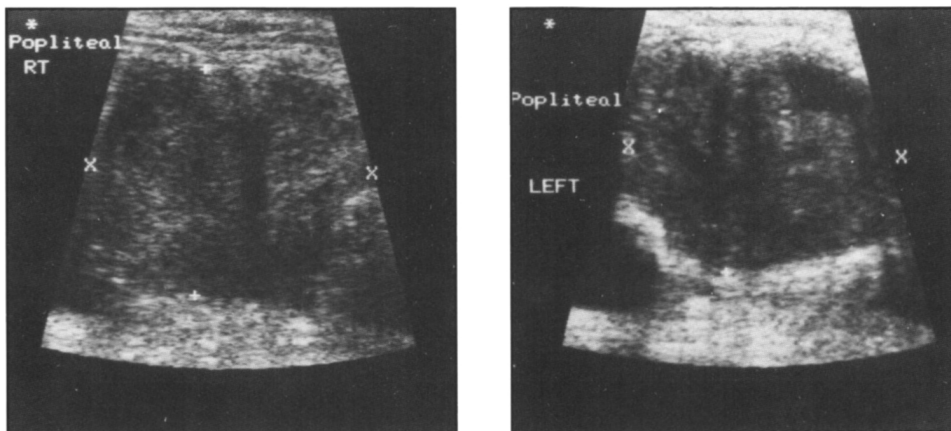


Figure 2 – Ultrasound studies of the popliteal fossae to show large areas of reduced density with inner areas of variable increased density, suggesting popliteal aneurysms containing clots and calcifications.

REFERENCES

1. Brooks DM. Nerve compression by simple ganglia: a review of thirteen collected cases. *J Bone Joint Surg* 1952; 34B: 391-400.
2. Stack RE, Bianco AJ, MacCarty CS. Compression of the common peroneal nerve by ganglion cysts: report of nine cases. *J Bone Joint Surg* 1965; 47A: 773-778.
3. Nakana KK. Entrapment neuropathy from Baker's cyst. *JAMA* 1978; 239: 1350.
4. Turek SL. *Orthopedics: Principles and their applications*. Third Edition. Philadelphia: J.B. Lippincott Co 1977: 716.
5. Sunderland S. *Nerves and Nerve Injuries*. Second Edition. Edinburgh: Churchill Livingstone 1978.
6. Stewart JD, Angus E, Gendron D. Sciatic neuropathies. *Br Med J* 1983; 287: 1108-1109.
7. Stewart JD. *Focal Peripheral Neuropathies*. New York: Elsevier 1987.
8. Gifford RW Jr, Hines EA Jr, Janes JM. An analysis and follow-up study of one hundred popliteal aneurysms. *Surgery* 1953; 33: 284-293.