




Grey matter volume predicts improvement in geriatric depression in response to Tai Chi compared to Health Education

Beatrix Krause-Sorio,¹  Prabha Siddarth,¹ Michaela M. Milillo,¹  Lisa Kilpatrick,¹ Linda Ercoli,¹ Katherine L. Narr,² and Helen Lavretsky¹ 

¹Department of Psychiatry and Biobehavioral Sciences, Semel Institute for Neuroscience and Human Behavior, University of California, Los Angeles, CA, USA

²Department of Neurology, University of California Los Angeles, Los Angeles, CA, USA

ABSTRACT

Objectives: Geriatric depression (GD) is associated with cognitive impairment and brain atrophy. Tai-Chi-Chih (TCC) is a promising adjunct treatment to antidepressants. We previously found beneficial effects of TCC on resting state connectivity in GD. We now tested the effect of TCC on gray matter volume (GMV) change and the association between baseline GMV and clinical outcome.

Participants: Forty-nine participants with GD (>=60 y) underwent antidepressant treatment (38 women).

Intervention: Participants completed 3 months of TCC ($N=26$) or health and wellness education control (HEW; $N=23$).

Measurements: Depression and anxiety symptoms and MRI scans were acquired at baseline and 3-month follow-up. General linear models (GLMs) tested group-by-time interactions on clinical scores. Freesurfer 6.0 was used to process T1-weighted images and to perform voxel-wise whole-brain GLMs of group on symmetrized percent GMV change, and on the baseline GMV and symptom change association, controlling for baseline symptom severity. Age and sex served as covariates in all models.

Results: There were no group differences in baseline demographics or clinical scores, symptom change from baseline to follow-up, or treatment-related GMV change. However, whole-brain analysis revealed that lower baseline GMV in several clusters in the TCC, but not the HEW group, was associated with larger improvements in anxiety. This was similar for right precuneus GMV and depressive symptoms.

Conclusions: While we observed no effect on GMV due to the interventions, baseline regional GMV predicted symptom improvements with TCC but not HEW. Longer trials are needed to investigate the long-term effects of TCC on clinical symptoms and neuroplasticity.

Key words: geriatric depression, gray matter volume, Tai Chi

Introduction

The prevalence of geriatric depression (GD) ranges from 10 to 15% in the population of over 60-years-old adults (Ismail *et al.*, 2013). GD has debilitating consequences, including lower remission rates, poor daily functioning and treatment prognosis, and comorbid cognitive impairment, which increases the risk of injuries and falls, and results in frequent

hospitalization (Carpenter *et al.*, 2014; Tunvirachaisakul *et al.*, 2018). Approximately 70% of patients respond to selective serotonin reuptake inhibitors (SSRIs) after 8–12 weeks of treatment (Chen *et al.*, 2011) and even fewer (30–40%) achieve remission (Nelson *et al.*, 2008) that puts individual at risk for higher mortality and morbidity and suicide (Alexopoulos, 2019). GD is further associated with brain atrophy across large portions of the frontal, temporal and parietal lobes (Mackin *et al.*, 2013). Such structural abnormalities are linked with cognitive dysfunction (Kim and Han, 2021). While some regions appear to decline, other regions show increased gray matter. For instance, thicker cortices

Correspondence should be addressed to: Helen Lavretsky, Department of Psychiatry, Semel Institute for Neuroscience and Behavior, 760 Westwood Plaza, University of California Los Angeles, Los Angeles, CA, 90024, USA. Phone: +1 (310) 794 4619. Email: hlavretsky@mednet.ucla.edu Received 28 Aug 2023; revision requested 15 Sep 2023; revised version received 19 Oct 2023; accepted 30 Oct 2023.

in the right isthmus cingulate and the left precuneus were associated with higher depressive symptom severity (Szymkowicz *et al.*, 2016). Several meta-analyses reported reductions in GMV in GD, including in the hippocampus, amygdala, the right lentiform nucleus and parts of the parahippocampal region, medial frontal and orbitofrontal cortices, the right subcallosal gyrus, the putamen and the thalamus compared to healthy older adults (Du *et al.*, 2014; Sexton *et al.*, 2013).

Several studies have investigated antidepressant-induced structural brain changes in geriatric depression. Greater increases in frontal gray matter volume (GMV) were associated with greater improvements in depressive symptom severity after three months of treatment with venlafaxine (Droppa *et al.*, 2017). The authors of this study suggested that antidepressant treatment may restore previous declines in cortical volume in regions related to depressive symptoms. In our laboratory, we found reductions in cortical thickness after three months of treatment with levomilnacipran, a serotonin-norepinephrine reuptake inhibitor (SNRI), compared to a placebo in geriatric depression (Krause-Sorio *et al.*, 2019). Similarly, we observed increases in cortical thickness and GMV in the left inferior and middle temporal cortices and the right medial and lateral orbitofrontal cortex (OFC) after three months of combined treatment with escitalopram (SSRI) plus memantine, a cognitive booster compared to escitalopram combined with a placebo in geriatric depression (Krause-Sorio *et al.*, 2020). In both cases, the structural brain changes occurred independent of differences in clinical outcomes, which may suggest that cortical changes are more sensitive to antidepressant treatment than behavioral/symptom changes.

In addition, we previously reported increased orbitofrontal GMV in geriatric depression with a history of antidepressant use compared to drug-naïve participants, which suggests that antidepressant treatment may have long-term protective effects on brain morphometry (Lavretsky *et al.*, 2005). In another 3-month trial of escitalopram in geriatric depression, researchers found that baseline components of the anterior cingulate cortex (ACC), which is strongly linked to symptom severity in major depressive disorder (MDD), were smaller in patients who eventually failed to achieve remission compared to those who did achieve remission (Gunning *et al.*, 2009). The same group later found that greater cortical thickness in the insula was associated with larger improvements in apathy after 3 months of escitalopram treatment (Pimontel *et al.*, 2020). Another study found reduced cortical thickness in bilateral posterior cingulate and parahippocampal cortices, left insula, precuneus, cuneus

and paracentral cortex and the right medial OFC and lateral occipital cortex in GD patients that did not respond to psychotherapy, compared to treatment responders (Mackin *et al.*, 2013).

Together, these results suggest that structural magnetic resonance imaging (MRI) measures may be used as markers of antidepressant treatment response in depression.

Tai Chi is rooted in the ancient Chinese martial arts but is used now as a mind-body exercise for stress reduction. Tai Chi involves low-impact, aerobic physical exercise, as well as body and breath awareness and has the benefit of no side effects or drug interactions. Tai Chi is known to improve balance and fear of falling in older adults, who have an increased risk of falls, with high rates of injuries and subsequent hospitalization, loss of independence and mortality (Gazibara *et al.*, 2017; Hosseini *et al.*, 2018; WHO, 2007). Tai Chi therefore can offer multiple benefits to older adults with depression that will help reduce depression severity along with other health benefits (Yeung *et al.*, 2017). Our laboratory previously discovered an increased likelihood of improvements in symptom severity and achieving remission in older depressed adults undergoing 16 weeks of combined escitalopram and Tai Chi treatment compared to those receiving escitalopram and health education control (Lavretsky *et al.*, 2011). We subsequently demonstrated an improvement in general health in older adults with depression in a larger study (Lavretsky *et al.*, 2022), along with an increase in functional connectivity in 167 pairwise region-to-region connections, including default mode network regions in Tai Chi compared to health education control (Kilpatrick *et al.*, 2022; Lavretsky *et al.*, 2022). To our best knowledge, no study to date has examined the effect of Tai Chi on GMV in geriatric depression. We therefore tested here the effect of three months of Tai Chi, compared to a health education control, on GMV change. In addition, we tested whether baseline GMV predicts symptom improvement, measured by reductions in scores on standardized psychiatric scales for depression and anxiety, in a population of older adults with major depressive disorder undergoing a 3-month Tai Chi intervention compared to a health education control.

Methods

Participants

One hundred and seventy-eight older adults over age 60 with major depressive disorder who have been stable on antidepressant treatment for at least four months participated in the parent study (NCT02460666, (Lavretsky *et al.*, 2022)).

One hundred and twenty-five completed the 3-month clinical assessment. At baseline, 49 were eligible and willing to undergo an MRI scan, and were randomized to either Tai-Chi-Chih (TCC) ($N=26$, 21 women, mean age = 67.6, SD = 6.7) or Health and Wellness Education (HEW) groups ($N=23$, 17 women, mean age = 68.4, SD = 5.5). Of these 49 participants, 40 also completed a second scan after completion of the intervention at three months (TCC $N=21$, HEW $N=19$). The screening was performed by a trained staff member to assess physical and cognitive problems. Eligibility criteria were: 1) a score of (Ramachandran *et al.*, 2011) ≥ 15 reflecting moderate to severe depression on the 24-item Hamilton Depression Rating Scale (HAMD-24, (Hamilton, 1960; Hamilton, 1967)); 2) a Mini-Mental State Examination Score greater than 24 (MMSE, (Folstein *et al.*, 1975)); 3) sufficient English proficiency to follow the interventions, including at least an 8th-grade reading level assessed using the word reading subtest of the Wide Range Achievement Test-IV (Wilkinson & Robertson, 2006); 4) the capacity to provide informed consent; 5) stable antidepressant treatment for at least 4 months prior to the beginning of participation. Exclusion criteria included 1) a history of other psychiatric conditions, such as psychosis, bipolar disorder, drug or alcohol dependence, or a neurological disorder; 2) disabilities, such as severe visual or hearing impairment that could prevent participation in the intervention; 4) insufficient English proficiency; 5) a diagnosis of dementia; 6) an MMSE score below 24; 7) effective antidepressant treatment or psychotropic medication; 7) psychotherapy with cognitive training components; 8) a HAMD score <15 . Additionally, MRI exclusion criteria involved unsafe or unverifiable safe metallic implants, permanent makeup, tattoos in the head and neck region and claustrophobia. All participants provided written informed consent for participation in the trial as approved by the UCLA Institutional Review Board (IRB). This study was conducted in accordance with the Declaration of Helsinki of 1975.

Clinical measures

Depressive symptom severity, the main outcome variable of the parent trial, at baseline and 3-month follow-up was assessed using the Hamilton Depression Rating Scale (HAMD-24, (Hamilton, 1960; Hamilton, 1967)). We additionally administered the Montgomery-Asberg Depression Scale (MADRS) (Montgomery *et al.*, 1985). Furthermore, anxiety was assessed using the Hamilton Anxiety Scale (HAMA) (Hamilton, 1959). Group differences in clinical characteristics were evaluated using the

nonparametric Kruskal-Wallis test for continuous variables, and Fisher's exact test for categorical variables. Group differences in post-intervention HAMD/MADRS/HAMA scores were evaluated using nonparametric ANCOVAs controlling for pre-intervention values.

Interventions

Participants underwent 12 weeks of weekly 60-minute classes in both TCC and HEW.

Each group consisted of 6–8 participants and trained experts conducted the classes. Both groups received homework assignments including a daily minimum of 20 minutes of effort in performing TCC training based on training materials on a CD or wellness-topic internet searchers for HEW. Participants were informed that the treatment groups involved “exercise and wellness education” in order to equalize expectations across treatments and they were blind to the differences in interventions. In addition, they were unaware of the main outcomes of interest, including symptomatic, functional, and cognitive improvements. In addition, after the 6-month follow-up, participants were offered to attend the intervention they had not participated in during the trial. The research staff performing neuropsychological testing and symptom assessments were blind to the condition of the participants.

The TCC classes were adaptations from a procedure described in “Tai-Chi-Chih! Joy Through Movement” (Stone, 1996). Each Tai Chi class consisted of a warmup (10 minutes of stretching and breathing) and a cool-down (5 minutes). The HEW group provided a social setting similar to the TCC group. Classes were based on a manual and presentations including educational information, learning objectives and activities that helped the participants to consolidate and integrate the learned materials. Both groups were instructed to complete 20 minutes of homework daily in between weekly sessions. Adherence was assessed on a weekly basis with research staff and the principal investigator. Additional details regarding the non-imaging portion of the study design can be found in our previous publication (Lavretsky *et al.*, 2022).

Procedure

Participants underwent initial phone screening and proceeded to in-person screening if they met the inclusion criteria. The baseline visit began with the participant signing their written informed consent and baseline measures included mood and cognitive assessments, as well as vital signs (pulse rate, systolic blood pressure, body weight and electrocardiogram, ECG). If the participant qualified for the study, a baseline MRI scan was performed.

MRI acquisition and analysis

Structural 3D T1-weighted multi-echo magnetization-prepared rapid gradient-echo sequence images were acquired at the Ahmanson & Lovelace Brain Mapping Center at UCLA using a Siemens 3T Prisma system (Siemens, Erlangen, Germany) with a 32-channel head coil (TEs = 1.74, 3.6, 5.46, and 7.32 ms; TR = 2,530 ms; TI = 1,260 ms; flip angle = 7°; voxel size = 1 mm³; double GRAPPA and matrix size = 256 × 192; acquisition time = 5:18 min). Freesurfer 6.0 (<http://surfer.nmr.mgh.harvard.edu>) was used to perform cortical reconstruction. Preprocessing involved magnetic field inhomogeneity corrections, non-brain tissue removal from the image, and parcellation and segmentation of cortical and subcortical gray matter from white matter and cerebrospinal fluid. Subsequently, the automated longitudinal reconstruction pipeline was used to create a subject-specific template and register individual baseline and follow-up scans to the template (Reuter *et al.*, 2012). The resulting scans were visually inspected for tissue misclassifications and misalignment of baseline-to-follow-up scans. Manual corrections were undertaken wherever necessary. Resulting cortical maps were smoothed with a Gaussian kernel of 10 mm full-width half-maximum. First, whole-brain volume- and surface-based longitudinal voxel-wise two-stage GLMs were performed for each hemisphere using qdec (www.surfer.nmr.mgh.harvard.edu). In the longitudinal model, group served as the between-group factor and symmetrized percent change (spc) in GMV and cortical thickness as the dependent variable. SPC is the change rate with respect to the average volume or thickness, i.e. $100 * (\text{annualized rate between time point 1 and time point 2}) / \text{average volume or thickness}$. The model accounts for the time between scans, i.e., corrects for individual differences in inter-scan intervals. Therefore, spc allows for both positive and negative numbers (i.e. GMV increase or decrease). An increase in GMV from baseline to follow-up will be reflected by positive numbers, while a decrease will be indicated by negative numbers (Reuter and Fischl, 2011). Second, we performed whole-brain voxel-wise GLMs with group as the between-group factor, and baseline GMV and clinical change as continuous variables (12-week minus baseline score). This model tested group differences in the relationship between GMV and clinical improvement, using interaction terms. Age and sex served as covariates in all models and the respective baseline clinical score was additionally included in the prediction models. The voxel threshold and Monte-Carlo corrected cluster thresholds were set to $p < 0.05$. Finally, we compared the correlations of baseline GMV and clinical change in TCC and HEW by conducting a Fisher's z-test of the z-transformed correlation coefficients.

Results

Forty-nine participants completed a baseline scan. Baseline demographics and clinical data, including post-intervention scores for the forty completers, are summarized in Table 1. There were no significant group differences in demographics or clinical scores at baseline and the groups did not differ in their changes in HAMD, MADRS and HAMA. Both groups showed significant improvements in all three scores. Additionally, there was no significant difference between groups in homework compliance (average number of days per week).

GMV

No clusters emerged from the time × group analysis on GMV change. However, interaction tests from the whole-brain analysis revealed several clusters that showed group differences in the relationship between baseline GMV and change in MADRS and HAMA scores (Figures 1 and 2). Lower baseline GMV in the right pericalcarine cortex, extending into the lingual cortex, was associated with greater improvement in MADRS in the TCC group ($r = 0.52$, $p = .007$) but not in the HEW group ($r = -0.31$, $p = .2$; Fisher's $z = 2.8$, $p = .005$). Similarly, lower baseline GMV in four clusters was associated with greater improvements in HAMA in the TCC group (right pericalcarine/parahippocampal cortex: $r = 0.55$, $p = .004$; left middle temporal cortex: $r = 0.39$, $p = .05$; left lateral occipital cortex: $r = 0.39$, $p = .05$; left lingual/isthmus cortices: $r = 0.47$, $p = .01$). In contrast, the HEW group did not show any association between baseline GMV and change in anxiety (right pericalcarine/parahippocampal cortex: $r = -0.18$, $p = .4$; left middle temporal cortex: $r = -0.19$, $p = .4$; left lateral occipital cortex: $r = -0.25$, $p = .3$; left lingual/isthmus cortices: $r = -0.14$, $p = .5$), and further, all tests comparing the correlations in TCC and HEW were found to be significant (Fisher's z ranging from 2.0 to 2.5, $p = 0.05 - .01$). The clusters for anxiety included the right pericalcarine cortex and the left lingual-to-isthmus, lateral occipital, and a long cluster from the posterior to the pole of the middle temporal cortex dipping superiorly into the insula. In the left lateral occipital cortex, one HEW participant appeared to be an outlier. However, removal of this data point did not change the findings.

Discussion

We did not find any group differences in changes in depression, anxiety or GMV in the TCC group compared to an active HEW control group over the course of 3 months in 49 older adults with MDD; however, group differences existed in the

Table 1. Demographic and clinical characteristics of participants

<i>N</i> = 49	TCC (<i>N</i> = 26)	HEW (<i>N</i> = 23)	GROUP DIFFERENCE <i>P</i> -VALUE
Sex	21 women/5 men	17 women/6 men	0.7
Age (years)	67.6 (6.7)	68.4 (5.5)	0.5
Education	16.0 (1.8)	16.0 (2.2)	0.9
Race, <i>n</i> (%)			
White	19 (73)	20 (87)	0.8
Asian	2 (8)	1 (4)	
Black	2 (8)	1 (4)	
Hispanic	1 (4)	1 (4)	
Other	2 (8)		
BMI	25.8 (4.9)	27.3 (7.4)	0.7
MMSE	29.0 (1.3)	29.0 (1.0)	0.5
Homework (d/wk)	4.5 (2.3)	4.3 (3.0)	0.9
HAMD			
Pre-intervention	18.9 (3.7)	18.2 (3.3)	0.5
Post-intervention*	8.5 (5.9)	9.9 (4.5)	0.3
MADRS			
Pre-intervention	17.8 (4.3)	15.3 (4.5)	0.1
Post-intervention*	10.3 (6.9)	11.6 (4.5)	0.2
HAMA			
Pre-intervention	11.5 (3.5)	10.0 (3.6)	0.5
Post-intervention*	6.8 (4.4)	6.2 (2.8)	0.8

Means and standard deviations shown. BMI = Body Mass Index, MMSE = Mini-Mental State Examination, HAMD = Hamilton Depression Rating Scale, HAMA = Hamilton Anxiety Scale, MADRS = Montgomery-Asberg Depression Scale. Group differences evaluated using Kruskal-Wallis test for continuous variables, and Fisher’s exact test for categorical variables.

*Post-intervention scores are available for 40 participants (TCC = 21, HEW = 19). Group differences in post-intervention scores were evaluated controlling for pre-intervention values. Within-group changes evaluated using Wilcoxon signed rank tests were as follows: TCC: HAMD median change, -10.0, *p* < .0001; MADRS median change, -6.0, *p* < .0001; HAMA median change, -4.0, *p* < .003; HEW: HAMD median change, -6.0, *p* < .0001; MADRS median change, -3.0, *p* < .03; HAMA median change, -4.0, *p* < .001.

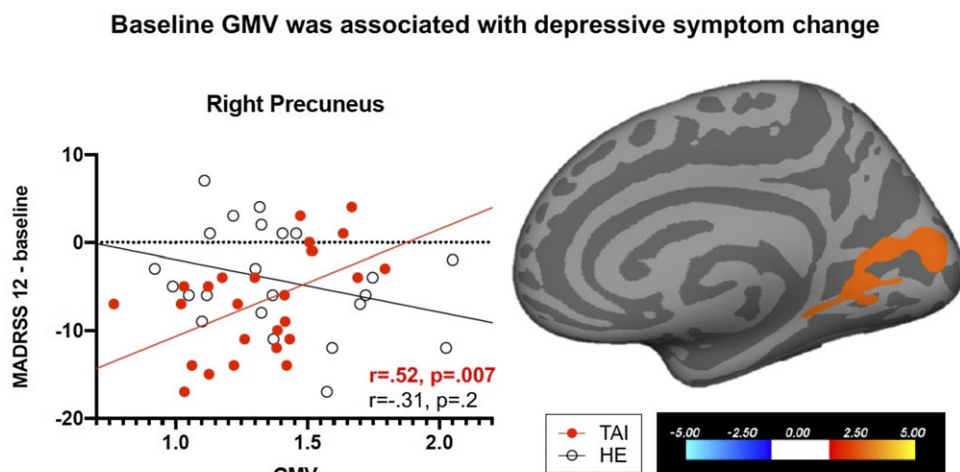


Figure 1. Group differences in the association between GMV and depressive symptom change. Smaller baseline GMV was associated with larger depression improvements in the TCC, but not in the HEW group.

relationship between baseline GMV and symptom change. In the TCC group, lower baseline right hemisphere pericalcarine-to-lingual GMV was associated with greater depressive symptom improvements. Similarly, in the TCC group, greater improvements in anxiety were related to lower GMV in the right pericalcarine cortex extending into

the parahippocampal region, the left middle temporal and lateral occipital, and the border of the lingual and isthmus cortices. These relationships were not found in the HEW group. These results suggest that TCC intervention effects may depend on the individual’s existing neuroanatomical characteristics. While the mechanism behind this effect is

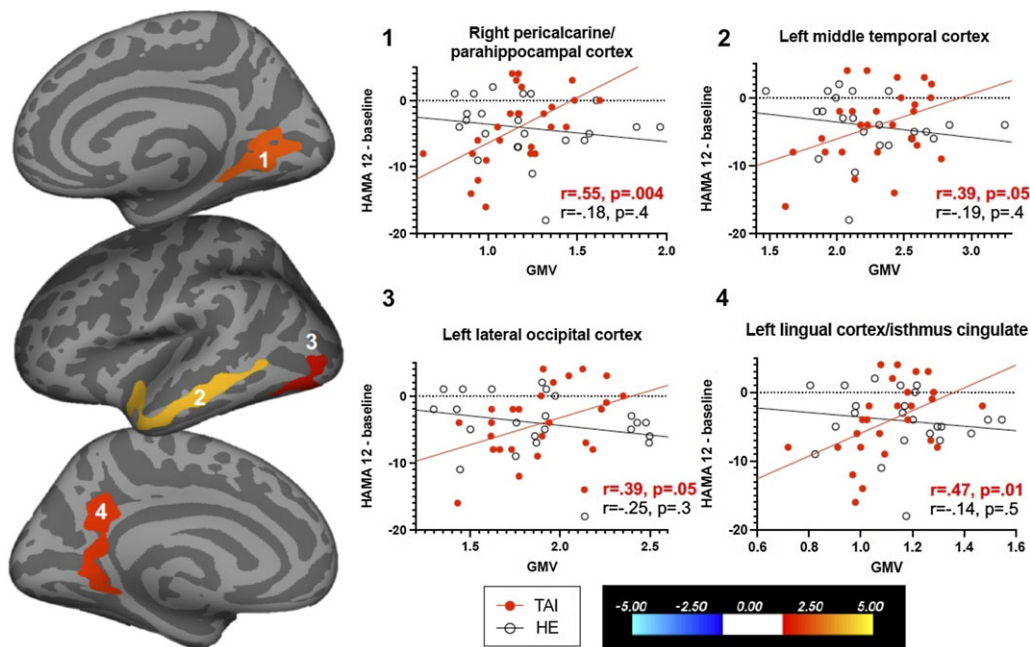


Figure 2. Group differences in the association between GMV and anxiety symptom change. Smaller baseline GMV was associated with larger anxiety reductions in the TCC group (panels 2 and 3 marginal) but not in the HEW group.

unclear, different levels of brain health and the ability to learn this rather complex technique might contribute to our observed findings. The regression models included the baseline test score as a covariate, therefore, the observed effects cannot be attributed to individual symptom severity.

Only a few studies reported correlations between GMV and depressive symptom severity in GD (Espinoza Oyarce *et al.*, 2020). Additionally, different studies use different mood measures, leading to potentially inconsistent findings. GD has been characterized by reduced cortical thickness in right supramarginal, inferior temporal, caudal and rostral middle frontal and medial superior frontal cortices, as well as left pars triangularis, superior parietal cortices and parts of the central sulcus (Mackin *et al.*, 2013). We previously found reduced bilateral orbitofrontal volume in GD compared to healthy controls, but no relationship between GMV and depressive symptom severity (Lavretsky *et al.*, 2007). Another study found that greater depressive symptom severity was associated with greater cortical thickness in the right isthmus cingulate in an ROI-based analysis, while a voxel-wise whole-brain analysis revealed an association between depression severity and the left precuneus (Szymkowicz *et al.*, 2016). Reduced thickness and volume have been found in a large network including the prefrontal cortex including orbitofrontal and anterior and posterior cingulate, the insula, several temporal and parietal regions, as well as subcortical regions (Kim and Han, 2021).

Lower GMV in several clusters was associated with greater improvements in anxiety. The left middle temporal cortex is reduced in GD and associated with episodic memory but not depressive symptom severity (Takamiya *et al.*, 2021). Similarly, we previously found left middle temporal GMV increases after 3 months of combined antidepressant and memantine treatment in GD compared to antidepressant treatment combined with a placebo (Krause-Sorio *et al.*, 2020). Lateral temporal and parahippocampal regions have also been found to be reduced in GD compared to healthy controls (Andreescu *et al.*, 2008). We recently found that greater anxiety was associated with lower GMV in left caudal middle frontal, postcentral and lingual cortices, as well as right superior frontal, pars opercularis and caudal middle frontal and right inferior to posterior parietal cortices in GD (Krause-Sorio *et al.*, under review). These regions do not overlap with our current findings. Since there was no group effect in anxiety improvement in the current study, the effect is likely due to differential indirect effects of the intervention on patients' anxiety levels. In an ROI-based study, we previously found correlations between GMV and anxiety scores in GD in the insula and orbitofrontal cortices (OFC), while depressive symptom severity correlated with insula GMV only (Laird *et al.*, 2019). Another ROI-based study in older adults with a history of depression found that greater trait anxiety was associated with reduced cortical thickness in the amygdala, ACC, insula, OFC and temporal cortices

(Potvin *et al.*, 2015). A recent meta-analysis in depression including adults across the age span found increased amygdala volume in a subgroup with comorbid anxiety, while the anxiety-free group showed reduced volume in the hippocampus, the globus pallidus, putamen and the thalamus (Espinoza Oyarce *et al.*, 2020). It is important to note, however, that studies demonstrating clusters from a group-based contrast often do not report or find correlations with related clinical scores.

In the parent clinical trial of this study involving 125 participants at the 3-month and 117 at the 6-month follow-up, we found that remission rates were similar between groups but the TCC group showed superior general health effects (Lavretsky *et al.*, 2022). Similarly, we previously found increased symptom improvement, remission rates, physical and cognitive functions, as well as a reduction in the inflammatory C-reactive protein in GD after 10 weeks of combined escitalopram and TCC treatment compared to an escitalopram and health education control (Lavretsky *et al.*, 2011). In a study comparing exercise with Tai Chi in older adults, both groups improved in dynamic balance, but Tai Chi showed superior performance in single-leg stance with eyes closed and fear of falling, as well as a within-group improvement in depressive symptom severity (Yıldırım *et al.*, 2016). Similarly, Tai Chi has been shown to improve balance and fear of falling, important modifiable risk factors of falls in older age (Carpenter *et al.*, 2014; Gazibara *et al.*, 2017). Additionally, a variety of previous Tai Chi studies found improvements in depression in younger adults with MDD (Yeung *et al.*, 2017).

Based on a recent model of the potential mechanisms of Tai Chi effects on MDD, Tai Chi is suggested to act as an anti-inflammatory treatment and modulates autonomic functioning and brain networks related to mood (Kong *et al.*, 2019). For example, mental control was improved after 12 weeks of Tai Chi compared to a health education control, and resting state functional connectivity was significantly reduced between the dorsolateral prefrontal cortex and the left superior frontal gyrus and the anterior cingulate cortex (Tao *et al.*, 2017).

While we found changes in resting state connectivity patterns (Kilpatrick *et al.*, 2022), GMV might not be sensitive enough to reflect the relatively short-term effects of TCC over 12 weeks, which may explain our failure to observe the group differences. Therefore, longer interventions may better be able to capture participants' natural gray matter decline over time, as well as potential increases in GMV. Even though TCC may have positive effects on mental wellbeing, the gentle movements may not lead to lasting training-related neural changes.

We recently found that yoga prevented GMV decline in older adults at an increased risk of Alzheimer's disease compared to the same type of health education control (Krause-Sorio *et al.*, 2022). Similar to the current study, participants underwent three months of weekly in-person lessons and additionally completed daily homework exercises in both conditions. TCC might be less physically taxing than our previous yoga training and may affect different physical and mental mechanisms. Furthermore, the current sample showed a relatively low range of depressive symptom severity, whilst on antidepressant medication. This combination may have led to weakened effects. It is also possible that both groups had unintended similar effects on clinical symptoms and brain structure, based on their similarities in social and mental engagement. We, therefore, believe that with the right intervention protocol and sample size, beneficial clinical and neural effects can be achieved in aging psychiatric populations.

The current study has several limitations. First, the sample size was relatively small; while the parent clinical trial included a much larger sample, this current sub-sample consisted of only 49 participants across both treatment groups. The reason was that many older adults did not qualify for MRI scanning due to implant safety criteria and claustrophobia. Additionally, the sample comprises well-educated individuals with limited racial diversity, consequently restricting the applicability of the findings to a broader population. It is also important to note that while we found associations between baseline GMV and intervention-related changes in anxiety scores, the patients in the current sample only experienced sub-clinical baseline levels of anxiety, therefore, the reduction in anxiety is not clinically significant. Second, due to the nature of the intervention, it was not possible to blind the experimenters to the intervention condition of each participant. Furthermore, while, cluster correction is applied, we did not correct for the three clinical outcomes and the results should therefore be interpreted with caution. Larger studies with more demographically diverse samples are necessary to further investigate the role of Tai Chi training.

The current study suggests that while changes in brain morphology may not be detected in older adults with depression undergoing antidepressant treatment after 3 months of TCC intervention, certain neuroanatomical regions may predict treatment outcomes in this population. Future studies should investigate structural and functional brain changes and prediction models using longer and more intensive Tai Chi interventions.

Conflict of interest

The authors report no conflicts with any product mentioned or concept discussed in this article.

Source of funding

Funding for this study was provided by the NIH grants AT 008383 AT009198 to Helen Lavretsky, MD. Additional support: National Center for Advancing Translational Science UCLA CTSI Grant Number UL1TR001881.

Description of authors' roles

HL is the PI of the study, KLN designed the neuroimaging component and advised on result interpretation, BKS and MMM acquired the data, LAK processed the imaging data, BKS analyzed the imaging data, PS analyzed the clinical data and PS and BKS wrote the manuscript. All authors provided critical input on the written manuscript and data interpretation.

Acknowledgments

We thank the University of California Brain Mapping Center and its technicians for their continued support.

References

- Alexopoulos, G. S.** (2019). Mechanisms and treatment of late-life depression. *Translational Psychiatry*, 9, 188.
- Andresescu, C. et al.** (2008). Gray matter changes in late life depression—a structural MRI analysis. *Neuropsychopharmacology*, 33, 2566–2572.
- Carpenter, C. R. et al.** (2014). Predicting geriatric falls following an episode of emergency department care: a systematic review. *Academic Emergency Medicine: Official Journal of the Society for Academic Emergency Medicine*, 21, 1069–1082.
- Chen, Y. M., Huang, X. M., Thompson, R., Zhao, Y.-B.** (2011). Clinical features and efficacy of escitalopram treatment for geriatric depression. *The Journal of International Medical Research*, 39, 1946–1953.
- Droppa, K. et al.** (2017). Association between change in brain gray matter volume, cognition, and depression severity: pre- and post- antidepressant pharmacotherapy for late-life depression. *Journal of Psychiatric Research*, 95, 129–134.
- Du, M. et al.** (2014). Brain grey matter volume alterations in late-life depression. *Journal of Psychiatry and Neuroscience*, 39, 397–406.
- Espinoza Oyarce, D. A., Shaw, M. E., Alateeq, K., Cherbuin, N.** (2020). Volumetric brain differences in clinical depression in association with anxiety: a systematic review with meta-analysis. *Journal of Psychiatry and Neuroscience*, 45, 406–429.
- Folstein, M. F., Folstein, S. E. and McHugh, P. R.** (1975). "Mini-mental state": a practical method for grading the cognitive state of patients for the clinician. *Journal of Psychiatric Research*, 12, 189–198.
- Gazibara, T. et al.** (2017). Falls, risk factors and fear of falling among persons older than 65 years of age. *Psychogeriatrics: The Official Journal of the Japanese Psychogeriatric Society*, 17, 215–223.
- Gunning, F. M. et al.** (2009). Anterior cingulate cortical volumes and treatment remission of geriatric depression. *International Journal of Geriatric Psychiatry*, 24, 829–836.
- Hamilton, M.** (1959). The assessment of anxiety states by rating. *British Journal of Medical Psychology*, 32, 50–55.
- Hamilton, M.** (1960). A rating scale for depression. *Journal of Neurology, Neurosurgery & Psychiatry*, 23, 56–62.
- Hamilton, M.** (1967). Development of a rating scale for primary depressive illness. *British Journal of Social and Clinical Psychology*, 6, 278–296.
- Hosseini, L., Kargozar, E., Sharifi, F., Negarandeh, R., Memari, A.-H., Navab, E.** (2018). Tai Chi Chuan can improve balance and reduce fear of falling in community dwelling older adults: a randomized control trial. *Journal of Exercise Rehabilitation*, 14, 1024–1031.
- Ismail, Z., Fischer, C. and McCall, W. V.** (2013). What characterizes late-life depression? *Psychiatric Clinics of North America*, 36, 483–496.
- Kilpatrick, L. A. et al.** (2022). Impact of Tai Chi as an adjunct treatment on brain connectivity in geriatric depression. *Journal of Affective Disorders*, 315, 1–6.
- Kim, Y. K. and Han, K. M.** (2021). Neural substrates for late-life depression: a selective review of structural neuroimaging studies. *Progress in Neuro-Psychopharmacology and Biological Psychiatry*, 104, 110010.
- Kong, J., Wilson, G., Park, J., Pereira, K., Walpole, C., Yeung, A.** (2019). Treating depression with Tai Chi: state of the art and future perspectives. *Frontiers in Psychiatry*, 10, 237–237.
- Krause-Sorio, B. et al.** (2019). Cortical thickness increases with levomilnacipran treatment in a pilot randomised double-blind placebo-controlled trial in late-life depression. *Psychogeriatrics: The Official Journal of the Japanese Psychogeriatric Society*, 20, 140–148.
- Krause-Sorio, B. et al.** (2020). Combined treatment with escitalopram and memantine increases gray matter volume and cortical thickness compared to escitalopram and placebo in a pilot study of geriatric depression. *Journal of Affective Disorders*, 274, 464–470.
- Krause-Sorio, B. et al.** (2022). Yoga prevents gray matter atrophy in women at risk for Alzheimer's disease: a randomized controlled trial. *J Alzheimers Dis*, 87, 569–581.
- Krause-Sorio, B. et al.** (2023). Regional gray matter volume correlates with anxiety, apathy and resilience in geriatric depression. *International Psychogeriatrics*, 29, 1–9.
- Laird, K. T. et al.** (2019). Anxiety symptoms are associated with smaller insular and orbitofrontal cortex volumes in late-life depression. *Journal of Affective Disorders*, 256, 282–287.

- Lavretsky, H. et al.** (2011). Complementary use of tai chi chih augments escitalopram treatment of geriatric depression: a randomized controlled trial. *The American Journal of Geriatric Psychiatry: Official Journal of the American Association for Geriatric Psychiatry*, 19, 839–850.
- Lavretsky, H. et al.** (2022). A randomized controlled trial of Tai Chi Chih or health education for geriatric depression. *The American Journal of Geriatric Psychiatry: Official Journal of the American Association for Geriatric Psychiatry*, 30, 392–403.
- Lavretsky, H., Ballmaier, M., Pham, D., Toga, A., Kumar, A.** (2007). Neuroanatomical characteristics of geriatric apathy and depression: a magnetic resonance imaging study. *The American Journal of Geriatric Psychiatry*, 15, 386–394.
- Lavretsky, H., Roybal, D. J., Ballmaier, M., Toga, A. W., Kumar, A.** (2005). Antidepressant exposure may protect against decrement in frontal gray matter volumes in geriatric depression. *The Journal of Clinical Psychiatry*, 66, 964–967.
- Mackin, R. S. et al.** (2013). Patterns of reduced cortical thickness in late-life depression and relationship to psychotherapeutic response. *The American Journal of Geriatric Psychiatry: Official Journal of the American Association for Geriatric Psychiatry*, 21, 794–802.
- Montgomery, G. K., Reynolds, N. C., Jr. and Warren, R. M.** (1985). Qualitative assessment of Parkinson's disease: study of reliability and data reduction with an abbreviated Columbia Scale. *Clinical Neuropharmacology*, 8, 83–92.
- Nelson, J. C., Delucchi, K. and Schneider, L. S.** (2008). Efficacy of second generation antidepressants in late-life depression: a meta-analysis of the evidence. *The American Journal of Geriatric Psychiatry*, 16, 558–567.
- Pimontel, M. A. et al.** (2020). Cortical thickness of the salience network and change in apathy following antidepressant treatment for late-life depression. *The American Journal of Geriatric Psychiatry: Official Journal of the American Association for Geriatric Psychiatry*, 29, 241–248.
- Potvin, O. et al.** (2015). Gray matter characteristics associated with trait anxiety in older adults are moderated by depression. *International Psychogeriatrics*, 27, 1813–1824.
- Ramachandran, V. S., Krause, B. and Case, L. K.** (2011). The phantom head. *Perception*, 40, 367–370.
- Reuter, M. and Fischl, B.** (2011). Avoiding asymmetry-induced bias in longitudinal image processing. *NeuroImage*, 57, 19–21.
- Reuter, M., Schmansky, N. J., Rosas, H. D., Fischl, B.** (2012). Within-subject template estimation for unbiased longitudinal image analysis. *NeuroImage*, 61, 1402–1418.
- Sexton, C. E., Mackay, C. E. and Ebmeier, K. P.** (2013). A systematic review and meta-analysis of magnetic resonance imaging studies in late-life depression. *The American Journal of Geriatric Psychiatry: Official Journal of the American Association for Geriatric Psychiatry*, 21, 184–195.
- Stone, J. F.** (1996). *Tai-Chi-Chih! Joy Through Movement*. Boston, MA: Good Karma Publishing.
- Szymkowicz, S. M. et al.** (2016). Depressive symptom severity is associated with increased cortical thickness in older adults. *International Journal of Geriatric Psychiatry*, 31, 325–333.
- Takamiya, A. et al.** (2021). Lower regional gray matter volume in the absence of higher cortical amyloid burden in late-life depression. *Scientific Reports*, 11, 15981.
- Tao, J. et al.** (2017). Tai Chi Chuan and Baduanjin practice modulates functional connectivity of the cognitive control network in older adults. *Scientific Reports*, 7, 41581.
- Tunvirachaisakul, C. et al.** (2018). Predictors of treatment outcome in depression in later life: a systematic review and meta-analysis. *Journal of Affective Disorders*, 227, 164–182.
- WHO** (2007). *WHO Global Report on Falls Prevention in Older Age*. France: WHO Library Cataloguing-in-Publication Data.
- Wilkinson, G. S. and Robertson, G. J.** (2006). *Wide Range Achievement Test Professional Manual, 4*. Bloomington, MN: NCS Pearson, Inc.
- Yeung, A. S. et al.** (2017). A pilot, randomized controlled study of Tai Chi with passive and active controls in the treatment of depressed Chinese Americans. *The Journal of Clinical Psychiatry*, 78, e522–e528.
- Yıldırım, P., Ofiuoglu, D., Aydogan, S., Akyuz, G.** (2016). Tai Chi vs. combined exercise prescription: a comparison of their effects on factors related to falls. *Journal of Back and Musculoskeletal Rehabilitation*, 29, 493–501.