

# Cerebellar Infarction — Review of Recent Experiences

W.B. WOODHURST

**SUMMARY:** *Six cases of acute cerebellar infarction seen on a neurosurgery service in a general hospital during a twenty-six month period are reviewed. The clinical presentation, course, and treatment are presented and discussed. This is an important clinical syndrome which requires a high level of clinical suspicion for detection. The diagnosis rests primarily upon the clinical signs and symptoms. The C.T. Scan may provide useful confirmatory evidence and clarifies the differential diagnosis. Surgical treatment by resection of the infarcted tissue — mass lesion is urgently required for those patients who deteriorate progressively.*

**RÉSUMÉ:** *Nous rapportons six cas d'infarctus cérébelleux aigu vus dans le service de neurochirurgie d'un grand hôpital général au cours d'une période de 26 mois. Nous présentons et discutons l'aspect clinique, l'évolution et le traitement de cette entité. Il s'agit d'un syndrome clinique important qui implique pour sa détection un haut niveau de sens clinique. Ce diagnostic se base presque entièrement sur les signes et symptômes. La tomodynamométrie permet d'obtenir des évidences complémentaires et de préciser le diagnostic différentiel. Lorsque les patients se détériorent progressivement il est nécessaire d'intervenir d'urgence par la résection chirurgicale de la masse tissulaire infarctée.*

## INTRODUCTION:

The purpose of this paper is to review our recent experiences with this cerebellar vascular disorder, evaluating the clinical and radiographic features, and surgical results, with a view to improving diagnostic accuracy and the treatment of this serious problem. Comparison and reference is made to other similar and related clinical and pathologic studies.

Cerebellar infarction has been clinically emphasized only in the relatively recent medical literature. The first report by Germain and Morvan (1938) has gone relatively unnoticed by most authors. They reported in detail the course of a thirty-two year old man who died from a right cerebellar infarction. In 1956 two more papers appeared, one by Fairburn and Oliver and the other by Lindgren, reporting a total of five cases of cerebellar infarction presenting as posterior fossa mass lesions. Since then, a steady reporting of small series from centers in the United States (Wood, 1969; Lehigh, 1970; Momose, 1973; Duncan, 1975; Ferguson, 1976; Gwang, 1977; Arnow, 1978; Feely, 1979), Canada (Norris, 1969), France (George, 1978; Geraud, 1978), Belgium (DeRueck, 1978), Russia (Nikonova, 1977; Levina, 1978; Vereshchagen, 1978; Nakhapeton, 1979), Japan (Ivamoto, 1974; Miki, 1978), have indicated a widespread distribution and a low, but not rare incidence.

From these reports and reviews recognition of a typical clinical syndrome arises. This syndrome consists of acute onset of vertigo, headache, nausea or vomiting, ataxia-disequilibrium, then progressing signs of brain stem compression with gaze palsy,

cranial nerve palsies and a decreasing level of consciousness. Most of the reported patients have deteriorated from the effects of the posterior fossa mass lesion, but in a few spontaneous recovery has occurred. (Duncan, 1975; Feely, 1979).

The disease is usually seen in older hypertensive patients with other evidence of cerebrovascular disease or factors predisposing to it. The syndrome has also been reported in infants (Fischer, 1972; Momose, 1973), in a patient with congenital heart disease (Mosose, 1973), with sickle cell disease (Arnow, 1978) and following angiography (Ferguson, 1976).

All authors have stressed that this clinical syndrome, seemingly innocent at onset, may progress to fatal brain stem compression. Decompression by resection of the infarcted cerebellar tissue, with or without CSF drainage for relief of hydrocephalus, has been the only consistently successful therapy.

The pathologic features of cerebellar infarction were reviewed by Sybert and Alvord in 1975. Their report involved autopsy and retrospective clinical study of twenty-eight cases of acute uncomplicated massive cerebellar infarction. These authors stressed that the infarcts predominantly involve the postero-inferior half of one cerebellar hemisphere. The most common arterial territory affected was the left posterior inferior cerebellar artery (PICA) followed by the right PICA. Much less common were infarcts in superior locations or bilateral posterior or superior locations. The most common arterial occlusion was the left vertebral. A consistent pathologic finding was moulding, with compression of the medulla present in all cases and judged to be the cause of death in these patients. The clinical profiles of the patients in this autopsy series are similar to those in the surgical series.

From the Vancouver General Hospital.

Reprint requests to: Dr. W.B. Woodhurst, Vancouver General Hospital, 855 West 12th Avenue, Vancouver, B.C., Canada V5Z 1M9.

## MATERIAL:

Six patients with this diagnosis were seen by the Division of Neurosurgery at the Vancouver General Hospital over a twenty-six month period, January 1977 to February 1979. During this period there were 2,255 discharges from the adult neurosurgery service. There was only one case of cerebellar hemorrhage seen during the same interval. The average age of the patients with cerebellar infarction was 59 years, ranging from 43 to 69. There were four males and two females.

## ASSOCIATED DISEASE:

Predisposing factors for cerebrovascular disease included hypertension and atrial fibrillation in one case and diabetes mellitus in one case.

## SIGNS AND SYMPTOMS

Initial or early symptoms included: ataxia of gait or limbs (or both) in six patients, vertigo in five, nausea and vomiting in four, headache in three, dysarthria in three and fever and diaphoresis in two.

Early neurologic assessments (less than twenty-four hours after onset of symptoms) were performed in three patients. Limb ataxia was noted in three, truncal ataxia in two, gaze paresis in one, nystagmus in one and skew deviation in one.

The course of the symptoms and signs varied. Two patients had a smooth improvement from initial deficit with no specific therapy. Four patients deteriorated: three of these became unconscious, two between 48 and 72 hours from the onset of symptoms, and one after a longer interval.

Neurologic findings of the deteriorated patients preoperatively were varied. There were three unconscious and one stuporous patient. All demonstrated gaze palsy of some form. One patient (stuporous) demonstrated marked limb ataxia. One patient demonstrated a hemiparesis, one showed decorticate posturing and one had flaccid limbs. All four patients had bilateral extensor plantar responses. Three patients had inspiratory stridor and one had deteriorated to the point of apnea.

## RADIOLOGIC FINDINGS

C.T. Scans were obtained on all patients. Only one scan was obtained less than twenty-four hours from the onset of symptoms. It was normal, but a repeat scan at five days showed low density changes in the left cerebellar hemisphere, (Fig. 1a and 1b). Later scans were obtained in all six cases. Three of these demonstrated low density changes in the cerebellum often difficult to judge with certainty. Two cases showed mixed density changes (Fig. 2a and 2b) and one was equivocal. Hydrocephalus of some degree was present in five of six cases.

Problems encountered in C.T. Scanning were primarily bone and motion artifact. These marred four scans and unfortunately these were the four deteriorating patients.

Two patients underwent vertebral angiography and this was normal in both cases.

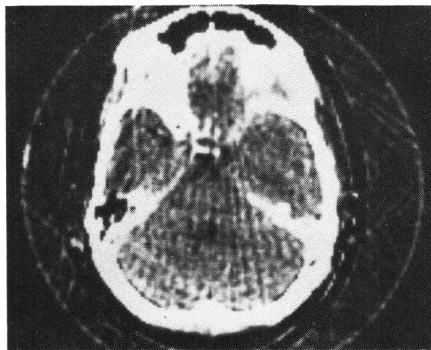


Figure 1(a) — C.T. Scan obtained 2-3 hours after onset of acute headache, tinnitus, vertigo, nausea and vomiting and ataxia in a 43-year old diabetic man. No abnormality demonstrated.

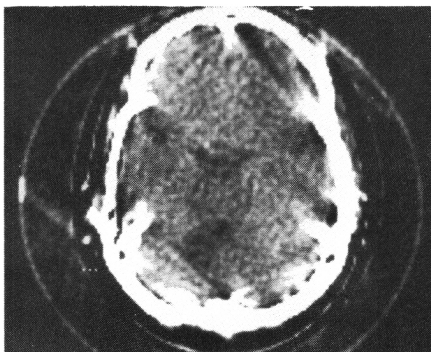


Figure 1(b) — C.T. Scan obtained 5 days later (same patient) showing low density changes in the left cerebellar hemisphere. The patient improved gradually without specific therapy.

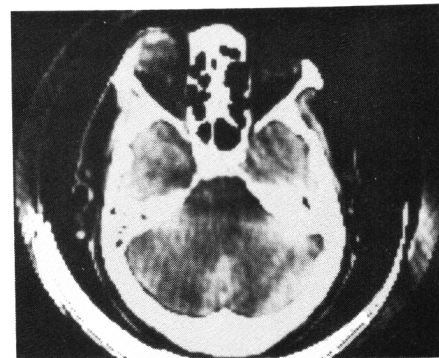

Figure 2(a) — C.T. Scan obtained 5 days after onset of progressive vertigo, ataxia, nausea, headaches and dysarthria and dysphagia in a 67-year old man. It shows mixed high and low density lesion in cerebellum. At operation, this hemorrhagic infarct involved the left inferior-posterior cerebellar hemisphere which was a sizable mass of swollen hemorrhagic tissue displacing the brain-stem and right cerebellar hemisphere.

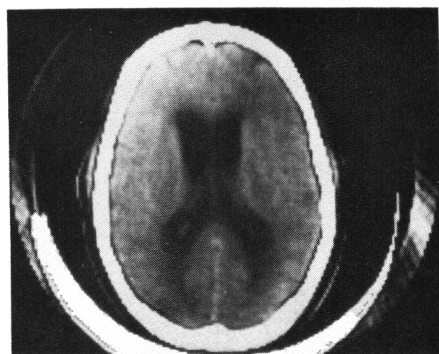


Figure 2(b) — C.T. Scan demonstrating moderate ventricular enlargement in same patient.

## LOCATION AND NATURE OF INFARCTS

All cases had the infarction in the left cerebellar hemisphere. At surgical exploration (four cases), the distribution of the infarct was posterior-inferior medial cerebellar hemisphere. One of these (Case 6) was confirmed by autopsy. Of the surgical cases three infarcts were partially hemorrhagic. The two nonsurgical cases also involved the left cerebellar hemisphere primarily posteriorly. One was hemorrhagic.

## TREATMENT

Operative procedures were performed in four cases. All of the four deteriorating patients underwent posterior fossa craniotomy and resection of infarcted cerebellar tissue. This was performed

with the patient in the sitting position in two cases and in the prone position in two cases. Two cases also underwent CSF diversion — one by external ventriculostomy and one by ventriculo-peritoneal shunt.

#### OUTCOME

Two cases made a good recovery without specific therapy. Two cases made a good recovery after surgery and were left with mild residual signs and mild functional deficits.

The two deaths illustrate the problems encountered. Case 1 deteriorated to a state of flaccid quadraparesis, unconsciousness and apnea prior to his operation. He failed to improve and died on the third post-operative day.

Case 6 was first seen when unconscious and demonstrated decorticate posturing. He failed to improve after external ventriculostomy and craniotomy and resection of infarcted left inferior cerebellum. He developed pneumonia, septicemia, and meningitis, and died twenty-seven days later. Autopsy disclosed the infarction in the distribution of the left posterior-inferior cerebellar artery had enlarged. Septic micro-infarcts were found in the brain stem. The primary etiology of the cerebellar infarct remained unclear as there was no evidence of hypertensive vascular disease, minimal arteriosclerosis and no source of embolus.

#### DISCUSSION

These six patients, seen at various stages of evolution of their illness, represent only a part of the spectrum of cerebellar infarction. Those patients with pure vertiginous disequilibrium or massive brain stem cerebellar infarction are rarely seen in neurosurgical consultation. It is, however, this "middle group" of patients represented here, who present with initially relatively mild or innocent-appearing symptoms and signs who are at risk from an expanding subacute posterior fossa mass lesion. The incidence of this disorder remains unclear. On our service it is not rare (6/2,255 discharges in twenty-six months). The natural history is also not certain. It is clear that a substantial proportion of patients will deteriorate.

The diagnosis rests primarily on the

clinical features of history and examination. Our patients and those in most other reported series complained of acute vertigo and imbalance, often with headache at the onset. They demonstrated signs of cerebellar dysfunction if examined early. If seen late, the signs were those of an expanding mass in the posterior fossa with depressed level of consciousness, cerebellar, brainstem, and cranial nerve deficits. Deteriorating level of consciousness was an ominous prognostic sign.

The C.T. Scan provided valuable additional information and clarified the differential diagnosis.

The treatment of patients, who deteriorate from the effects of the mass lesion, is resection of the infarcted tissue. Hydrocephalus, occurring acutely or later, may require ventriculo-peritoneal shunting for relief. Delay in recognition and treatment was common in this series and may prove fatal. A high index of suspicion for this disorder and improvements in clinical and radiographic examination of these patients should lead to improved results of treatment.

#### ACKNOWLEDGEMENTS

The author thanks the attending neurosurgeons and neurologists of the Vancouver General Hospital for permission to include their cases in this report.

The assistance of Dr. G.B. Thompson in the preparation of the manuscript and the secretarial assistance of Mrs. E. Sleath are gratefully acknowledged.

#### REFERENCES

- ARNOW, P.M., PANWALKER, A., GARVIN, J.S. and RODRIGUEZ-ERDMANN, F. (1978). Aspirin, Hyperventilation, and Cerebellar infarction in sickle cell disease. *Arch. Intern. Med.* 138: 148-149.
- DeRUECK, J., VAN DER EECKEN, H. (1978). Cerebellar Infarction and Internal Hydrocephalus. *ACTA Neurol. Belg.* 78: 129-140.
- DUNCAN, G.W., PARKER, S.W., and FISHER, M. (1975). Acute Cerebellar Infarction in the Pica Territory. *Arch. Neurol.* 32: 364-368.
- FAIRBURN, B. and OLIVER, L.C. (1956). Cerebellar Softening, a Surgical Emergency. *B.M.J.* 1956: 1335-6.
- FEELY, M.P. (1979). Cerebellar Infarction. *Neurosurgery* 4: 7-11.
- FERGUSON, L., SUNDARESAN, N., RICHARDSON, R., and MARSAN, R. (1976). Acute Hemorrhagic Cerebellar Infarction following Angiography. *Surg. Neurol.* 5: 176-178.
- FISHER, E.G., STRAND, R.D., GILLES, F.H. (1972). Cerebellar Necrosis Simulating Tumor in Infancy. *J. Paediat.* 81: 98-100.
- GEORGE, B., COPHIGNON, J., GEORGE, C. and LOUGHON, J. (1978). Aspect Chirurgical des Ramollissements Cerebelleux. *Neurochirurgie* 24: 83-88.
- GERAUD, G., GUILLAME, J., LAGARRIQUE, J., LAZORTHES, Y., BÈS, A., and GERAUD, J. (1978). Les Ramollissements Pseudo-tumoraux du Cervelet. *Rev. Neurol.* (Paris) 3-134: 183-195.
- GERMAIN, A., MORVAN, A. (1938). Ramollement Cerebelleux Pseudotumoral. *Annales de Medicine Interne Paris* (Bull. Soc. Med. Hosp. Paris) 44: 1695-1700.
- GUIANG, R.L., Jr., and ELLINGTON, O.B. (1977). Acute Pure Vestibular Disequilibrium in Cerebellar Infarction. *Eur. Neurol.* 16: 11-15.
- IVAMOTO, H.S., NUMOTO, M., DONAGHY, P. (1974). Surgical Decompression for Cerebral and Cerebellar Infarcts. *Stroke* 5: 365-370.
- LeBEAU, J., CORCOS, A. (1976). Sur un Nouveau Cas de Ramollissement Cerebelleux Pseudotumoral. *Sem. Hop. (Paris)* 52: 637-640.
- LEHRICH, J.R., WINKLER, G.F. and OJEMANN, R.G. (1970). Cerebellar Infarction with Brain Stem Compression. *Arch. Neurol.* 22: 490-498.
- LEVINA, G.Y. (1978). Cerebellum Infarction in Hypertensive Cases. *Arkiv Patologii* 40: 68-70.
- LINDGREN, S.O. (1956). Infarctions Simulating Brain Tumors in the Posterior Fossa. *J. Neurosurgery* 13: 575-581.
- MIKI, K., KURIMOTO, T., TANI, S., IKEDA, Y., KAWAMURA, Y., SOMEDA, K., MATSUMURA, H. (1978). On the Surgical Treatment of Cerebellar Infarction. *No Shinkei Geka* 6(7) 707-13.
- MOMOSE, K.J. and LEHRICH, J.R. (1973). Acute Cerebellar Infarction Presenting as a Posterior Fossa Mass. *Radiology* 109: 343-352.
- NAKHAPETOU, B.A. (1974). On the Symptomatology of Acute Circulatory Disturbances in the Cerebellum. *Vrachibioe Delo.* 1 Jan. 1974: 39-41.
- NIKONOVA, O.S. (1977). Thrombotic Lesions of the Superior and Inferior Posterior Cerebellar Arteries. *Z.H. Neuropatol Psikhiatr* 77: 1326-1329.
- NORRIS, J.W., EISEN, A.A. and BRANCH, C.L. (1969). Problems in Cerebellar Hemorrhage and Infarction. *Neurology* 19: 1043-1050.
- SYPERT, G.W. and ALVORD, E.C. (1975). Cerebellar Infarction — A Clinicopathologic Study. *Arch. Neurol.* 32: 357-363.
- VERESHCHAGIN, N.W., CHEBOTAREVA, N.M., KALASHNIKOVA, L.A. (1978). Cerebellar Infarct — Clinical Picture, Diagnosis and Treatment. *ZH Neuropatol Psikhiatr.* 78 (11) 1609-14.
- WOOD, M.W. and MURPHY, F. (1969). Obstructive Hydrocephalus due to Infarction of a Cerebellar Hemisphere. *J. Neurosurgery* 30: 260-263.