

DIAGNOSTIC CHALLENGE

The vanishing lung

Naveed Nazir Shah, MD; Rakesh Bhargava, MD; Zuber Ahmed, MD; Deepak Kumar Pandey, MD; Mohd Shameem, MD; Arshad Altaf Bachh, MD; Khurshid Ahmad Dar, MD

Case history

A 35-year-old man presented to the emergency department (ED) with a 3-month history of increasing shortness of breath associated with reduced exercise tolerance. The patient was a smoker with more than 20 pack-years of tobacco use. He had no history of fever, night sweats, cough, hemoptysis or chest pain, and his medical history was unremarkable.

Physical examination revealed a well-looking man who was alert, stable and in no respiratory distress. Vital signs were blood pressure 122/74 mm Hg, pulse 92 beats/min, respiratory rate 22 breaths/min, temperature 35.8°C and oxygen saturation 97% on room air. The patient had no pallor, cyanosis, diaphoresis, clubbing or peripheral edema. His jugular veins were not distended; however, his trachea was shifted to the right and breath sounds were diminished over the left hemithorax without dullness to percussion. The patient's heart sounds were maximally audible over the right hemithorax.

An electrocardiogram revealed normal sinus rhythm and right axis deviation without evidence of ischemia. Pulmonary function tests were consistent with an obstructive pattern (forced expiratory volume in 1 second [FEV₁] = 1.71 L; 45% predicted). A posterior–anterior chest x-ray is shown in Figure 1.

Question

The most likely diagnosis is:

- a) bullous emphysema;
- b) tension pneumothorax;
- c) spontaneous pneumothorax; or
- d) right-sided pneumonia?

For the Answer to this Challenge, see page 233.

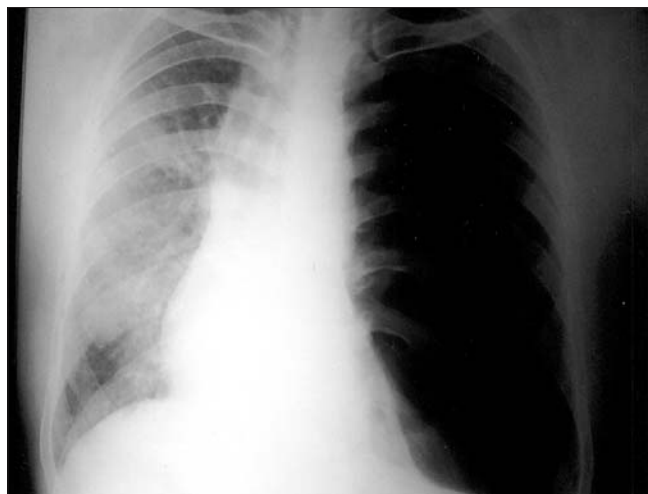


Fig. 1. Posterior–anterior chest x-ray.

From the Department of Tuberculosis and Chest Diseases, Jawaharlal Nehru Medical College, Aligarh Muslim University, Aligarh, Uttar Pradesh, India

Received: Mar. 6, 2007; accepted: Mar. 8, 2007

This article has not been peer reviewed.

Can J Emerg Med 2007;9(3):170