

# Iatrogenic radial neck fracture on closed reduction of elbow dislocation

Prasad Ellanti, MRCS\*; Dermot O'Farrell, FRCS Tr &Orth\*

## ABSTRACT

Traumatic dislocation of the elbow is rare in children and can most often be managed in the emergency department using procedural sedation and closed reduction with good functional outcome. Radiographs must be evaluated for associated avulsions and fractures around the elbow. We present the case of a 14-year-old girl who sustained a fracture of the radial neck subsequent to repeated attempts at closed reduction of a pure posterior elbow dislocation that was missed on postreduction radiographs. Careful use of reduction techniques and avoidance of repeated forceful manipulations is emphasized.

## RÉSUMÉ

La dislocation traumatique du coude est rare chez les enfants; dans la plupart des cas, elle peut se traiter au service des urgences sous sédation interventionnelle, par réduction fermée, et la réparation donne de bons résultats fonctionnels. Toutefois la recherche d'avulsions et de fractures possibles autour du coude, sur les radiographies, s'impose. Il sera question ici du cas d'une jeune fille de 14 ans, qui a subi une fracture du col du radius, à la suite de tentatives répétées de réduction fermée d'une simple dislocation postérieure du coude, qui est passée inaperçue sur les radiographies après l'intervention. Aussi insisterons-nous sur l'application méticuleuse des techniques de réduction et sur le fait d'éviter les manipulations énergiques répétées.

**Keywords:** closed reduction, elbow dislocation, iatrogenic, radial neck fracture

Traumatic dislocation of the elbow is rare in children, with an incidence of 3 to 6%.<sup>1</sup> Pure dislocation is uncommon, and radiographs must be evaluated for associated avulsions and fractures around the elbow.<sup>1</sup> Pure dislocations can most often be managed in the

emergency department (ED), with good functional outcome, using procedural sedation and closed reduction.<sup>2</sup> We present the case of a 14-year-old girl who sustained a fracture of the radial neck on closed reduction of a pure posterior elbow dislocation.

## CASE REPORT

A 14-year-old girl presented to the ED at a peripheral hospital with significant pain and swelling to the left elbow following a fall on her outstretched hand. This was a closed injury, and there were no neurovascular deficits. Plain film radiographs confirmed the clinical suspicion of posterior elbow dislocation (Figure 1). Apparent clinical reduction was attained on the third attempt to reduce the elbow using the Parvin method<sup>3</sup> under procedural sedation by an ED physician. Plain film radiographs, however, revealed a fracture of the radial neck with posterior displacement and 90° rotation (Figure 2) that was not diagnosed at this time by the treating ED physician.

The patient presented to the orthopedic outpatient department 10 days postinjury when the fracture was diagnosed. The radiology reports from the referring institution confirmed our diagnosis. Failed closed reduction under a general anesthetic necessitated open reduction and fixation with K-wire. The elbow was immobilized for 4 weeks in an above-elbow backslab and commenced on range of motion exercises subsequently after removal of K-wires at this time (Figure 3). A full and pain-free range of motion at the elbow was restored at 3 months postoperatively without any residual instability. She remains symptom free at 1 year postinjury.

From the \*Department of Trauma and Orthopaedic Surgery, Mid-Western Regional Hospital, Dooradoyle, Limerick, Ireland.

**Correspondence to:** Mr. P. Ellanti, Department of Trauma and Orthopaedic Surgery, Mid-Western Regional Hospital, Dooradoyle, Limerick, Ireland; prasad.ellanti@gmail.com.

This article has been peer reviewed.

© Canadian Association of Emergency Physicians

CJEM 2013;15(6):389-391

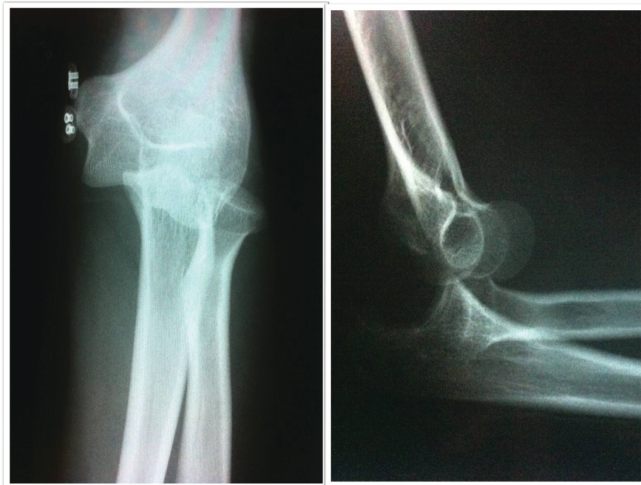DOI 10.2310/8000.2013.130920

DECKER



CJEM • JCMU

2013;15(6) 389

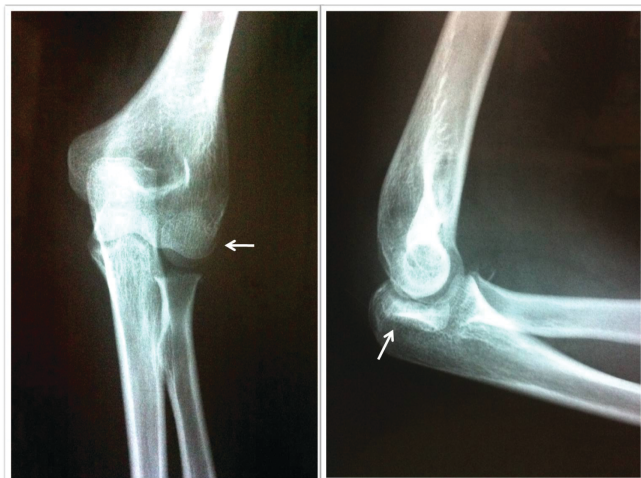


**Figure 1.** Anteroposterior and lateral radiographs demonstrating posterior elbow dislocation.

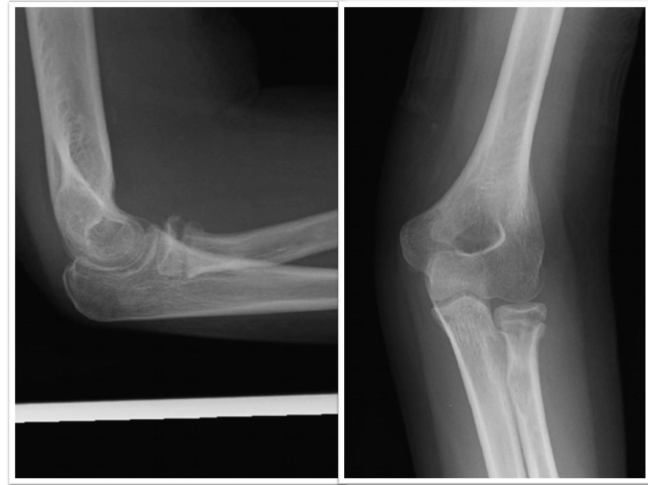**DISCUSSION**

Approximately 90% of elbow dislocations are posterior or posterolateral dislocations.<sup>4</sup> Pure dislocations are uncommon. The most commonly associated fracture is avulsion of the medial epicondyle.<sup>5</sup> Radial neck fractures in association with elbow dislocations are well described.<sup>6</sup> There are few reports, however, describing an iatrogenic cause of radial neck fractures in children.<sup>7</sup>

Jeffery described two mechanisms for fracture of the radial neck in children.<sup>8</sup> In the more common first type, displacement is due to a fall on the outstretched hand, and the capitellum is driven against the outer aspect of the radial head, causing a fracture. This valgus force also results in a traction lesion on the



**Figure 2.** Postreduction views of the elbow demonstrating a radial neck fracture with 90° rotation (white arrows).



**Figure 3.** Radiographs of the elbow at 6 weeks from open reduction.

medial aspect of the joint, often in the form of an avulsed medial epicondyle. The uncommon second type results from a temporary posterior subluxation or dislocation of the elbow joint. The radius neck is fractured at the time of spontaneous reduction when the radius impacts against the posterior aspect of the capitellum. The mechanism of injury in our patient is similar to that of the second type described by Jeffery.

In the skeletally immature child, the relatively cartilaginous radial head is resistant to fracture. In 90% of cases, the fracture involves the physis or the radial neck.<sup>9</sup> The radial head has been shown to ossify between 11.5 and 14 years in females and between 13.5 and 16 years in males.<sup>10</sup> The proximal radial epiphysis had fully ossified in our patient.

Outcomes are better for cases managed with closed reduction than those managed with open reduction. Injuries necessitating open reduction and fixation tend to be more severe, and in one series, poor outcomes were noted in 50% of such cases, primarily as a result of avascular necrosis, radial head enlargement, and periarticular ossification.<sup>11</sup> Closed reduction in the presence of a radial neck fracture can result in an iatrogenic malposition of the radial head. Navali and Sadigi reported a 180° rotational malposition of the radial head where the articular surface was at the fracture site. Despite union of the fracture following surgical correction, the patient went on to develop avascular necrosis.<sup>12</sup>

This case is interesting as the initial radiographs demonstrate a pure elbow dislocation, which is uncommon, and the subsequent postreduction radiographs demonstrate a radial neck fracture. This was

likely from repeated forceful attempts at reduction. The case highlights the importance of careful evaluation of pre- and postreduction radiographs. Several closed reduction methods have been described, and regardless of the technique used, the mediolateral displacement needs to be addressed prior to the anteroposterior displacement.<sup>13</sup>

### **CONCLUSION**

Careful evaluation of pre- and postreduction radiographs, careful use of reduction techniques, and avoidance of repeated forceful manipulations are emphasized to avoid this complication.

**Competing interests:** None declared.

### **REFERENCES**

1. Wilkins KE. Fractures and dislocations of the elbow region. In: Rockwood CA, Wilkins KE, King RE, editors. *Fractures in children*. 4th ed. Vol 3. Philadelphia: Lippincott-Raven, 1996. p. 653-887.
2. Lansinger O, Karlsson J, Körner L, et al. Dislocation of the elbow joint. *Arch Orthop Trauma Surg* 1984;102:183-6, doi:10.1007/BF00575230.
3. Parvin RW. Closed reduction of common shoulder and elbow dislocations without anesthesia. *AMA Arch Surg* 1957; 75:972-5, doi:10.1001/archsurg.1957.01280180104014.
4. Cohen MS, Hastings H II. Acute elbow dislocation: evaluation and management. *J Am Acad Orthop Surg* 1998; 6:15-23.
5. Fowles JV, Slimane N, Kassab MT. Elbow dislocation with avulsion of the medial humeral epicondyle. *J Bone Joint Surg Br* 1990;72-B:102-4.
6. Broberg MA, Morrey BF. Results of treatment of fracture dislocations of the elbow. *Clin Orthop* 1987;216:109-19.
7. Ward WT, Williams JJ. Radial neck fracture complicating closed reduction of a posterior elbow dislocation in a child: case report. *J Trauma* 1991;31:1686-8, doi:10.1097/00005373-199112000-00020.
8. Jeffery CC. Fractures of the neck of the radius in children. Mechanism of causation. *J Bone Joint Surg Br* 1972;54:717-9.
9. Henrikson B. Isolated fractures of the proximal end of the radius in children: epidemiology, treatment and prognosis. *Acta Orthop Scand* 1969;40:246-60, doi:10.3109/17453676908989505.
10. Brodeur AE, Silberstein JJ, Graviss ER. *Radiology of the pediatric elbow*. Boston: GK Hall; 1981.
11. Steinberg EL, Golomb D, Salama R, et al. Radial head and neck fractures in children. *J Pediatr Orthop* 1988;8:35-40, doi:10.1097/01241398-198801000-00009.
12. Navali AM, Sadigi A. Displaced fracture of the neck of the radius with complete 180 degrees rotation of the radial head during closed reduction. *J Hand Surg [Br]* 2006;31:689-91, doi:10.1016/j.jhsb.2006.04.020.
13. Sheps DM, Hildebrand KA, Boorman RS. Simple dislocations of the elbow: evaluation and treatment. *Hand Clin* 2004;20:389-404, doi:10.1016/j.hcl.2004.07.002.