

# Bedside ultrasonography detects significant femoral vessel overlap: implications for central venous cannulation

Francesca L. Beaudoin, MD, MS\*; Roland C. Merchant, MD, MPH, ScD\*; James Lincoln, BS\*; Fenwick Gardiner, BS\*; Otto Liebmann, MD\*; Jamieson Cohn, MD\*

## ABSTRACT

**Objective:** Our goal was to gain a better understanding of the femoral vessel anatomy as it relates to central venous cannulation. The primary objective of this study was to use bedside ultrasonography to determine the amount of exposed femoral vein at three sites corresponding to surface anatomy of the landmark-based procedure.

**Methods:** This cross-sectional study enrolled a random sample of 180 adult patients presenting to a large urban academic emergency department. Subjects underwent standardized ultrasonography to identify and measure the depth and diameter of the femoral vessels and amount of exposed femoral vein at the level of the inguinal ligament (0 cm) 2 cm and 4 cm below. Repeated measures analysis of variance was used to determine significant relationships between vessel measurements and distance from the inguinal ligament.

**Results:** The median age was 44.5 (range 19–90) years; 101 patients were male. The mean ( $\pm$  SD) percentage of exposed vein at the inguinal ligament was 83% ( $\pm$  21). This decreased significantly ( $p < 0.01$ ) with increasing distance from the inguinal ligament: 65% ( $\pm$  25) at 2 cm and 56% ( $\pm$  30) at 4 cm. At every distance away from the inguinal ligament, there were some subjects with no vein exposed.

**Conclusion:** This study demonstrates significant overlap of the femoral vessels at sites where landmark-based femoral vein cannulation is often attempted. Our results suggest that ultrasound guidance would be beneficial as femoral vein cannulation may be difficult or impossible in certain individuals owing to anatomic variations.

## RÉSUMÉ

**Objectif:** Notre objectif était d'acquiescer une meilleure compréhension de l'anatomie des vaisseaux fémoraux en ce qui

concerne la canulation veineuse centrale. L'objectif principal de cette étude était d'utiliser l'échographie au chevet pour déterminer la portion de la veine fémorale exposée à trois points correspondant à l'anatomie de surface en utilisant la technique des points de repères.

**Méthodes:** Dans le cadre de cette étude transversale, un échantillon aléatoire, composé de 180 adultes qui se sont présentés au service d'urgence d'un grand centre universitaire en milieu urbain, a été utilisé. Les sujets ont subi une échographie standardisée pour détecter et mesurer la profondeur et le diamètre des vaisseaux fémoraux et la portion de veine fémorale exposée au niveau du ligament inguinal (à 0 cm), à 2 cm et à 4 cm en-dessous. Une analyse de variance à mesures répétées a été effectuée pour déterminer les relations significatives entre les mesures des vaisseaux et la distance entre la veine et le ligament inguinal.

**Résultats:** L'âge médian était de 44,5 ans (fourchette de 19 à 90 ans); 101 patients étaient de sexe masculin. La moyenne ( $\pm$   $\sigma$ ) en pourcentage de la veine exposée au ligament inguinal était de 83 % ( $\pm$  21). Cela diminuait de façon significative ( $p < 0,01$ ) avec l'augmentation de la distance la séparant du ligament inguinal : de 65 % ( $\pm$  25) à 2 cm et de 56 % ( $\pm$  30) à 4 cm. À chaque point distant du ligament inguinal, il y avait des sujets dont la veine n'était pas exposée.

**Conclusion:** Cette étude démontre un chevauchement important des vaisseaux fémoraux aux points où la canulation veineuse fémorale à l'aide des points de repère est souvent tentée. Nos résultats suggèrent que l'échoguidage serait bénéfique compte tenu que la canulation veineuse fémorale peut être difficile, voire impossible, à effectuer chez certains individus en raison des variations anatomiques.

**Keywords:** central venous access, femoral artery, femoral vein, ultrasonography

From the \*Department of Emergency Medicine, Rhode Island Hospital, Warren Alpert Medical School of Brown University, Providence, RI.

Poster presentation at the Society for Academic Emergency Medicine National Meeting, New Orleans, LA, May 2009.

**Correspondence to:** Dr. Francesca L. Beaudoin, Department of Emergency Medicine, Rhode Island Hospital, 593 Eddy Street, Claverick 2, Providence, RI 02903; Francesca\_beaudoin@brown.edu.

Submitted September 14, 2010; Revised January 20, 2011; Accepted March 4, 2011.

© Canadian Association of Emergency Physicians

CJEM 2011;13(4):245-250

DOI 10.2310/8000.2011.110482

Central cannulation of the femoral vein is often attempted using a landmark-based technique. Despite a growing trend toward the use of ultrasonography for procedural guidance, bedside ultrasonography is still available only in less than a third of community emergency departments (EDs) in the United States.<sup>1,2</sup> Classic teaching of central venous cannulation in emergency medicine textbooks advises that the introducer needle should enter the skin 2 cm below the inguinal ligament and 1 cm medial to the femoral artery pulse.<sup>3,4</sup> Despite these widely referenced landmarks, information about the femoral vessel anatomy as it corresponds to this procedure is lacking.

Intuitively, factors that are important when attempting central venous cannulation are vein depth and diameter and the amount of vein that is overlapped by the artery. Previous vascular studies have attempted to characterize these variables, with specific attention to the concept of overlap.<sup>5–8</sup> These investigations have provided limited quantitative information about the amount of overlap, however, and did not examine the amount of exposed vein. The amount of exposed femoral vein is arguably the most important factor in determining the success of central venous access. Nevertheless, no study has examined the amount of exposed femoral vein as it corresponds to the surface landmarks that are used for the landmark-based technique.

There is also no evidence to suggest that the right or left femoral vein should be favoured for attempts to central venous cannulation; however, it has been reported that practitioners will choose the right nearly two-thirds of the time.<sup>9</sup> Additionally, external rotation and abduction of the hip, also called the “frog-leg” position, are often employed. Once again, there is inadequate evidence to support the frog-leg maneuver. Although a recent pediatric study concluded that placing patients in this position did not decrease that amount of overlap, a small study of 25 adults concluded that there was improvement with this position.<sup>10,11</sup>

Reported failure of femoral vein cannulation ranges from 15 to 37%.<sup>12,13</sup> In addition, arterial puncture complicates 10 to 15% of attempts and can result in arteriovenous fistula, hemorrhage, hematoma formation, and pseudoaneurysms.<sup>12–14</sup> Anatomic variability of the femoral vessels may, in part, explain the complications that arise and the failures that can result when cannulation of the femoral veins is attempted using the landmark technique.

The need for safe and effective patient care mandates a better understanding of the femoral vascular anatomy as it relates to central venous cannulation. The primary objective of this study was to use bedside ultrasonography to determine the amount and variability of depth, diameter, and exposure of the femoral vein in the inguinal area among adult ED patients. Specifically, we aimed to determine the amount of femoral vein exposed at three sites at which the landmark-based procedure might be performed (0, 2, and 4 cm distal to the inguinal ligament). Knowing where the amount of femoral vein exposed is greatest can indicate the preferred site for femoral central venous access. We also aimed to determine if the relationship between the amount of exposed vein and these three sites was affected by the side of the body (right or left inguinal area), body mass index (BMI), age, and sex.

## **METHODS**

### ***Study design and selection of participants***

This cross-sectional study was conducted at a large urban academic adult ED. Over a 12-week period, a random sampling of 180 participants who presented to the ED were enrolled. A priori sample size calculation based on previous pediatric data by Warkentine and colleagues<sup>8</sup>, estimated that 180 participants would be necessary to achieve 90% power. Twenty-four 4-hour blocks of time were randomly selected over the enrolment period. During these blocks, consecutive patients were approached for enrolment based on their presentation time. Patients were eligible if they had not undergone femoral artery or vein catheterization or puncture on the day of the study prior to enrolment. The hospital's Institutional Review Board approved the study protocol, and all participants provided written informed consent.

### ***Study intervention***

In preparation for femoral vessel ultrasonography, participants were placed in a supine position on their hospital stretcher with both legs fully extended and without rotation. The position of the inguinal ligament on both lower extremities was identified as a straight line from the anterior superior iliac spine to the pubic tubercle and was marked with a washable marking pen. This served as a reference line (0 cm). Two additional

lines were measured and marked 2 cm below (the recommended puncture site for cannulation) and 4 cm below (recommended as the maximum distance that one should attempt cannulation) the inguinal ligament. These three lines were used as points for vessel measurements.

Ultrasonography of the femoral vessels of each extremity was then performed by a physician coinvestigator. All investigators underwent a standardized 1-hour training session in vascular measurement. A SonoSite MicroMaxx with a 7.5 MHz linear transducer (SonoSite, Inc., Bothell, WA) was used to identify the common femoral artery and vein in the inguinal area using cross-sectional images. The vein was distinguished from the artery by ultrasonography by lack of pulsation, compressibility, and increased size when distal pressure was applied. Still images of the femoral vessels were obtained at each marked line (0, 2, and 4 cm). Vessel measurements were taken with the machine's caliper function, and each measurement was verified in real time by two data recorders.

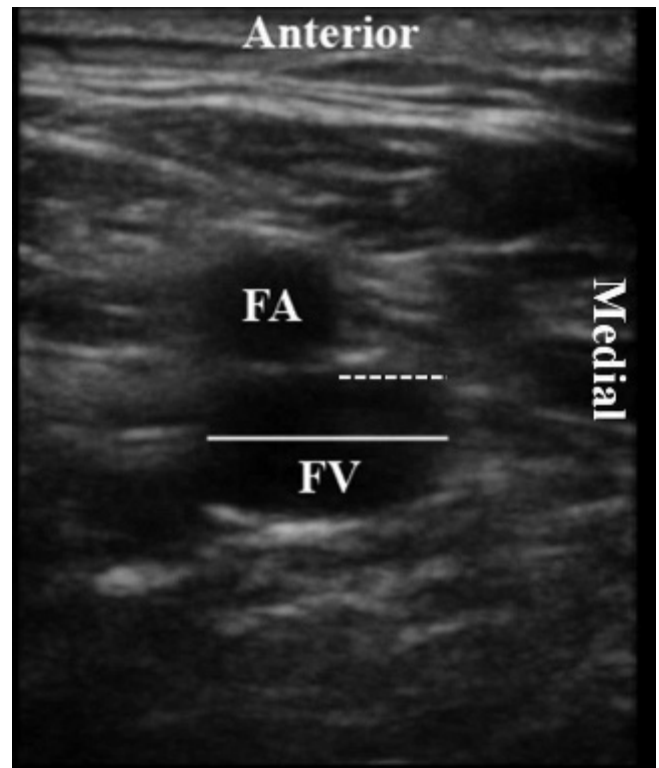
A sensitivity analysis was also performed on a subset of patients ( $n = 80$ ) to determine the effect of frog-leg positioning on the amount of exposed vein. These patients underwent repeat vessel measurement at 0, 2, and 4 cm on both sides of the body.

### Data collection and processing and outcome measures

The BMI (calculated by patient-reported height and weight), sex, and age of all participants were recorded. The diameter and depth (skin to superior wall of vessel) of the femoral artery and vein and amount of exposed femoral vein were recorded at each distance (0, 2, and 4 cm) from the inguinal ligament for both the left and right sides of the bodies of each participant. The absolute amount of exposed femoral vein was measured as the distance from the medial wall of the femoral artery to the medial wall of the vein. The percentage of vein exposed was defined as the amount of exposed vein as a percentage of the total diameter of the vein. Figure 1 displays a sample ultrasound image and illustrates measurements of the femoral vein diameter and amount of exposed vein.

### Statistical analyses

Summary statistics (e.g., means, medians, percentages, standard deviations) were calculated for the demographic



**Figure 1.** Sample ultrasound images of the femoral vessels in cross section at the inguinal ligament of a sample subject. *Solid line* indicates femoral vein diameter; *dashed line* indicates exposed femoral vein. FA = femoral artery; FV = femoral vein.

characteristics, factors of interests, and measurements obtained for this study. Because the primary outcome measurement, the amount of exposed vein, was normally distributed and met the assumptions of a linear model, repeated measures analysis of variance (ANOVA) was used to examine the relationship between the distance (0, 2, and 4 cm) from the inguinal ligament and the depth, diameter, and exposure of the femoral vein, respectively. Linear regression analyses, adjusted for age, sex, and BMI, were performed to examine the impact of these factors on the relationship between the distance from the inguinal ligament and the amount of femoral vein exposed. The amount of exposed vein at each distance from the inguinal ligament was compared between the right and left femoral vessels using paired  $t$ -tests. The mean difference for the amount of exposed vein between the right and left inguinal vessels the mean difference for the amount of exposed vein between the right and left inguinal vessels was calculated along with the corresponding 95% confidence intervals (CIs). Differences were considered significant at the  $\alpha = 0.05$  level. The overall sample

size was 180 patients and this was based on the fact that we expected no more than a 15% difference in the percentage of vein exposed between the sides.

## RESULTS

A total of 205 patients were screened for the study. Six were unable to provide informed consent, 5 were excluded at the discretion of the treating physician, and 19 declined to participate. The subject population included 101 males and 79 females. The median age was 44.5 years, with an interquartile range of 25 years and a range from 19 to 90 years. The mean BMI of the participants was  $28.3 \pm 6.2 \text{ kg/m}^2$ .

The results of the findings of depth, diameter, and exposed vein for each distance from the inguinal ligament and results of the ANOVA models are shown in Table 1 for each of the inguinal site measurements for the 180 vessel pairs. The depth and diameter of the femoral artery and diameter of the femoral vein were not different at 0, 2, and 4 cm. However, the femoral vein became deeper at further distances from the inguinal ligament. As also illustrated in Figure 2, the mean amount of exposed vein decreased at further distances from the inguinal ligament.

In the adjusted multivariate regression model ( $R^2 = 0.32$ ), the amount of femoral vein exposed was significantly associated with increasing distance from the inguinal ligament ( $\beta = -0.20$ ; 95% CI =  $-0.22$  to  $-0.18$ ). The regression coefficient ( $\beta = -0.20$ ) indicates that every 2 cm increase in distance from the inguinal ligament is associated with a 20% decrease in the amount of femoral vein exposed. Age, BMI, and

sex did not impact the observed relationship between the amount of exposed vein and the distance from the inguinal ligament.

At all distances from the inguinal ligament, some subjects had complete vein exposure (no arterial overlap) and some had no vein exposed. Eleven subjects had complete exposure of the vein at each measured distance from the inguinal ligament. The highest proportion of subjects (42%) had complete vein exposure directly at the inguinal ligament. At further distances from the inguinal ligament, there were fewer subjects with complete vein exposure: 17% at 2 cm and only 6% at 4 cm.

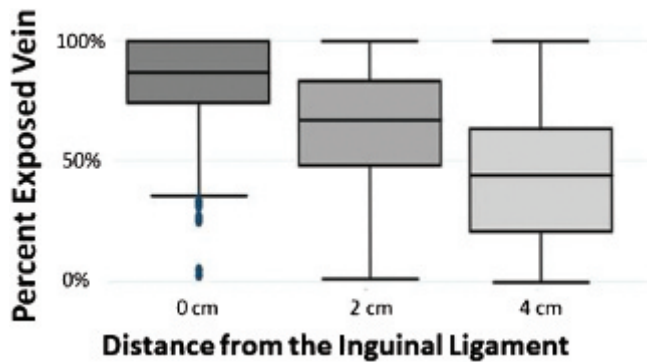
In addition, as the distance from the inguinal ligament increased, the percentage of subjects who had no femoral vein exposed increased. Of the 180 subjects, 1 (0.6%) had no portion of the vein exposed on either the right or left side at 0 cm, 3 subjects (1.6%) had no vein exposed at 2 cm, and 14 (7.8%) had no vein exposed at 4 cm. One subject had no femoral vein exposed on either side at all distances from the inguinal ligament.

There was no statistically significant difference between right and left at any distance from the inguinal ligament ( $p > 0.1$ ). The majority of subjects ( $n = 140$ ) had small differences (0.1 cm or  $< 10\%$ ) in the amount of exposed vein between right and left. The mean difference in the amount of exposed vein between the right and left vessels was 0.02 cm (95% CI  $-0.01, 0.05$ ) at 0 cm from the inguinal ligament, 0.02 cm (95% CI  $-0.06, 0.01$ ) at 2 cm, and 0.01 (95% CI  $-0.03, 0.03$ ) at 4 cm. However, there was as much as a 1.6 cm or 100% difference in one subject. Twenty subjects had at least a

**Table 1. Depth, diameter, and vein exposed at each distance for 180 vessel pairs**

	Distance from inguinal ligament			<i>p</i> value
	0 cm	2 cm	4 cm	
Depth (cm)				
Femoral artery	1.7 (0.6)	1.7 (0.7)	1.9 (0.8)	0.478
Femoral vein	2.0 (0.7)	2.1 (0.8)	2.5 (0.8)	0.049*
Diameter (cm)				
Femoral artery	0.9 (0.2)	0.8 (0.2)	0.8 (0.2)	0.449
Femoral vein	1.1 (0.3)	1.1 (0.3)	1.0 (0.3)	0.467
Femoral vein exposed (cm)	0.9 (0.4)	0.7 (0.3)	0.5 (0.4)	0.001*
Femoral vein exposed (%)	83 (21)	65 (25)	56 (30)	0.001*

Values are reported as mean (SD).  
\*Statistical significance,  $p < 0.05$ .



**Figure 2.** Box and whiskers plot of percentage of exposed vein at each distance. In this plot, the whiskers represent the minimum and maximum data points.

50% difference between sides; in those 20, the left side had more vein exposed in 11 subjects.

During interim data analysis, the sensitivity analysis revealed no difference between neutral and frog-leg positioning at any level or side of the body. Therefore, this arm of the study was discontinued.

## **DISCUSSION**

The findings in our study challenge the traditional teaching of the landmark-based technique of central venous cannulation.<sup>3,4</sup> Our study results have immediate bedside implications for this procedure.

At the commonly recommended puncture site (2 cm), only 17% of subjects had 100% of the vein completely exposed. At the inguinal ligament, however, the number of subjects who had a completely exposed vein was more than twofold greater (42%). This suggests that a more proximal puncture site may be more suitable for cannulation of the femoral vein. Concerns have been raised about the risk of intra- or retroperitoneal bleeding with puncture sites above the inguinal ligament; however, our data suggest that there are risks to using puncture sites further below the inguinal ligament as well. As the distance from the inguinal ligament increases, the deeper and less exposed the vein is, which makes the procedure more difficult to perform.

In some cases, even a more proximal puncture site at the inguinal ligament may not be suitable. For example, less than 50% of the vein was exposed in a substantial number of cases at each distance: 8% at 0 cm, 30% at 2 cm, and 57% at 4 cm. We postulate that blind cannulation using a landmark-based technique in these instances would be difficult and more likely to result in a failed attempt. We do not know the minimum amount of accessible vein required for successful cannulation. At

the inguinal ligament and at each distance below it, there were instances of 100% artery-vein overlap in individual subjects, which would arguably make venous cannulation impossible at those sites. Our results were not impacted by neutral or frog-leg positioning.

A secondary concern is that the landmark-based procedure dictates that the puncture site should be 1 cm medial to the femoral pulse. We measured the mean absolute amount of exposed vein to be 0.9, 0.7, and 0.5 cm at 0, 2, and 4 cm from the inguinal ligament, respectively. Therefore, if puncture sites are made 1 cm away from the medial wall of the artery, there may not be any vein present in some subjects. Knowing the above information beforehand by using bedside ultrasonography could be invaluable as it would allow the clinician to choose the optimal puncture site or side or perhaps to choose an alternative means of venous access altogether.

We did not observe statistically significant differences between right and left side measurements, although this study was powered to detect at least a 15% difference in the percentage of vein exposed between sides. This study was underpowered to detect a smaller statistical difference between the right and left side measurements. However, there were potentially clinically significant findings in our study population with regard to these measures. There were subjects who had no vein exposed on one side of the body but complete vein exposure on the other. These preliminary findings are not enough to support universally choosing one side over the other when attempting the landmark-based procedure but should prompt recognition that one side may be more favourable than the other in some patients. This finding further substantiates the use of ultrasonography to locate the ideal puncture site and side.

## **LIMITATIONS**

A few limitations should be noted. This study excluded patients who had already undergone femoral central venous access. In other words, patients requiring femoral central access in the ED were not studied. However, it is unlikely that those requiring femoral central access have a different anatomy than those who do not require this procedure. An additional limitation is that we measured only three sites along the femoral vessels. Continuous measurements would further define the vascular anatomy.

This study also does not directly address whether a more proximal puncture site or use of ultrasonography will enhance femoral vein cannulation. However, ultrasound guidance for vascular access has already been demonstrated to increase success rates, reduce time to cannulation, and decrease complications in attempting internal jugular vein cannulation.<sup>15,16</sup> To date, there is only one small randomized trial of ultrasound-guided femoral vessel cannulation in the emergency medicine literature.<sup>17</sup> In that study, Hilty and colleagues found ultrasound guidance to be superior to the landmark technique for femoral cannulation in 20 ED patients undergoing cardiopulmonary resuscitation. Although further study is necessary, the benefit of ultrasound guidance appears to be supported by our study findings, given the variations in amount of exposed vein according to distance from the inguinal ligament and by side of the body.

## CONCLUSION

This study demonstrates significant overlap of the femoral vessels at sites where femoral vein cannulation is often attempted and implies that ultrasound guidance would be a beneficial adjunct to this procedure. If a landmark-based procedure must be attempted, we urge consideration that femoral vein cannulation may be impossible in certain individuals. Additionally, we prompt recognition that a proportion of individual subjects will have clinically important differences between the right and left sides. Considering the anatomic variations of the femoral vessels present among and within individuals, additional research and resources should focus on the use of bedside ultrasonography as an adjunct to femoral vessel cannulation.

**Acknowledgement:** All equipment, supplies, and cost were supported by the University Emergency Medicine Foundation/Department of Emergency Medicine, Rhode Island Hospital.

**Competing interests:** None declared.

## REFERENCES

- Moore CL, Molina AA, Lin H. Ultrasonography in community emergency departments in the United States: access to ultrasonography performed by consultants and status of emergency physician-performed ultrasonography. *Ann Emerg Med* 2006;47:147-53, doi:[10.1016/j.annemergmed.2005.08.023](https://doi.org/10.1016/j.annemergmed.2005.08.023).
- Stein JC, River G, Kalika I, et al. A survey of bedside ultrasound use by emergency physicians in California. *J Ultrasound Med* 2009;28:757-63.
- Reichman EF, Simon RR. *Emergency medicine procedures*. New York: McGraw-Hill; 2004.
- Roberts JR, Hedges JR. *Clinical procedures in emergency medicine*. 3rd ed. Philadelphia: WB Saunders; 1998.
- Baum PA, Matsumoto AH, Teitelbaum GP, et al. Anatomic relationship between the common femoral artery and vein: CT evaluation and clinical significance. *Radiology* 1989;173:775-7.
- Hughes P, Scott C, Bodenham A. Ultrasonography of the femoral vessels in the groin: implications for vascular access. *Anaesthesia* 2000;55:1198-202, doi:[10.1046/j.1365-2044.2000.01615-2.x](https://doi.org/10.1046/j.1365-2044.2000.01615-2.x).
- Seyahi N, Kaveci A, Altiparmak MR, et al. Ultrasound imaging findings of femoral veins in patients with renal failure and its impact on vascular access. *Nephrol Dial Transplant* 2005;20:1864-7.
- Warkentine FH, Pierce MC, Lorenz D, et al. The anatomic relationship of femoral vein to femoral artery in euvolemic pediatric patients by ultrasonography: implications for pediatric femoral central venous access. *Acad Emerg Med* 2008;15:426-30, doi:[10.1111/j.1553-2712.2008.00087.x](https://doi.org/10.1111/j.1553-2712.2008.00087.x).
- Riley W, FitzGerald D, Cohn L. Single, percutaneous, femoral venous cannulation for cardiopulmonary bypass. *Perfusion* 2007;22:211-5, doi:[10.1177/0267659107083021](https://doi.org/10.1177/0267659107083021).
- Hopkins JW, Warkentine F, Gracely E, et al. The anatomic relationship between the common femoral artery and common femoral vein in frog leg position versus straight leg position in pediatric patients. *Acad Emerg Med* 2009;16:579-84, doi:[10.1111/j.1553-2712.2009.00430.x](https://doi.org/10.1111/j.1553-2712.2009.00430.x).
- Werner SL, Jones RA, Emerman CL. Effect of hip abduction and external rotation on femoral vein exposure for possible cannulation. *J Emerg Med* 2008;35:73-5, doi:[10.1016/j.jemermed.2007.03.023](https://doi.org/10.1016/j.jemermed.2007.03.023).
- Williams JF, Seneff MG, Friedman BC, et al. Use of femoral venous catheters in critically ill adults: prospective study. *Crit Care Med* 1991;19:550-3.
- Maecken T, Grau T. Ultrasound imaging in vascular access. *Crit Care Med* 2007;35 Suppl:S178-85, doi:[10.1097/01.CCM.0000260629.86351.A5](https://doi.org/10.1097/01.CCM.0000260629.86351.A5).
- Altin RS, Flickers S, Nalden HJ. Pseudoaneurysm and arteriovenous fistula after femoral artery catheterization: association with low femoral punctures. *AJR Am J Roentgenol* 1989;152:629-31.
- Randolph AG, Cook DJ, Gonzales CA, et al. Ultrasound guidance for placement of central venous catheters: a meta-analysis of the literature. *Crit Care Med* 1996;24:2053-8, doi:[10.1097/00003246-199612000-00020](https://doi.org/10.1097/00003246-199612000-00020).
- Leung J, Duffy M, Finckh A. Real-time ultrasonographically-guided internal jugular vein catheterization in the emergency department increases success rates and reduces complications: a randomized, prospective study. *Ann Emerg Med* 2006;48:540, doi:[10.1016/j.annemergmed.2006.01.011](https://doi.org/10.1016/j.annemergmed.2006.01.011).
- Hilty WM, Hudson PA, Levitt MA, et al. Real-time ultrasound-guided femoral vein catheterization during cardiopulmonary resuscitation. *Ann Emerg Med* 1997;29:331-6, doi:[10.1016/S0196-0644\(97\)70344-5](https://doi.org/10.1016/S0196-0644(97)70344-5).