

Blood Manganese Correlates with Brain Magnetic Resonance Imaging Changes in Patients with Liver Disease

Robert A. Hauser, Theresa A. Zesiewicz, Carlos Martinez,
Alexander S. Rosemurgy and C.W. Olanow

ABSTRACT: Background: Chronic liver failure is associated with high signal abnormalities in the basal ganglia on T1-weighted magnetic resonance imaging of the brain. These abnormalities are strikingly similar to those seen following manganese intoxication. As dietary manganese is normally cleared by the liver, we hypothesize that hepatic dysfunction could lead to manganese overload and account for the MRI abnormalities seen in patients with chronic liver disease. **Methods:** We measured blood manganese concentrations in eleven patients with biopsy-proven hepatic cirrhosis and eleven healthy age and sex-matched controls. We also performed semi-quantitative measures of T1 signal abnormalities on MRI in the patients with chronic liver disease. **Results:** Patients with cirrhosis had significantly higher blood manganese concentrations (20.6 ± 10.2 mcg/L) than controls (7.2 ± 2.7 , $p = .0013$). In addition, semi-quantitative scores of T1-weighted signal hyperintensity on MRI correlated with blood manganese concentration in patients with cirrhosis ($r = .65$, $p = .029$). **Conclusions:** These findings demonstrate that chronic liver disease is associated with manganese overload and suggest that manganese is responsible for the T1-weighted signal hyperintensity seen on MRI of patients with liver disease. As manganese intoxication is known to cause parkinsonism and an encephalopathy similar to those which occur with chronic liver disease, it is possible that manganese toxicity contributes to the development of these symptoms in liver damaged patients and that therapies which prevent or reduce manganese overload may have clinical benefit.

RÉSUMÉ: Le taux de manganèse sanguin est en corrélation avec les changements observés à l'imagerie par résonance magnétique chez les patients avec atteinte hépatique. Introduction: L'insuffisance hépatique chronique est associée à des anomalies du signal dans le noyau lenticulaire, le noyau caudé, l'avant-mur et le noyau amygdalien à l'imagerie par résonance magnétique avec pondération T1 du cerveau. Ces anomalies sont étonnamment semblables à celles observées dans l'intoxication au manganèse. Comme le manganèse de la diète est normalement éliminé par le foie, nous avons émis l'hypothèse qu'une dysfonction hépatique pourrait engendrer une surcharge en manganèse et être responsable des anomalies observées à l'IRM chez les patients atteints de maladie hépatique chronique. **Méthodes:** Nous avons mesuré la concentration de manganèse sanguin chez onze patients avec cirrhose hépatique prouvée par biopsie et onze contrôles sains, appariés pour l'âge et le sexe. Nous avons également réalisé des mesures semi-quantitatives des anomalies de signal T1 à l'IRM chez les patients atteints de maladie hépatique chronique. **Résultats:** Les patients atteints de cirrhose avaient des concentrations sanguines de manganèse significativement plus élevées (20.6 ± 10.2 mcg/L) que les contrôles (7.2 ± 2.7 , $p = .0013$). De plus, les scores semi-quantitatifs de l'hyperintensité du signal pondéré T1 à l'IRM étaient corrélés avec les concentrations sanguines de manganèse chez les patients atteints de cirrhose ($r = .65$, $p = .029$). **Conclusions:** Ces observations démontrent que la maladie hépatique chronique est associée à une surcharge en manganèse et suggèrent que le manganèse est responsable de l'hyperintensité du signal pondéré T1 observé à l'IRM des patients atteints de maladie hépatique. Il est connu que l'intoxication au manganèse cause un parkinsonisme et une encéphalopathie semblables à ce qui est observé dans la maladie hépatique chronique. Il est donc possible que la toxicité par le manganèse contribue au développement de ces symptômes chez les patients avec atteinte hépatique et que les traitements qui préviennent ou diminuent la surcharge en manganèse puissent avoir un bénéfice clinique chez ces patients.

Can. J. Neurol. Sci. 1996; 23: 95-98

Chronic liver failure is associated with abnormal increased signal intensity in the globus pallidus (GP), putamen, substantia nigra (SN), and anterior pituitary on T1-weighted magnetic resonance imaging of the brain.¹⁻³ The cause of these signal abnormalities is presently unknown. T1-weighted signal hyperintensity can be associated with lipids,⁴ methemoglobin,⁵ melanoma,⁶ calcification,⁷ neurofibromatosis⁸ and manganese.^{9,10} However, only manganese (Mn) is known to cause an abnormal increase in T1-weighted signal in the same distribution as observed in patients with chronic liver disease. We have hypothesized that patients with chronic liver disease may suffer Mn overload due to decreased hepatic elimination of normal dietary Mn.¹¹ To test this hypothesis,

we compared blood Mn concentrations in patients with biopsy-proven cirrhosis to those of healthy controls and evaluated the correlation between blood Mn concentration and the extent of T1-weighted signal hyperintensity on MRI.

From the Departments of Neurology (R.A.H., T.A.Z.), Radiology (C.M.), and Surgery (A.S.R.), University of South Florida, Tampa, Florida and the Department of Neurology, Mount Sinai School of Medicine (C.W.O.), New York, New York.

RECEIVED AUGUST 1, 1995. ACCEPTED IN FINAL FORM DECEMBER 11, 1995.
Reprint requests to: C. Warren Olanow, M.D., F.R.C.P.(C), Department of Neurology, Mount Sinai School of Medicine, 1 Gustave L. Levy Place, Box 1137, New York, New York 10029 USA.

METHODS

Eleven patients with biopsy-proven cirrhosis underwent MRI of the brain and determination of blood Mn concentration. Blood Mn concentrations were also obtained in 11 age and sex-matched healthy controls. Consecutive patients with liver-biopsy confirmed cirrhosis were selected for the study from an ambulatory care hepatology clinic. Controls consisted of employees and family members of patients with no history of liver disease. All participants signed an informed consent. Blood Mn assays were performed by Smith Kline Beecham Clinical Laboratories using graphite furnace atomic absorption spectroscopy and were verified by repeat analysis. All blood samples were collected in an identical fashion and assayed by blinded technicians. A t-test was used to compare blood Mn concentrations between patients with cirrhosis and normal controls.

MRI studies of the brain were performed on a General Electric Signa 1.5 Tesla system. MR images were obtained in T1-weighted sagittal (TR/TE = 350/19 ms), axial (TR/TE = 500/19 ms), and coronal (TR/TE = 500/19 ms) planes; spin-echo axial (TR/TE = 3200/18 ms) and coronal (TR/TE = 2400/30 ms) planes; and, T2-weighted axial (TR/TE = 3200/126 ms) and coronal (2400/80 ms) planes. MR images were evaluated by a blinded neuroradiologist (CM) using a semi-quantitative scale. Signal intensity was graded as normal (0), mildly abnormal (1+), or markedly abnormal (2+) in each of the GP, putamen, caudate nucleus, thalamus, SN, tectum, central pons, and anterior pituitary. For each patient, scores of T1-weighted signal hyperintensity in each of these regions were summed to yield a "T1-score". Pearson's correlation coefficient was used to evaluate the relationship between blood Mn concentration and T1-score. Additional MRI abnormalities were recorded when present.

RESULTS

Eleven patients with biopsy-proven hepatic cirrhosis participated in the study (Table 1). Eight (73%) were male. The mean age (\pm SD) was 56.9 ± 10.9 years, and the average disease duration was 9.1 ± 10.5 years. The presumed cause of cirrhosis was alcohol abuse in 5 cases, infectious hepatitis in 3, and unknown in 3. None of the patients had Wilson's disease, Systemic Lupus Erythematosus, a history of prior parenteral nutrition, or were receiving dietary supplementation. Eight (73%) had a functioning portal shunt.

Patients with cirrhosis had a mean blood Mn concentration of 20.6 ± 10.2 mcg/L. This compared with control individuals who had a mean blood Mn concentration of 7.2 ± 2.7 mcg/L. These values were significantly different using a t-test for samples with unequal variance ($p = .0013$).¹²

Abnormal T1-weighted signal hyperintensity was present on MRI in 10 of 11 (91%) patients with chronic liver disease (Figure 1). Total T1 scores for individual patients are shown in Table 1 and regional distribution is illustrated in Table 2. Signal abnormality was most commonly observed in the SN and GP and was most pronounced in the GP. Abnormal T1-weighted signal hyperintensity in the putamen, tectum and anterior pituitary was also noted in some patients. Signal abnormalities were not observed in the caudate, thalamus or pons in any patient. No signal changes were detected in any of these regions on T2-weighted or spin echo scans. Atrophy was present in 6 cases (55%). In 5, the atrophy was generalized. In 1, atrophy was confined to the cerebellum. No other radiologic abnormalities were detected.

There was a significant correlation between total T1 score and blood Mn concentration as shown in Figure 2 ($r = 0.65$; $p = .029$). The T1 scores and Mn levels were normally distributed on the Wilks-Shapiro test, justifying assumptions for employing the Pearson correlation coefficient. Similar results were obtained with non-parametric analyses.

DISCUSSION

We demonstrate significantly higher blood Mn concentrations in patients with biopsy-proven hepatic cirrhosis than healthy age and sex-matched controls. These findings are consistent with the findings of earlier investigators.^{11,13} We also establish that blood Mn concentrations correlate with T1 signal abnormality on MRI in patients with chronic hepatic dysfunction. These findings support the notion that Mn accumulation accounts for the signal abnormalities seen on MRI in this patient population and raise the possibility that Mn may contribute to neurologic dysfunction in patients with chronic liver disease.

Mn is a trace metal which is essential for normal life, but can cause neurotoxicity at high concentrations. Within the brain, Mn accumulates in the GP and the pars reticularis portion of the SN^{14,15} where it is primarily localized within mitochondria and

Table 1: Baseline characteristics, MRI scores and blood Mn levels of 11 patients with biopsy-proven cirrhosis.

Patient No.	Age (yrs)	Sex	Etiology	Duration (Yrs)	Shunt	Blood Mn (mcg/l)	Total T1 Score
1	40	M	Hepatitis C	10	-	45.0	7
2	60	M	ETOH	10	-	20.1	7
3	45	M	Hepatitis C	2	+	12.2	5
4	53	F	UNK	5	+	28.2	4
5	38	M	ETOH	5	+	26.2	4
6	65	M	UNK	2	-	20.4	4
7	69	F	UNK	2	+	18.9	4
8	56	M	ETOH	6	+	18.8	3
9	67	F	Hepatitis C	39	+	11.3	2
10	61	M	ETOH	7	+	6.6	1
11	65	M	ETOH	13	+	19.5	0

M = male, F = female, ETOH = alcohol abuse, UNK = unknown.

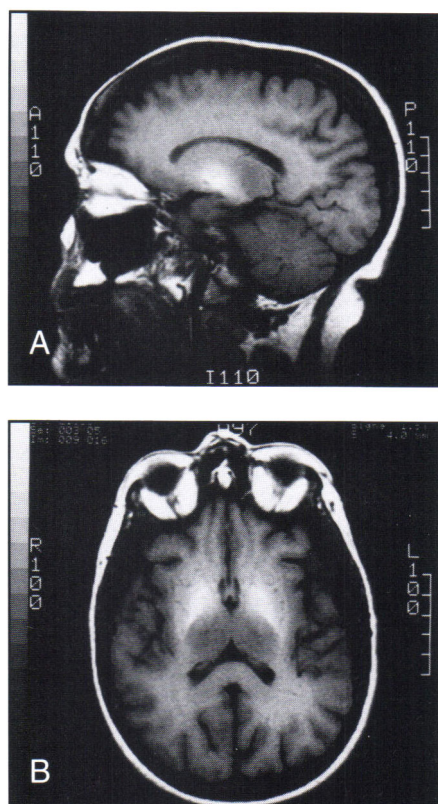


Figure 1: T1-weighted sagittal and axial MRI of a patient with hepatic cirrhosis demonstrating signal hyperintensity in the globi pallidi.

Table 2: Distribution, frequency and severity of abnormal signal hyperintensity in patients with chronic liver disease.

	GP	SN	Putamen	Tectum	Pituitary
Normal	2	1	5	8	9
Mild-Mod Abnormality	2	8	6	2	2
Marked Abnormality	7	2	0	1	0
Total Positive	9	10	6	3	2
Percent (%)	82	91	55	27	18

serves as a cofactor for numerous enzymes.¹⁶ Mn is ubiquitous in nature and widely distributed throughout the Earth's crust, water, and atmosphere. It is also normally ingested in food and water with an average daily intake of 2.6 to 3.0 mg.¹⁷ Only 1-3.5% of ingested Mn is systemically absorbed as it is rapidly cleared by the liver and excreted into bile.¹⁸⁻²⁰ Indeed, bile duct obstruction in both patients and animal models has been demonstrated to cause a marked impairment of Mn elimination.^{21,22} Mn intoxication has been reported to occur primarily as a consequence of industrial exposure.²³ However, as Mn elimination occurs predominantly through the liver, we hypothesize that hepatic dysfunction could also lead to Mn overload. Our finding of increased blood Mn concentrations in patients with hepatic cirrhosis supports this concept.

Mn is a paramagnetic ion which shortens T1 on MRI in a concentration-dependent fashion.⁹ Parenteral administration of Mn to monkeys results in Mn accumulation and abnormal high

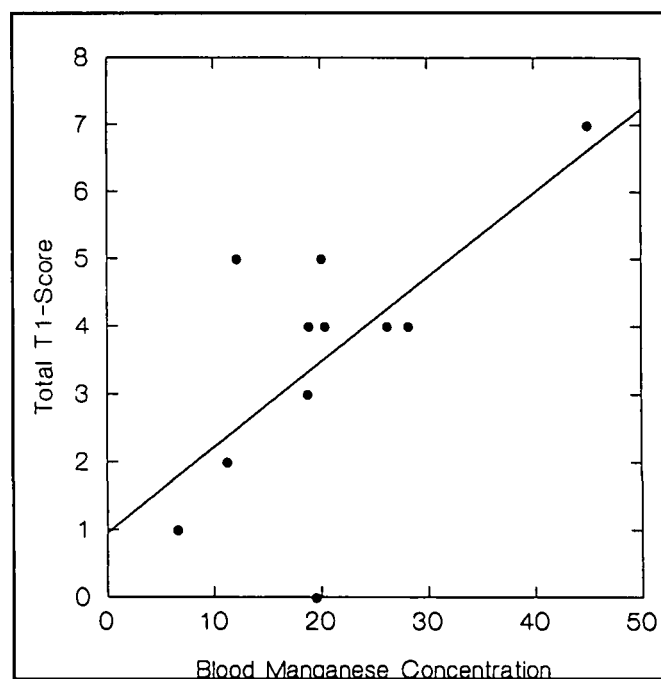


Figure 2: Blood Manganese concentration versus Total T1-Score for 11 patients with hepatic cirrhosis ($r = 0.65$, $p = .029$).

signal intensity on T1-weighted MRI in the GP, SN, putamen, and anterior pituitary.^{9,24} A similar MRI pattern has been described in patients who were thought to have Mn intoxication due to: 1) long-term total parenteral nutrition containing Mn,²⁵ 2) repair and recycling of railroad track containing a Mn steel alloy,²⁶ and 3) chronic employment in a Mn smelting plant (personal observation CWO). MRI findings have been reported to resolve following removal from the source of Mn exposure in both patients and animal models.^{9,26,27}

The MRI abnormalities identified in patients with chronic liver disease are strikingly similar to those seen in association with Mn intoxication. In our cirrhotic patients, we noted abnormal T1 signal hyperintensity in the GP (82%), SN (91%), putamen (55%), tectum (27%), and anterior pituitary (18%). Brunberg et al.¹ reported abnormal increased signal on T1-weighted images in the GP (71%), mesencephalon (40%), putamen (50%), tectum (10%), and anterior pituitary (80%) of 42 patients with chronic hepatic failure. Similarly, Kulisevsky et al.³ reported pallidal signal hyperintensity in 73% of cirrhotic patients and Inoue et al.² noted pallidal signal hyperintensity in 56% of patients with portal-systemic encephalopathy. Interestingly, T1-weighted signal abnormalities have been reported to resolve following treatment of hepatic encephalopathy.²⁸ Thus the pattern and time course of resolution of signal abnormalities seen in patients with chronic liver disease is virtually identical to that observed in Mn intoxication.

Mn accumulation in the brain may have important clinical consequences for patients with chronic liver disease. Mn intoxication can lead to both encephalopathy and parkinsonism.²⁹⁻³³ In turn, encephalopathy and parkinsonism are both well recognized features of liver disease.³⁴⁻³⁶ It is therefore reasonable to consider that Mn accumulation may account for encephalopathy and parkinsonism in patients with chronic liver disease. It is noteworthy that

Alzheimer type II astrocytes, which are characteristic findings in the GP and SN of patients with chronic liver disease, are also seen in these regions in Mn-intoxicated monkeys.²⁴ Further support for this concept derives from the case of an 8-year-old girl with developmental paucity of intrahepatic bile ducts who developed dystonia, tremor, and T1-weighted signal abnormalities on MRI in association with an increase in blood Mn levels.³⁷ Normalization of blood Mn levels following orthotopic liver transplantation was associated with resolution of neurological abnormalities and MRI changes. Additional studies are required to assess the relationship between Mn metabolism, MRI abnormalities, and clinical dysfunction in patients with liver disease. Ultimately, direct measurement of brain Mn concentration may be required to prove that Mn accumulates in the brain of patients with liver disease. Nonetheless, in the absence of a history of Mn exposure, signal hyperintensity in the GP and SN on T1-weighted MRI should suggest the possibility of Mn accumulation due to chronic liver disease. If Mn does contribute to the development of neurologic signs and symptoms in cirrhotic patients, therapies that diminish Mn intake or enhance its elimination may prevent or reverse neurologic dysfunction.

Addendum: A paper on this topic has been recently published: (Kreiger D, Kreiger S, Jansen O, et al. Manganese and chronic hepatic encephalopathy. *Lancet* 1995; 346: 270-274.)

REFERENCES

- Brunberg JA, Kanal E, Hirsch W, Van Thiel DH. Chronic acquired hepatic failure: MR imaging of the brain at 1.5 T. *Am J Neuroradiol* 1991; 12: 909-914.
- Inoue E, Shinichi H, Narumi Y, et al. Portal-systemic encephalopathy: presence of basal ganglia lesions with high signal intensity on MR images. *Radiology* 1991; 179: 551-555.
- Kulisevsky J, Pujol J, Junque C, et al. MRI pallidal hyperintensity and brain atrophy in cirrhotic patients: two different MRI patterns of clinical deterioration? *Neurology* 1993; 43: 2570-2573.
- Young SW. Nuclear Magnetic Resonance Imaging. Basic Principles. New York: Raven Press, 1984.
- Gomori JM, Grossman RI, Goldberg HI, et al. Intracranial hematomas: imaging by high-field MR. *Radiology* 1985; 157: 87-93.
- Gomori JM, Grossman RI, Shields JA, et al. Choroidal melanomas: correlation of NMR spectroscopy and MR imaging. *Radiology* 1986; 158: 443-445.
- Dell LA, Brown MS, Orrison WW, Eckel CG, Matwiyoff NA. Physiologic intracranial calcification with hyperintensity on MR imaging: case report and experimental model. *Am J Neuroradiol* 1988; 9: 1145-1148.
- Mirowitz SA, Sartor K, Gado M. High-intensity basal ganglia lesions on T1-weighted MR images in neurofibromatosis. *Am J Neuroradiol* 1989; 10: 1159-1163.
- Newland MC, Ceckler TL, Kordower JH, Weiss B. Visualizing manganese in the primate basal ganglia with magnetic resonance imaging. *Exp Neurol* 1989; 106: 251-258.
- Shinotoh H, Snow B, Hewitt KA, et al. MRI and PET studies of manganese-intoxicated monkeys. *Neurology* 1995; 45: 1199-1204.
- Hauser RA, Zesiewicz TA, Rosemurgy AS, Martinez C, Olanow CW. Manganese intoxication and chronic liver failure. *Ann Neurol* 1994; 36: 871-875.
- Altman D. Practical Statistics for Medical Research. New York: Chapman and Hall, 1991.
- Versieck J, Barbler F, Speecke A, Hoste J. Manganese, copper and zinc concentrations in serum and packed blood cells during acute hepatitis, chronic hepatitis and posthepatic cirrhosis. *Clin Chem* 1974; 20: 1141-1145.
- Larsen NA, Pakkenberg H, Damsgaard E, Heydorn K. Topographical distribution of arsenic, manganese, and selenium in the normal human brain. *J Neurol Sci* 1979; 42: 407-416.
- Bonilla E, Salazar E, Joaquin J, et al. The regional distribution of manganese in the normal human brain. *Neurochem Res* 1982; 7: 221-227.
- Baruthio F, Guillard O, Arnaud J, Pierre F, Zawislak R. Determination of manganese in biological materials by electrothermal atomic absorption spectroscopy: a review. *Clin Chem* 1988; 34: 227-234.
- Greger JL, Davis CD, Suttie JW, Lyle BJ. Intake, serum concentrations and urinary excretion of manganese by adult males. *Am J Clin Nutr* 1990; 51: 457-461.
- Greenberg DM, Copp DH, Cuthberston EM. Studies in mineral metabolism with aid of artificial radioactive isotopes; distribution and excretion particularly by way of bile, of iron, cobalt and manganese. *J Biol Chem* 1943; 147: 749-756.
- Pollack S, George JN, Reba RC, Kaufmann RM, Crosby WH. The absorption of nonferrous metals in iron deficiency. *J Clin Invest* 1965; 44: 1470-1473.
- Klaassen CD. Biliary excretion of manganese in rats, rabbits and dogs. *Toxicol Appl Pharmacol* 1974; 29: 458-468.
- Papavasiliou PS, Miller ST, Cotzias GC. Role of liver in regulating distribution and excretion of manganese. *Am J Physiol* 1966; 211: 211-216.
- Marchal G, Ni Y, Zhang X, et al. Mn-DPDP enhanced MRI in experimental bile duct obstruction. *J Comput Assist Tomography* 1993; 17: 290-296.
- Olanow CW, Calne DB, Chu NS, Perl D. Manganese-induced neurotoxicity. In: Calne DB et al., eds. *Advances in Neurodegeneration II*, Birkhauser Press, 1994: 53-62.
- Olanow CW, Good PF, Shinotoh H, et al. Manganese intoxication in the rhesus monkey; a clinical, pathological, and biochemical study. *Neurology* (In Press).
- Mirowitz SA, Westrich JJ, Hirsch JD. Hyperintense basal ganglia on T1-weighted MR images in patients receiving parenteral nutrition. *Radiology* 1991; 181: 117-120.
- Nelson K, Golnick J, Korn T, Angle C. Manganese encephalopathy: utility of early magnetic resonance imaging. *Br J Indust Med* 1993; 50: 510-513.
- Mirowitz SA, Westrich TJ. Basal ganglia signal intensity alternations: reversal after discontinuation of parenteral manganese administration. *Radiology* 1992; 185: 535-536.
- Watanabe A, Murakami J, Ando T, et al. Reduction of increased signal intensity in the basal ganglia on T1-weighted MR images during treatment of hepatic encephalopathy. *Internal Med* 1993; 32: 10-14.
- Mena I, Marin O, Fuenzalida S, Cotzias GC. Chronic manganese poisoning: clinical picture and manganese turnover. *Neurology* 1967; 17: 128-136.
- Huang CC, Chu NS, Lu CS, et al. Chronic manganese intoxication. *Arch Neurol* 1989; 46: 1104-1106.
- Cook DG, Fahn S, Brait KA. Chronic manganese intoxication. *Arch Neurol* 1974; 30: 59-64.
- Huang CC, Lu CS, Chu NS, et al. Progression after chronic manganese exposure. *Neurology* 1993; 43: 1479-1483.
- Calne DB, Chu NS, Hung CC, Lu CS, Olanow CW. Manganism and idiopathic parkinsonism: similarities and differences. *Neurology* 1994; 44: 1583-1586.
- Sherlock S, Summerskill WHJ, White LP, Phear EA. Portal-systemic encephalopathy: neurological complications of liver disease. *Lancet* 1954; 267: 453-457.
- Victor M, Adams RD, Cole M. The acquired (non-Wilsonian) type of chronic hepatocerebral degeneration. *Medicine* 1965; 44: 345-396.
- Read AE, Sherlock S, Laidlaw J, Walker JG. The neuro-psychiatric syndromes associated with chronic liver disease and an extensive portal-systemic collateral circulation. *Quart J Med* 1967; 36: 135-150.
- Barron TF, Deveny AG, Mamourian AC. Symptomatic manganese neurotoxicity in a patient with chronic liver disease: correlation of clinical symptoms with MRI findings. *Ped Neurol* 1994; 10: 145-148.