

LETTER TO THE EDITOR**To THE EDITOR****Very Delayed Onset of Neurosarcoidosis After Isolated Optic Perineuritis****Keywords:** Sarcoidosis, Perineuritis, Adalimumab

Optic perineuritis is an uncommon condition, characterized by inflammation localized primarily to the optic nerve sheath. Without the characteristic imaging finding of optic nerve sheath enhancement, it may be difficult to distinguish clinically from optic neuritis as there is variable involvement of the optic nerve itself, causing visual field deficits and decreased central acuity.¹ Primary disease may represent a localized form of idiopathic orbital inflammation. Secondary optic perineuritis can occur as a manifestation of sarcoidosis, Behcet's, granulomatosis with polyangiitis, IgG4 disease, anti-myelin oligodendrocyte glycoprotein (MOG) protein-related disorders, giant cell arteritis, and infections such as tuberculosis and syphilis (Table 1).² We describe a case of neurosarcoidosis presenting as isolated optic perineuritis.

A 41-year-old right-handed female presented to a general ophthalmologist in October 2017 with a complaint of decreased vision in the left eye for 3 months. She was referred to our neuro-ophthalmology clinic for query optic neuritis as her contrast-enhanced MRI was unremarkable and left optic disc edema was noted on exam.

The patient noticed progressive diminishing vision in the left eye accompanied by a periorbital pressure sensation. No other neurologic symptoms were volunteered or elicited on direct questioning. Medical history was significant for meningitis as a teenager, right hip arthroscopy and malaise and rash following insect bites in Cuba 18 months prior to the current presentation. The patient worked as a fitness trainer and was in good general health. She took no medications, only supplements including fish oil, probiotics, vitamin D, and olive leaf extract. There was a history of breast cancer in several family members and her father died from metastatic cancer in his 50s with an unknown primary.

On our assessment in January 2018, visual acuity was 20/20 and 20/60-2, improving to 20/40 with pinhole. A hyperopic shift was present in the left eye. Color vision was 15/16 and 14/16 using Ishihara plates. Ocular motility was full. No relative afferent pupillary defect (RAPD) was present and anterior segment slit lamp examination was normal. Fundus examination in the right eye was normal, with no optic disc pallor or edema. In the left eye, there was circumferential disc edema with choroidal folds at the posterior pole (Figure 1A). 24-2 visual field testing showed only enlargement of the blind spot in the left eye.

The clinical history and findings were not in keeping with demyelinating optic neuritis. Most notably, the time course of vision loss was too long with no improvement since its onset and there was no relative afferent pupillary defect. Work-up was initiated to investigate other causes of optic disc edema with decreased vision including infection, inflammatory processes, and infiltrative lesions. Blood work showed normal erythrocyte

sedimentation rate (ESR), C-reactive protein (CRP), and angiotensin converting enzyme (ACE), negative rheumatoid factor (RF), anti-nuclear antibodies (ANA) and anti-neutrophilic cytoplasmic autoantibody (ANCA), and normal protein electrophoresis complement and IgG4 levels. Anti-MOG antibodies were negative. Serology for syphilis, HIV, Lyme, Toxoplasmosis, and Bartonella was negative. Fluorescein angiography showed some leakage from the optic disc consistent with her disc edema but no abnormalities in the retinal vasculature. Breast ultrasound and CT of the chest, abdomen, and pelvis were unremarkable, notably there was no evidence of hilar lymphadenopathy or pulmonary disease.

When her optic disc edema continued to worsen and no clear cause had been identified, MRI of the brain and orbits was repeated in February 2018. This revealed mild concentric enhancement of the left optic nerve sheath, consistent with optic perineuritis (Figure 1B, C). Despite all of the negative investigations, it was unclear whether this was a primary or secondary process. A lumbar puncture was performed and revealed only increased protein (1.07 g/L), normal glucose (2.7 mmol/L), and a few lymphocytes with irregular nuclear membranes; flow cytometry showed no clonal proliferation. Cerebrospinal fluid (CSF) ACE level was normal and cultures were negative. IL2 and oligoclonal bands were not tested due to our low suspicion for multiple sclerosis. She was offered an empiric course of steroids, but declined as she was troubled by the lack of a clear diagnosis.

She was reimaged in January of 2019 after experiencing visual decline in the left eye (now 20/400) and new neurologic symptoms of numbness and discomfort running down the right leg into her foot, as well as bilateral finger paresthesias. MRI brain and spine revealed a new finding of enhancing lesions in the left medial temporal lobe (Figure 2A) along with two enhancing extramedullary lesions in the lumbosacral spinal cord. In addition, perineural enhancement was now also present in the right optic nerve. These findings pointed to a working diagnosis of neurosarcoidosis and rheumatology became involved. Repeat CT chest, abdomen, and pelvis were again negative for findings of sarcoidosis, and pulmonary function tests were unremarkable. Given the absence of any other lesions, a stereotactic brain biopsy of one of the left temporal lobe lesions was performed in April 2019. This showed focal non-caseating granulomas in the cortex (Figure 2B-D) composed of histiocytes and lymphocytes with a rare giant cell.

When the diagnosis of neurosarcoidosis was confirmed histologically, our patient agreed to proceed with treatment. She was started on prednisone, with the later addition of methotrexate. Despite treatment, she developed right optic disc edema and vision decreased to 20/40 with persistent perineural enhancement on repeat MRI. The decision was made to add a biologic agent and adalimumab was chosen due to convenient subcutaneous dosing route and less need for methotrexate co-therapy as compared to infliximab. With this, the right disc edema resolved and vision improved to 20/20, though unfortunately the left eye remained 20/400. She has been evaluated extensively for other systemic manifestations of sarcoidosis, no other organ system involvement was detected.

Table 1. Etiology of optic perineuritis

| |
|---|
| Primary/idiopathic |
| Sarcoidosis |
| Infection: Syphilis, TB, Lyme, Bartonella, HZV/HSV |
| Anti-MOG antibody disease |
| IgG4 disease |
| Vasculitis: Giant cell arteritis, GPA, Behcet's |
| Connective tissue/autoimmune disease: SLE, inflammatory bowel disease, RA, gout |
| Neoplasia: Lymphoma, leukemia |

GPA=granulomatosis with polyangiitis; HSV=herpes simplex virus; HZV=herpes zoster virus; MOG=myelin oligodendrocyte glycoprotein; RA=rheumatoid arthritis; SLE=systemic lupus erythematosus; TB=tuberculosis.

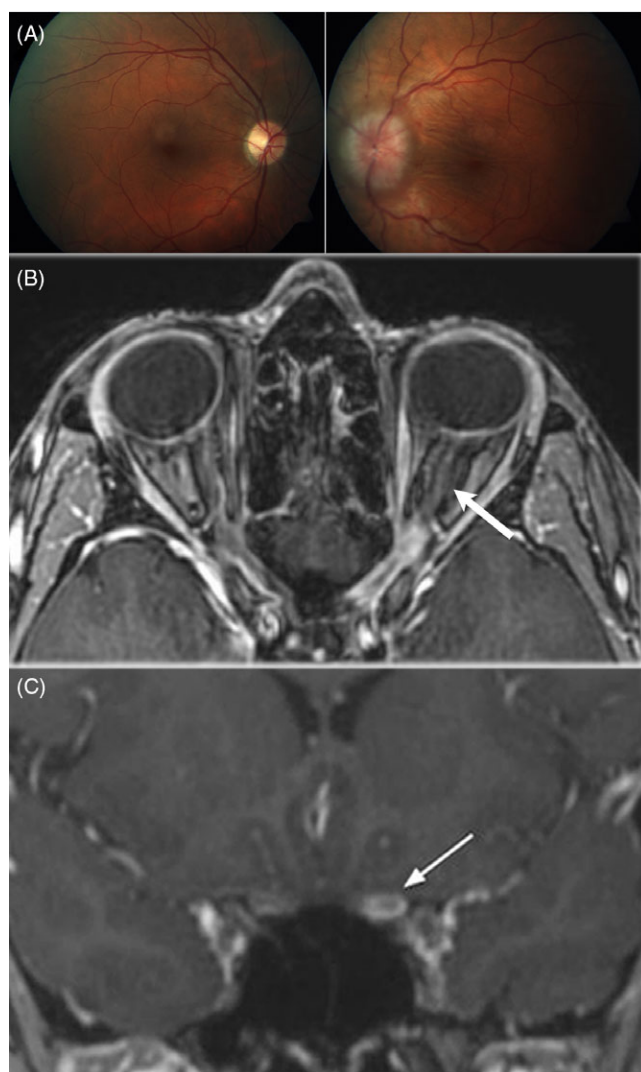


Figure 1: (A) Fundus photographs of right and left eye; the left eye shows marked, circumferential optic disc edema and choroidal folds. Left optic sheath enhancement (white arrow) on T1 FS, (B) axial and (C) coronal MRI.

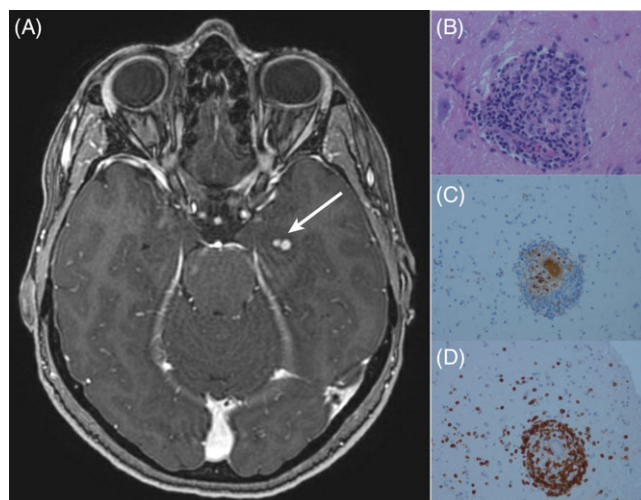


Figure 2: (A) T1 FS axial MRI showing small enhancing foci in the left mesial temporal lobe (white arrow). Microscopy images showing characteristic non-caseating granulomas of sarcoidosis in temporal lobe grey matter. (B) H/E stain; granuloma composed of core of macrophages (CD 68-positive, C) with surrounding mantle of reactive T lymphocytes (CD 3-positive, D) magnifications, (B) 400x; (C), (D) 200x. 50 micron size bar bottom right. Stains for microorganisms were negative and there was no vasculitis (not shown).

While ocular involvement occurs in approximately 25% of patients with sarcoidosis, neuro-ophthalmic disease is uncommon (2%–10% of all cases) and rarely occurs in isolation, unaccompanied by other neurologic or systemic features such as pulmonary disease.³ Optic perineuritis can occur as a first manifestation of sarcoidosis^{4,5}; however, our case is unique in that visual symptoms preceded any other neurologic manifestations for over 1 year and to date, there have been no other systemic findings of this condition. A high index of suspicion for sarcoidosis must be maintained in unexplained optic perineuritis. A second learning point from this case is that delay in initiation of treatment, most commonly high dose prednisone, is associated with worse visual outcome.^{1,2} Unfortunately, the lack of definitive diagnosis reinforced a pre-existing aversion to medical therapy in our patient. Only when the prospect of severe bilateral vision loss became apparent did she accept treatment with steroids and immunosuppression.

CONFLICT OF INTEREST

The authors have no conflicts of interest to declare.

STATEMENT OF AUTHORSHIP

LD, JP, and ARR wrote the manuscript; all authors revised the manuscript for intellectual content and approved the final draft.

Laura Donaldson 

McMaster University, Department of Surgery, Division of Ophthalmology, Hamilton, Ontario, Canada

John Provias
McMaster University, Department of Pathology and Molecular
Medicine, Hamilton, Ontario, Canada

Raj Carmona
McMaster University, Department of Medicine, Division of
Rheumatology, Hamilton, Ontario, Canada

Amadeo R. Rodriguez
McMaster University, Department of Surgery, Division of
Ophthalmology, Hamilton, Ontario, Canada

McMaster University, Department of Medicine, Division of
Neurology, Hamilton, Ontario, Canada

Correspondence to: Amadeo R. Rodriguez, 2757 King St E,
Hamilton, ON L8G 5E4, Canada. Email: arodrig@mcmaster.ca

REFERENCES

1. Purvin V, Kawasaki A, Jacobson DM. Optic perineuritis: clinical and radiographic features. *Arch Ophthalmol.* 2001;119:1299–306.
2. Hickman SJ. Optic perineuritis. *Curr Neurol Neurosci Rep.* 2016;16:16–21.
3. Koczman JJ, Rouleau J, Gaunt M, Kardon RH, Wall M, Lee AG. Neuro-ophthalmic sarcoidosis: the University of Iowa experience. *Semin Ophthalmol* 2008;23:157–68.
4. Micieli JA, Streutker CJ, McIntyre K. Isolated optic perineuritis as the presenting sign of sarcoidosis. *J Neuroophthalmol.* 2020;40:255–57.
5. Garri F, Rinaldi F, Perini P, et al. Slowly progressive optic perineuritis as the first clinical manifestation of sarcoidosis. *J Neuroophthalmol.* 2020;41:e39–e41.