

An investigation of *Encephalitozoon cuniculi* in the wild rabbit *Oryctolagus cuniculus* in Victoria, Australia

BY J. C. COX, D. PYE

*Commonwealth Serum Laboratories, Poplar Road, Parkville, 3052,
Victoria, Australia*

J. W. EDMONDS AND ROSAMOND SHEPHERD

*Keith Turnbull Research Institute, Department of Crown Lands and Survey,
Frankston, 3199, Victoria, Australia*

(Received 3 September 1979)

SUMMARY

Sera from 823 wild rabbits (*Oryctolagus cuniculus*) collected from a number of geographic regions of Victoria, Australia over the past eight years were examined for antibodies to *Encephalitozoon cuniculi*, along with sera from 46 hares (*Lepus europaeus*) (Pallas) and 57 New Zealand wild rabbits. No sera were positive, implying that this common laboratory rabbit parasite is absent from wild rabbits in these areas. However, wild rabbits were found to be readily infected by the oral route with small numbers of tissue-culture-grown spores of *E. cuniculi*. A possible explanation for the absence of encephalitozoonosis in wild rabbits is that *E. cuniculi* infection places them at a biological disadvantage for survival. The natural hygiene habit of wild rabbits may also significantly decrease post-natal infection.

INTRODUCTION

Encephalitozoon cuniculi (Microsporida, Glugidae) is a frequently encountered intracellular protozoan parasite of laboratory animals (Canning, 1977). The parasite has a worldwide distribution and, in Australia, most laboratory rabbit colonies examined have a high prevalence of infection (Cox, Walden & Nairn, 1972; Testoni, 1974; Cox & Pye, 1975). Despite the ubiquitous nature of *E. cuniculi*, no systematic study of the prevalence of infection in populations of wild animals has been reported; the only reports of *E. cuniculi* infection in wild rabbits being of an isolated case in the USA (Jungherr, 1955) and, very recently, three cases in Scotland (Wilson, 1979). In the present study, the prevalence of encephalitozoonosis in wild rabbits (*Oryctolagus cuniculus*) and their susceptibility to infection was investigated.

MATERIALS AND METHODS

Field specimens

Sera. Most sera (823) were from wild rabbits collected during the years 1971–9 in Victoria. Collection areas are shown in Fig. 1. Geographical areas ranged from semi-

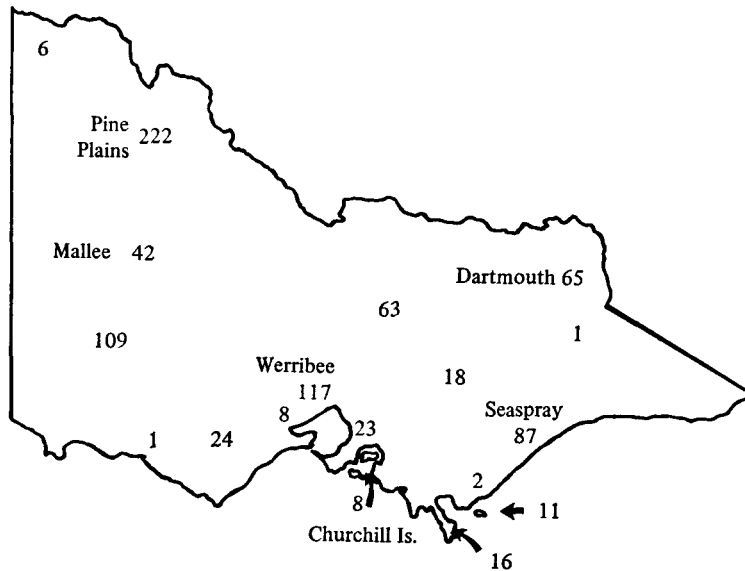


Fig. 1. Collection areas of wild rabbit sera in Victoria, Australia. Figures refer to number of individual sera collected.

arid inland (e.g. Mallee) and dry coastal regions (e.g. Seaspray) to wet, high-altitude areas (e.g. Dartmouth). Several island populations were also investigated. The 46 hare sera were collected from central and western Victoria and the Mallee. Sera from 57 New Zealand wild rabbits were collected from the South Island in 1979. They were kindly supplied by Dr J. Morgan Williams, Ministry of Agriculture and Fisheries, Rabbit Research Group, Christchurch, New Zealand.

Kidney tissue. The kidneys of 24 rabbits trapped at Pine Plains were removed on capture and a portion immediately placed in 3% (w/v) formaldehyde in phosphate buffer, pH 7.0.

Laboratory studies

Sera. Dr Barbara Smith, ICI Tasman Laboratories, Upper Hutt, New Zealand kindly supplied 67 sera from the ICI mixed-breed laboratory rabbit colony.

Rabbits. Young wild rabbits for experimental infection were collected near Werribee and individually caged in an isolation room. All rabbits were seronegative to *E. cuniculi* and were maintained in isolation for several weeks prior to artificial infection.

Growth and assay of E. cuniculi. *E. cuniculi* were grown in the human diploid cell line, CSL 300. Cell cultures were grown on Basal Medium Eagle (BME) supplemented with 10% (v/v) unheated calf serum. Infected and confluent cultures were maintained on Medium 199 supplemented with 5% unheated fetal calf serum.

Spores were assayed in CSL 300 cell cultures and the results expressed as focus forming units (FFU)/ml as described elsewhere (Pye & Cox, 1979).

Artificial infection of rabbits. Rabbits were fed orally, by means of a stomach tube,

with varying numbers of *E. cuniculi* organisms in 5 ml of tissue culture medium. Two rabbits each were fed 10^6 , 3×10^4 or 10^3 organisms of *E. cuniculi*. A total organism to viable spore count ratio of 1.4×10^3 meant that rabbits in the three groups received 700, 21 or 0.7 viable spores each. Rabbits were tested at weekly intervals for serum antibodies and spores of *E. cuniculi* in the urine. Ten to 16 weeks after initiation of infection, infected and control rabbits were killed and tissue blocks of kidney, lung, heart, liver, spleen and brain were removed.

Immunofluorescence. *E. cuniculi* for antigen were grown in CSL 300 cells as described previously (Cox *et al.* 1977). Sera were tested by indirect immunofluorescence for the presence of antibodies to *E. cuniculi* at dilutions of 1/10, 1/100 and 1/1000 then titrated at appropriate doubling dilutions. Titres were expressed as the highest serum dilution giving bright staining of the spore body. The conjugate used was a fluorescein-conjugated sheep IgG anti-rabbit immunoglobulin (CSL).

Tissue blocks were quick-frozen in a slurry of isopentane and liquid nitrogen at -160°C . Sections, 6 μm , were cut in a cryostat at -25°C , transferred to microscope slides at room temperature and dried in a current of air for 2 h at 2°C . Sections were stained by direct immunofluorescence using a fluorescein-conjugated rabbit IgG anti-*E. cuniculi* reagent at a concentration of 1 mg globulin/ml. The conjugate had been absorbed with tissue homogenates (Nairn, 1976) to eliminate non-specific staining of tissue sections. Approximately 2 cm^2 of each tissue was examined for the presence of *E. cuniculi*.

Urine specimens were acidified to pH 2.5 to 3.0 by dropwise addition of 1 M citrate, 1 M phosphate buffer, pH 2.0, centrifuged at 1000 *g* for 10 min; the sediment was then washed in phosphate-buffered saline (0.01 M-phosphate, 0.145 M-NaCl, pH 7.2). Smears on glass slides were examined by direct immunofluorescence for the presence of *E. cuniculi*. By this technique, 0.1 to 0.2 ml of each urine specimen was examined.

Histology. Tissue blocks were fixed in 3% (w/v) formaldehyde in phosphate buffer, pH 7.0; paraffin sections were cut at 5 μm . At least 2 cm^2 of each tissue was stained with haematoxylin and eosin and examined microscopically for pathological changes. Tissues were also stained by a modified Gram stain (Brown & Brenn, 1931) and examined for the presence of *E. cuniculi*.

RESULTS

Of the 926 individual sera tested – 823 Victorian wild rabbits, 46 Victorian wild hares and 57 New Zealand wild rabbits – not one showed significant antibody to *E. cuniculi* (i.e. titre of 10 or more). The sera of 12 Victorian rabbits and four hares were weakly reactive (titre approximately 5) with spores of *E. cuniculi*. These rabbits were not from any specific location though two rabbits from Churchill Island were amongst the 12. No pathologic changes consistent with encephalitozoonosis were seen in any of the 24 kidneys from wild rabbits; nor were any *E. cuniculi* seen.

Four of the eight wild rabbits in the infectivity experiment, one from each of the

infection levels and one control, died in the early stages of the experiment, seemingly from non-specific causes. The others remained in apparently good condition throughout the experiment.

The course of infection in the two rabbits receiving the higher doses of *E. cuniculi* was similar to that already described for laboratory rabbits (Cox, Hamilton & Attwood, 1979) though the time to develop serum antibodies was delayed. In the rabbit receiving about 700 viable spores, serum antibodies were detected by week 5 and spores were being excreted in the urine by week 7. The rabbit was killed at week 10, when the titre was greater than 1000. Intracellular groups of *E. cuniculi* were observed in the lung and kidney and lesions typical of encephalitozoonosis were seen in the brain, heart, lung and kidney. The rabbit receiving 21 spores developed serum antibodies about week 7 and spores were first detected in the urine at week 8. When killed at week 12, the kidney, spleen, lung and brain contained intracellular accumulations of *E. cuniculi*. Lesions typical of encephalitozoonosis were seen in the brain, heart, lung, liver and kidney. The kidney of this rabbit showed an abnormally severe infection, around 10^6 spores of *E. cuniculi*/ml were excreted in the urine over several weeks and an average of 45 infected renal cells were counted in each section of 0.5 cm² area. The rabbit receiving approximately 0.7 viable spores showed a transient low antibody titre peaking at 20 at week 14. Tissues from this rabbit and from the control at week 16 showed no evidence of *E. cuniculi* infection.

Just under 30% (19 of 67) of the laboratory rabbits from the ICI Tasman Laboratories, New Zealand showed significant antibody titres to *E. cuniculi*. This figure is similar to that reported for laboratory rabbit colonies in Australia (Cox & Pye, 1975).

DISCUSSION

The unexpected result obtained in this study is that *E. cuniculi* is not a parasite of wild rabbits in Victoria or in New Zealand. This is despite the ubiquitous nature of the parasite in laboratory rabbit colonies in these localities, and the established susceptibility of the wild rabbit to infection. The possibility of a new serotype of *Encephalitozoon* antigenically unrelated to *E. cuniculi* was effectively ruled out by the negative findings in the 24 wild rabbit kidneys examined.

There are good reasons to believe that wild rabbits in Victoria have been exposed to *E. cuniculi*. Domestic-type rabbits have been released in small numbers in a number of regions of Victoria (Myers, 1970) including Western Victoria and Churchill Island (Edmonds, 1977). On the basis of the currently-known prevalence of infection in laboratory rabbit colonies, a number of these rabbits should have had encephalitozoonosis.

There are two unrelated reasons why *E. cuniculi* may have failed to establish in the wild. The first concerns the mode of transmission of infection. Very strong evidence for transplacental transmission has been reported (Hunt, King & Foster, 1972), although the importance of this mode of transmission is not established. Cox *et al.* (1977), were able to show in laboratory rabbits that infection occurred either transplacentally or at the nursing stage. The latter was presumed to occur

by ingestion of contaminated urine. Whereas laboratory rabbits have no option but to urinate in their cages, wild rabbits habitually leave their burrows to urinate. Thus, horizontal transmission of infection by this means could be expected to be reduced below the level required to maintain the disease.

Survival pressures on juvenile wild rabbits in Victoria are much more severe than on juvenile laboratory rabbits. Predation alone may account for up to 80% of juveniles (Myers, 1970). Myxomatosis and nutritional stress generally reduce the population to about 20% of the breeding season peak, most of those lost being juveniles and sub-adults (Shepherd & Edmonds, 1978). Additionally, *E. cuniculi*-infected rabbits show a depressed immune response (Cox, 1977) which would be expected to make them more susceptible to any concurrent infection. In this atmosphere of severe competition, any set-back to optimal health would be expected to act as a significant selection factor.

It was tempting to speculate that the release of myxoma virus in south-eastern Australia in 1950 was the final pressure which eliminated *E. cuniculi* from the wild rabbit population. The study of rabbits in New Zealand, where myxoma virus has never been established, was initiated to test this hypothesis. The negative result suggests that there are sufficient selection pressures against *E. cuniculi* in wild rabbits even in the absence of myxoma virus.

Several minor observations merit comment. The low transient titre observed in the wild rabbit fed 0.7 viable spores is similar to that described previously in two laboratory rabbits (Cox, Pye & Gallichio, 1976). The explanation suggested then, that the rabbits had been exposed to a sub-infective dose of *E. cuniculi*, may be applicable here. However, the long delay period between ingestion of organisms and development of the transient titre would not be expected if this were the cause. The low titres observed in the 12 wild rabbits and two hares could have a similar explanation, though this would imply that some animal in the wild harbours *E. cuniculi*. Conversely, the titres could be a weak cross-reaction with some other immunogen.

We wish to thank Professor H. D. Attwood for examining the histology preparations and Mr R. C. Hamilton for their preparation. The technical assistance of Rhonda Horsburgh and Chris Roberts is greatly appreciated.

REFERENCES

- BROWN, J. H. & BRENN, L. (1931). A method for the differential staining of Gram-positive and Gram-negative bacteria in tissue sections. *Bulletin of The Johns Hopkins Hospital* **48**, 69–73.
- CANNING, ELIZABETH U. (1977). Microsporidia. In *Parasitic Protozoa IV* (ed. Julius P. Kreier), pp. 155–96. New York: Academic Press.
- COX, J. C. (1977). Altered immune responsiveness associated with *Encephalitozoon cuniculi* infection in rabbits. *Infection and Immunity* **15**, 392–5.
- COX, J. C., GALLICCHIO, HEATHER A., PYE, D. & WALDEN, N. B. (1977). Application of immunofluorescence to the establishment of an *Encephalitozoon cuniculi*-free rabbit colony. *Laboratory Animal Science* **27**, 204–9.

- COX, J. C., HAMILTON, R. C. & ATTWOOD, H. D. (1979). An investigation of the route and progression of *Encephalitozoon cuniculi* infection in adult rabbits. *Journal of Protozoology* **26**, 260–65.
- COX, J. C. & PYE, D. (1975). Serodiagnosis of nosematosis by immunofluorescence using cell-culture-grown organisms. *Laboratory Animals* **9**, 297–304.
- COX, J. C., PYE, D. & GALLICHO, HEATHER A. (1976). The use of cultivated Microsporidia in serological diagnosis. In *Proceedings of the first International Colloquium on Invertebrate Pathology and IXth Annual Meeting, Society for Invertebrate Pathology*, pp. 85–87. Kingston, Canada: Printing Department, Queen's University.
- COX, J. C., WALDEN, N. B. & NAIRN, R. C. (1972). Presumptive diagnosis of *Nosema cuniculi* in rabbits by immunofluorescence. *Research in Veterinary Science* **13**, 595–97.
- EDMONDS, J. W. (1977). Studies on immunoglobulin allotypes of wild rabbits *Oryctolagus cuniculus* in south-eastern Australia. Unpublished thesis. Monash University, Melbourne, Australia.
- HUNT, R. D., KING, N. W. & FOSTER, H. L. (1972). Encephalitozoonosis: Evidence for vertical transmission. *Journal of Infectious Diseases* **126**, 212–14.
- JUNGHERR, E. (1955). *Encephalitozoon* encephalomyelitis in a rabbit. *Journal of the American Veterinary Medical Association* **127**, 518.
- MYERS, K. M. (1970). The rabbit in Australia. In *Proceedings of the advanced study institute on 'Dynamics of numbers in populations'* (ed. P. J. de Boer and G. R. Gradwell), pp. 478–506. The Netherlands: PUDOC.
- NAIRN, R. C. (1976). *Fluorescent Protein Tracing*, 4th ed. Edinburgh: Churchill Livingstone.
- PYE, D. & COX, J. C. (1979). A simple focus assay for *Encephalitozoon cuniculi*. *Laboratory Animals* **13**, 193–5.
- SHEPHERD, ROSAMOND, C. H. & EDMONDS, J. W. (1978). Myxomatosis in the Mallee region of Victoria, Australia. *Journal of Hygiene* **81**, 239–43.
- TESTONI, F. J. (1974). Enzootic renal nosematosis in laboratory rabbits. *Australian Veterinary Journal* **50**, 159–63.
- WILSON, JANE M. (1979). *Encephalitozoon cuniculi* in wild European rabbits and a fox. *Research in Veterinary Science* **26**, 114.