

An investigation of colonization of the conjunctival sac of sheep by bacteria and mycoplasmas

G. J. R. DAGNALL

*The Royal Veterinary College, Department of Animal Health, Boltons Park,
Potters Bar, Hertfordshire EN6 1NB*

(Accepted 17 January 1994)

SUMMARY

The conjunctival sacs of 100 healthy adult ewes and 20 lambs and 76 adult ewes affected by ovine keratoconjunctivitis (OKC) were examined microbiologically. *Branhamella ovis* was the only organism regularly isolated from healthy ewes and lambs, *Mycoplasma conjunctivae* was isolated from the conjunctival sac of nine ewes but its occurrence was not associated with clinical signs of ovine keratoconjunctivitis. *Mycoplasma conjunctivae* and *Branhamella ovis* were isolated significantly more often from eyes affected by OKC than from unaffected eyes.

INTRODUCTION

There have been few investigations specifically concerned with the resident flora of the conjunctival sac of healthy sheep. Spradbrow [1] isolated very few species of bacteria from the conjunctival sac of sheep but Egwu and colleagues [2] found a diverse flora after sampling sheep once. The only organisms known to be of clinical significance, and which can be isolated from the conjunctival sac of healthy sheep and those affected by ovine keratoconjunctivitis (OKC), are *Mycoplasma conjunctivae* [3–6] and *Branhamella ovis* [6, 7]. *Chlamydia psittaci* has been associated with a specific follicular conjunctivitis [8–10].

OKC is characterized by a rapid onset of conjunctivitis with purulent discharge, followed by keratitis and corneal opacity. Corneal ulceration may occur in severe cases. Nasal discharge, lachrymation, photophobia, hyperaemia of the sclera and conjunctiva and pannus are seen.

In this investigation, three surveys were conducted. In the first, healthy adult sheep were sampled once to determine the variety and relative numbers of organisms present in the conjunctival sac. In the second, the variety and relative numbers of organisms present in the conjunctival sac of two groups of healthy lambs and the dams of one of the groups were investigated; the objective of this was to ascertain whether organisms isolated were resident flora or were present only transiently. In the third survey, the microbiological flora of the conjunctival sac of sheep affected by OKC was investigated.

METHODS

*Sampling methods**First survey*

The macroscopic appearance of the eyes of 100 housed, healthy adult ewes of various breeds was recorded and samples were taken from the conjunctival sac and nasal mucosa with cotton-tipped swabs.

Second survey

Ten healthy, cross-bred Welsh Mountain lambs (L1–L10) which had not had contact with sheep other than their dams were sampled from the conjunctival sac at 1, 4, 6, 13, 20, 34, 48, 70, 97, 116 and 137 days after birth. They were housed in a polythene tunnel (Polypen) until 70 days of age when they were moved to a paddock. The eyes of 10 other lambs (R1–R10) were sampled from the conjunctival sac of both eyes 1, 5, 10, 15 and 20 days after birth; they were observed for 60 days after the last sampling. Their dams (E1–E10) were also sampled similarly, on day 1 and day 20 of the investigation. The ewes and lambs were housed in an enclosed barn and had contact with other lambs of the same age and with adult ewes. The sampling methods were identical to those used in the first survey.

Third survey

The eyes of 67 adult sheep with varying degrees of severity of OKC were examined. The sheep were either bred and kept at the Royal Veterinary College or were from commercial flocks. Samples were taken in all seasons from housed sheep and sheep kept outdoors.

Macroscopic examination

The cornea was examined for opacity or pannus. The extent of opacity, whether restricted to the limbus or covering the whole cornea, was recorded, as was the extent and severity of pannus. The conjunctiva, sclera and nictitating membrane were examined for the presence of hyperaemia, oedema and lymphoid follicles. The sites at which follicles were seen and the presence of blepharospasm and discharge from the eyes were recorded.

Cytological examination (sheep affected by OKC)

A few drops of 0.4% oxybuprocaine hydrochloride (Benoxinate-Minims) were instilled into each conjunctival sac. After 4–5 min, cells were collected by scraping the palpebral conjunctiva of each eye with a sterile spatula with rounded ends and then transferring them as smears onto glass slides. The smears were allowed to dry partially for 1–2 min, fixed in methanol for 10 min and subsequently stained by the Giemsa method, dehydrated in xylol and then mounted in DPX (R A Lamb Ltd, London). They were examined microscopically for bacteria and mycoplasmas attached to the cells and for chlamydial inclusions within the cells.

Cultural methods

Three samples were taken from each eye by firmly rolling sterile cotton-tipped swabs along the palpebral conjunctiva to allow the whole surface of the swab to come into contact with the conjunctiva. One swab was examined for the presence

of chlamydiae [11], the second swab was used to inoculate Columbia blood agar base (CM331, Unipath Ltd, Basingstoke, Hampshire) containing 5% defibrinated sheep blood, heated (chocolate) blood agar [12] and McConkey agar (CM76, Unipath Ltd.). Plates were incubated aerobically at 37 °C overnight and then examined. Incubation was continued for a further 2 days after which the plates were discarded. Organisms were identified by methods described by Cowan [13].

The third swab was used for the inoculation of mycoplasma and ureaplasma agar and broth [14]. The mycoplasma agar was incubated at 37 °C for up to 14 days in a closed container in which a candle had been burnt to extinction. The agar surface was examined with a dissecting microscope. Colonies resembling mycoplasmas were subcultured, cloned three times and identified by the growth inhibition test [15] or by the use of specific antibodies in indirect immunofluorescent tests on the colonies [16].

RESULTS

First survey

No gross abnormalities were seen in the conjunctival sac of any of the ewes. Bacteria and mycoplasmas were cultured from the conjunctival sac of the left, right or both eyes of 39 of 100 ewes. *B. ovis* was isolated from the left eye of 30 and both eyes of 9. The colonies, designated S-type, had an entire edge, were smooth, grey, glossy and β -haemolytic on agar containing sheep blood [17, 18]. Coagulase-negative staphylococci were isolated from 1 eye of 17 ewes and both eyes of 2. *M. conjunctivae* was isolated from 1 eye of 11 ewes and from both eyes of 4. Other organisms isolated on one occasion were *Escherichia coli*, *Streptomyces* sp., *Moraxella* sp., *Staphylococcus aureus* and diphtheroids.

B. ovis was isolated from the nasal mucosa of 39 ewes, *M. conjunctivae* from 10 and both organisms from 5. There was no associated nasal discharge and in all ewes the same organisms were also isolated from the conjunctival sac.

Second survey

Lambs L1–L10

Typical, S-type colonies of *B. ovis* were isolated from lambs L6 and L7. The right eye of lamb L7 was colonized by *B. ovis* on days 1, 4, 6, 13, 34, 48 and 116 after birth. On day four there was profuse lachrymation and mild hyperaemia of the palpebral conjunctiva in the right eye but no lesions were seen from day 6 onwards. *B. ovis* was isolated from the left eye at the end of the sampling period (day 137).

B. ovis was found in the right eye of lamb L6 on days 13 and 34 and, on day 20 in association with coagulase-negative staphylococci. No pathological changes were seen on these days. However, on day 48, many follicles were seen in the palpebral conjunctiva (Fig. 1) and a profuse, pure growth of *B. ovis* was obtained from the conjunctival fluid. Profuse, pure growth of *B. ovis* was also obtained at each subsequent sampling except on day 70 (the day the lambs were moved from the Polypen to a paddock). The follicles were still present at the end of the sampling period (137 days).

A few coagulase-negative staphylococci and diphtheroids, which were not

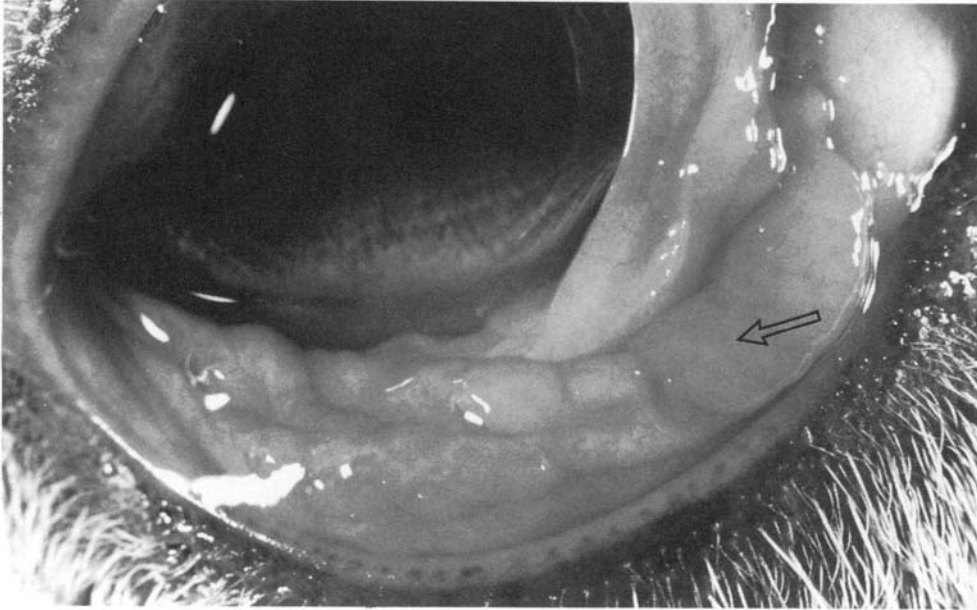


Fig. 1. Follicles (arrow) on the palpebral conjunctiva of lamb L6.

characterized, were also isolated from some lambs, but there was no gross pathological change in the eyes.

Mild, transient hyperaemia of the palpebral conjunctiva was seen on the fourth day after birth in both eyes of L1 and L2. The same changes were seen in lamb L1 on day 6 after birth; thereafter the eyes of both animals appeared normal. No organisms were isolated from L1 or L2.

Lambs R1–R10

B. ovis was isolated from 6 lambs on day 10 (4 animals), 15 (3) and 20 (5) after birth. Colonies were grey and β haemolytic but differed from those isolates from L6 and L7 in that they were rough and crenated (R-type colonies) [18]. In their non-reactivity to carbohydrates and other laboratory tests they conformed to the type strain of *B. ovis* (NCTC 11227).

Other organisms isolated included coagulase-negative staphylococci, α haemolytic streptococci, diphtheroids, *Bacillus* sp., *Streptomyces* sp., *Erwinia herbicola* and *Pseudomonas maltophilia*. There were no clinical signs of conjunctivitis in lambs R1–R10 during the investigation, nor 60 days thereafter.

Ewes E1–E10

B. ovis (R-colony type) was isolated from both eyes of E3 on days 1 and 20. *B. ovis* (S-colony type) was isolated from the right eye of E7 on day 1 and from both eyes on day 20. *E. herbicola* was isolated from the right eye of E7 on day 1, and in association with diphtheroids from the left eye of E3 on day 20. The ewes remained clinically healthy throughout the investigation.

Third survey

Of 134 eyes (67 sheep) examined, 97 eyes (72%) showed some degree of OKC.

Table 1. *Bacteria, mycoplasmas and fungi isolated from the conjunctival sac of 67 sheep with ovine keratoconjunctivitis (OKC)*

	Clinical signs of OKC (97 eyes)	Unaffected (37 eyes)
Bacteria, mycoplasmas or fungi isolated	64	11
<i>M. conjunctivae</i>	44	2
<i>B. ovis</i>	28	3
Coagulase negative staphylococci	17	5
<i>M. conjunctivae</i> and <i>B. ovis</i>	14	0
<i>Bacillus</i> spp.	10	4
α haemolytic streptococci	6	1
<i>M. arginini</i>	5	0
<i>Streptomyces</i> spp.	3	1
<i>Mucor</i> spp.	3	1
<i>M. conjunctivae</i> and <i>C. psittaci</i>	0	1

P. haemolytica, *A. laidlawii*, *Staph. aureus* and *B. cereus* were each isolated once from eyes affected by OKC but not from healthy eyes.

Macroscopic appearance of OKC

The macroscopic changes in the eyes were characteristic. The conjunctiva and sclera were hyperaemic, there was pannus, lachrymation and some degree of corneal opacity. Lymphoid follicles were absent except on two occasions when they were seen on the third eyelid and the palpebral conjunctiva. In both cases follicles were associated with colonization with *B. ovis*.

Organisms isolated

Details of the isolates and their occurrence are shown in Table 1. Of 97 eyes with clinical signs of OKC, *M. conjunctivae* was isolated from 44. This was statistically significant when compared with isolation of the organism from unaffected eyes ($\chi^2 = 17.23$, $P < 0.001$). *B. ovis* was isolated from 28 affected eyes which was significantly more than the number of isolations of the organism from unaffected eyes ($\chi^2 = 5.37$, $P = 0.02$). *B. ovis* was isolated in pure culture from six eyes affected by OKC and from four in mixed culture with coagulase-negative staphylococci. *B. ovis* was isolated once in pure culture from an unaffected eye; once in mixed culture with a coagulase negative staphylococcus and once in mixed culture with a *Bacillus* sp. Coagulase-negative staphylococci were isolated once in pure culture from the eye of a sheep affected by OKC.

Of those eyes with clinical signs of OKC from which *M. conjunctivae* was isolated, 14 were diagnosed as being infected with mycoplasmas by microscopic examination of scrapings of the conjunctival mucosa. Cocci resembling *B. ovis* were seen in smears from 2 eyes of 4 sheep; a profuse growth of *B. ovis* was obtained from all 4. No other bacteria were seen microscopically, reflecting their low isolation rate on culture.

DISCUSSION

This study has shown that few organisms can be isolated from the conjunctival sac of healthy sheep, even when sampled regularly over a relatively long period of

time. Only *B. ovis* was isolated consistently from healthy ewes and lambs and this organism represented the major part of the resident flora of the conjunctival sac, the other isolates being apparently transient or opportunistic colonizing organisms, as described below.

In a more limited study, Spradbrow [1] was surprised to find relatively few organisms in the conjunctival sac, and suggested that *B. ovis* might be a cause of OKC in conjunction with factors such as exposure to ultraviolet light or trauma. In contrast, Egwu and colleagues [2] found representatives of a large number of bacterial genera and of two genera of *Mollicutes*. No pathogenic role was ascribed to any of the organisms apart from *M. conjunctivae* and *Staph. aureus*.

M. conjunctivae has been incriminated as a causal agent in OKC [4–6, 19], but in some sheep examined in the current study it was present in the conjunctival sac in the absence of clinical signs of OKC. Possibly, those ewes from which *M. conjunctivae* was isolated had been in contact with sheep affected with OKC. As the animals appeared clinically healthy they may have been sampled just prior to development of OKC. Alternatively, *M. conjunctivae* may have been part of the resident flora but in numbers that were too small to elicit a clinical response. Furthermore, there may be differences in pathogenicity between individual strains of *M. conjunctivae*. This would result in some sheep exhibiting clinical signs of OKC whereas others would not.

B. ovis and *M. conjunctivae* were isolated from the nasal mucosa of some sheep in which the organisms were also detected in the conjunctival sac. This suggests that the probable source of nasal infection was the eye and that organisms had passed down the naso-lachrymal duct to colonize the nasal mucosa. Any nasal discharge would be a potential source of pathogenic organisms for other susceptible sheep.

B. ovis was isolated from affected and unaffected eyes but significantly more often from those affected by OKC. Clinical signs in affected eyes were usually mild and mostly confined to inflammatory changes in the conjunctiva. There was evidence to suggest that *B. ovis* may have a role in the development of OKC by contributing to the severity of the condition. It is important that the pathogenic mechanisms of *B. ovis* be defined so that the role of the organism in OKC can become clearer.

Although coagulase-negative staphylococci were isolated frequently, these organisms have never been implicated in OKC and were regarded as opportunistic colonizing bacteria, although their clinical significance was not investigated further. Colonization by other organisms such as *Bacillus* sp. and *Streptomyces* sp. was also considered insignificant because they were isolated relatively infrequently. In ewes affected by OKC, *M. conjunctivae* was the organism isolated most frequently. It was also present in two apparently healthy eyes, once in association with *C. psittaci*, but there was no evidence from this survey that *C. psittaci* was a significant primary cause of OKC.

ACKNOWLEDGEMENT

The author wishes to thank Deborah Tysall for her help in the field work involved in these surveys.

REFERENCES

1. Spradbrow PB. The bacterial flora of the ovine conjunctival sac. *Aust Vet J* 1968; **44**: 117–18.
2. Egwu GO, Faull WB, Bradbury JM, Clarkson MJ. Ovine infectious keratoconjunctivitis: a microbiological study of clinically unaffected and affected sheep's eyes with special reference to *Mycoplasma conjunctivae*. *Vet Rec* 1989; **125**: 253–6.
3. Barile MF, del Giudice RA, Tully JG. Isolation and characteristics of *Mycoplasma conjunctivae* sp. n. from sheep and goats with keratoconjunctivitis. *Infect Immun* 1972; **5**: 70–6.
4. Jones GE, Foggie A, Sutherland A, Harker DB. Mycoplasmas and ovine keratoconjunctivitis. *Vet Rec* 1976; **99**: 137–41.
5. Laak EA ter, Schreuder BEC, Smith-Buys CMC. The occurrence of *Mycoplasma conjunctivae* in the Netherlands and its association with infectious keratoconjunctivitis in sheep and goats. *Vet Q* 1988; **10**: 73–83.
6. Dagnall GJR. A study of ovine keratoconjunctivitis with special reference to *Mycoplasma conjunctivae* and *Branhamella ovis*. [PhD thesis]. Royal Veterinary College, London: University of London, 1991.
7. Woodland RM, Wilsmore AJ, Dagnall GJR. Sheep conjunctivitis caused by *Chlamydia psittaci* and *Branhamella ovis*. *Proc Eur Soc Chlamydia Res* 1988; **1**: 134.
8. Cello RM. Ocular infection in animals with PLT (*Bedsonia*) group agents. *Am J Ophthalmol* 1967; **63**: 1270–4.
9. Storz J, Pierson RE, Marriott ME, Chow TL. Isolation of psittacosis agents from follicular conjunctivitis in sheep. *Proc Soc Exp Biol Med* 1967; **125**: 857–60.
10. Andrews AH, Goddard PC, Wilsmore AJ, Dagnall GJR. A chlamydial keratoconjunctivitis in a British sheep flock. *Vet Rec* 1987; **120**: 238–9.
11. Woodland RM, Kirton RP, Darougar S. Sensitivity of mitomycin-C treated McCoy cells for isolation of *Chlamydia trachomatis* from genital tract specimens. *Eur J Clin Microbiol* 1987; **6**: 653–6.
12. Sims W. Oral haemophili. *J Med Microbiol* 1970; **3**: 615–25.
13. Cowan ST, ed. Cowan and Steel's manual for the identification of medical bacteria. 2nd ed., Cambridge: Cambridge University Press, 1974.
14. Freundt EA. Culture media for classic mycoplasmas. In: Razin S, Tully JG, eds. *Methods in mycoplasmaology*, vol 1. Mycoplasma characterization. New York: Academic Press, 1983: 130–1.
15. Clyde WA. Mycoplasma species identification based upon growth inhibition by specific antisera. *J Immunol* 1964; **92**: 958–65.
16. Rosendal S, Black FT. Direct and indirect immunofluorescence of unfixed and fixed mycoplasma colonies. *Acta Path Microbiol Scand* 1972; **80B**: 615–22.
17. Lindqvist K. A neisseria species associated with infectious keratoconjunctivitis of sheep *Neisseria ovis* Nov. Spec. *J Infect Dis* 1960; **106**: 162–5.
18. Dagnall GJR. Some cultural characteristics of *Branhamella ovis* isolated from the conjunctival sac of sheep. *Vet Microbiol* 1993; **37**: 45–52.
19. Nicolet J von, Dauwalder M, Boss PH, Anetzhofner J. Die "primär" infektiöse Keratoconjunctivitis des Rindes. Mögliche ätiologische Rolle von *Mycoplasma bovoculi*. *Schweizer Arch Tierheilk* 1976; **118**: 141–50.