

## SHORT NOTES

*Note Brevi / Communications Brèves / Kurze Mitteilungen*

---

### TRISOMY 2q

B. DALLAPICCOLA (1), A. FORABOSCO (2), A. CALABRO (1)

(1) Department of Medical Genetics, University of Rome, Italy

(2) Department of Human Normal Anatomy, University of Modena, Italy

*Two unrelated patients with trisomy 2q32→q37, resulting from maternal balanced translocations t(2; 13) (q32 q33) and t(2; 15) (q32 q26) are reported. Comparison of the clinical findings suggests that trisomy 2q is associated with a rather characteristic constellation of symptoms and malformations.*

The chromosome rearrangements studied before the introduction of the new banding techniques can now be evaluated exactly by means of these techniques. Thus, previously reported patients with chromosome unbalance may be reconsidered to establish precise karyotype-phenotype correlations, which often allow the identification of peculiar patterns of malformations in relation with the involvement of specific chromosomal segments.

This is the case of the trisomy for the long arm of chromosome 2, hitherto studied with the banding techniques in one patient (Forabosco et al. 1973). We have now reconsidered the only other known case of this syndrome, which was reported before the introduction of the banding techniques (Ricci et al. 1968). Comparison of the clinical stigmata observed in these two patients leads to the conclusion that trisomy 2q is associated with a rather characteristic constellation of symptoms.

#### CASE 1

V.L., a female newborn baby, was born in October 1966, when the mother was 26 and the father 25. Family history unremarkable. Pregnancy and delivery with no complications. Birth weight 2270 g, length 50 cm, head circumference 30.5 cm. Physical examination revealed microcephaly, with prominent occiput and forehead (Fig. 1), hypertelorism, short nose with a flat nasal bridge and upturned nostrils, cleft palate, micrognathia. Ears were low set, slanted and malformed. There was clinodactyly of the 5th fingers and bilateral talipes. The neck was short. Cardiac examination revealed an harsh murmur. Radiographic examination showed slight skull asymmetry, absence of the 12th ribs, and decreased iliac index.

At the age of 45 days the patient died because of heart failure.

At a postmortem examination, stenosis of aorta, hypoplasia of kidneys, and multiple intestinal ectasias were found.

*Cytogenetic Studies.* By standard Giemsa a 46, XY, Dq+ karyotype was found in the patient on

peripheral blood cultures. The healthy mother was carrier of a translocation  $t(2q-; Dq+)$ . Giemsa banding technique indicates that the translocation involves chromosomes 2 and 15. The break points occur at bands q32 on chromosome 2 and q26 on chromosome 15.

The chromosome formula in the mother was  $46,XX,t(2;15)(q32\ q26)$  (see Fig. 2). Therefore, the proposita was trisomic for a large part of the long arm

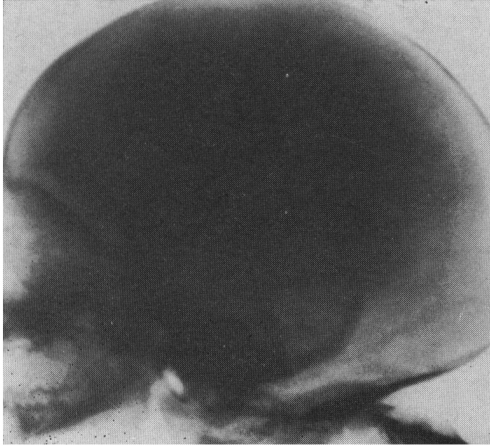

Fig. 1. Case 1: lateral view of the skull.

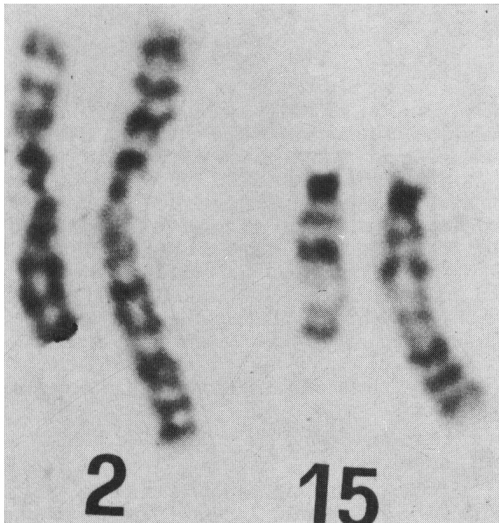

Fig. 2. Partial karyotype of a Giemsa banded metaphase of the mother of case 1:  $t(2;15)(q32\ q26)$ .

of chromosome 2 ( $q32 \rightarrow q37$ ), and monosomic for the telomeric part of the long arm of chromosome 15.

## CASE 2

R.M., a female newborn baby, was born in December 1971 at term of a pregnancy with no complications. Birth weight 2700 g. At the age of 24 months the following malformations were recorded: microcephaly; the skull is brachycephalic, with prominent frontal bone and forehead; hypertelorism, with antimongoloid slant of palpebral fissures and strabismus; short nose and upturned nostrils; long philtrum; micrognathia; low set, slanted and malformed ears, with folded helix, prominent anthelix and anti-tragus, and large concha; short neck; clinodactyly of 5th fingers; muscles' hypoplasia (Fig. 3).

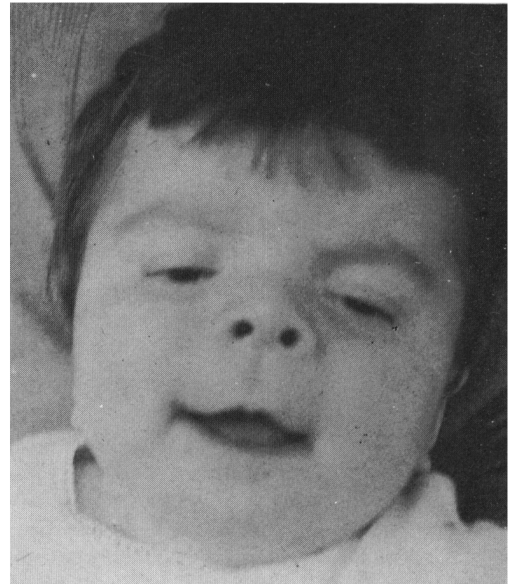


Fig. 3. Case 2 at age 24 months.

*Cytogenetic Studies.* By means of R and T banding techniques a  $46,XX,13q+(q32)mat$  was found in the patient. The mother had a  $46,XX,der(13),t(2;13)(q32\ q33)$  chromosomal formula. Therefore, the patient is trisomic for part of the long arm of chromosome 2 ( $q32 \rightarrow q37$ ) and monosomic for band q34 of chromosome 13 (Fig. 4).

## DISCUSSION

Chromosome 2 is very often involved in chromosomal rearrangements in man (review in Genest et al. 1971). Several reports deal with

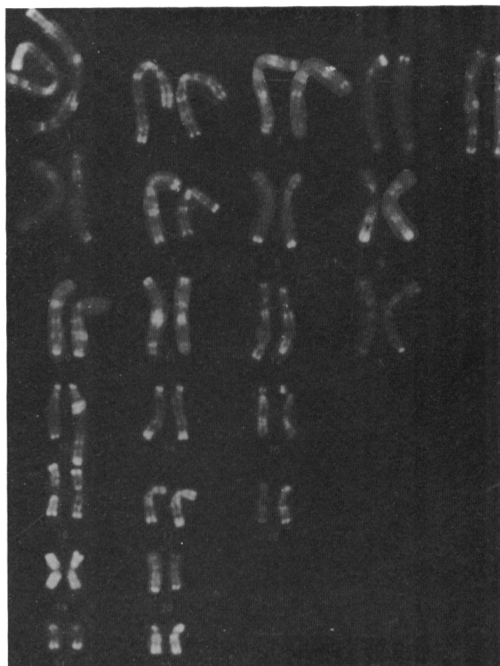


Fig. 4. R-banded karyotype of case 2: 46, XX, 13q+ (q32) mat.

the translocation of a portion of the long arm of chromosome 2 onto the distal end of the long arm of chromosomes 13 (Genest et al. 1971, Forabosco et al. 1973), 14 (Reisman and Kasahara 1968, Fitzgerald 1974), and 15 (Wurster et al. 1969). In some cases the nature of the D chromosome involved in the translocation has not been stated (Lisco and Lisco 1967, Ricci et al. 1968, Davison et al. 1970).

Most cases of 2-D translocations have been identified in subjects with congenital malformations. The effect of these chromosomal rearrangements on the phenotype cannot be easily determined. It was suggested (Genest et al. 1971) that congenital defects and presence of a 2-D translocation in most reported cases is not coincidental and possibly the material lost from chromosome 2 should be considered more important than that lost from the D chromosomes. However, these conclusions must be reconsidered studying these subjects with the banding techniques. The patients reported in this paper are the only proved cases of unbalanced offsprings resulting parental 2-D translocations. Both patients are trisomic for bands q32 → q37 of chromosome 2 and monosomic for the distal band of chromosomes 15 and 13, respectively (Table 1).

Table 1

	Case 1	Case 2
Authors	Ricci et al.	Forabosco et al.
Year	1968	1973
Technique	G-bands	R, T-bands
Parental abnormality	t(2q-; 15q+) mat	t(2q-; 13q+) mat
Chromosomal unbalance in the patient:		
trisomy	2q	2q
segment	q32 q37	q32 q37
monosomy	15q terminal (q26)	13q terminal (q34)
Sex	F	F
Length of gestation	40 weeks	40 weeks
Birth weight	2270 g	2700 g
Age at time of examination	1 month	2 years
Evolution	dead at 45 days	alive

Table 2

Main symptoms	Case 1	Case 2
Poor psychomotor development	+	+
Hypotrophy	+	+
Microcephaly	+	—
Macrocephaly	—	+
Skull asymmetry	+	+
Prominent forehead	+	+
Hypertelorism	+	+
Antimongoloid slant of palpebral fissures	+	+
Short nose, flat nasal bridge	+	+
Upturned nostrils	+	+
Long philtrum	+	+
Cleft palate	+	—
Micrognathia	+	+
Low set, slanted, malformed ears	+	+
Short neck	+	+
Clinodactyly 5th fingers	+	+
Malformed feet	+	+
Low total ridge count	+	+
Distal axial triradii	+	+
Muscular hypotrophy	+	+
Congenital heart disease	+	—
Absent 12th ribs	+	—

They present a closely comparable pattern of malformations (Table 2) consisting of severe hypotrophy and poor psychomotor development; prominent forehead; hypertelorism with antimongoloid slant of palpebral fissures; short nose with flat nasal bridge and upturned nostrils; long philtrum; micrognathia; low set, slanted and malformed ears; short neck; clinodactyly of 5th fingers; malformed feet; dermatoglyphic abnormalities.

The clinical findings seem to be due to the trisomy of the long arm of chromosome 2, there being no evidence of malformations of the Dq-syndromes (Laurent et al. 1971).

Further observations are necessary to provide more information and to confirm the karyotype-phenotype correlations suggested by our observations.

#### REFERENCES

- Davison B.C., Bedford J., Dunn W. 1970.  $t(2q-; Dq+)$  in a mentally retarded female child. *J. Med. Genet.*, 7:81-82.
- Fitzgerald M.G. 1974. Balanced  $(2q-; 14q+)$  translocation. *Aust. Paediatr. J.*, 10: 180-183.
- Forabosco A., Dutrillaux B., Toni G., Tamborino G., Cavazzuti G. 1973. Translocation équilibrée  $t(2; 13)(q23; q33)$  familiale et trisomie 2q partielle. *Ann. Genet.*, 16: 255-258.
- Genest P., Lachance R., Poty J., Jacob D. 1971. Autosomal translocation in a mentally retarded male child with  $46,XY,t(2q-; 13q+)$  complement: case report and review. *J. Med. Genet.*, 8: 504-508.
- Laurent C., Noël B., David M. 1971. Essai de classification de délétions du bras long d'un chromosome du group D. A propos d'un cas  $15q-$ . *Ann. Genet.*, 14: 33-40.
- Lisco E., Lisco H. 1967. A case of balanced 2/D translocation. *Ann. Genet.*, 10: 42.
- Reisman L.E., Kasahara S. 1968. An unusual chromosome abnormality: 2/D translocation. *Am. J. Dis. Child.*, 115: 625-628.
- Ricci N., Dallapiccola B., Cotti G. 1968. Translocation 2-D familiale. *Ann. Genet.*, 11: 111-113.
- Wurster D.H., Hoefnagel D., Benirschke K., Allen F.H. 1969. Placental chorangiomas and mental deficiency in a child with 2/15 translocation:  $46,XX,t(2q-; 15q+)$ . *Cytogenetics*, 8: 389-399.