

Mechanism of Cerebral Vasospasm Following Subarachnoid Hemorrhage in Monkeys

R.L. Macdonald, B.K.A. Weir, M.G.A. Grace, M.H. Chen, T.P. Martin and J.D. Young

ABSTRACT: This paper reviews our recent studies on the mechanism of cerebral vasospasm following subarachnoid hemorrhage (SAH) in monkeys. Middle cerebral artery (MCA) vasospasm was maximal at 7 days, resolving by 14 days, and absent at 28 days after SAH. Arterial fibrosis was not detected during vasospasm, although there was intimal hyperplasia with fibrosis 28 days after SAH. On scanning electron microscopy, smooth muscle cells from vasospastic arteries had corrugated cell membranes and appeared similar to cells contracted pharmacologically, suggesting that vasospastic smooth muscle is contracted. Morphometric analysis of arteries obtained 7 days after SAH showed no significant increases in arterial wall area of vasospastic arteries compared with normal MCAs. The results suggest vasospasm in monkeys is not due to hypertrophy, hyperplasia, or fibrosis in the arterial wall. Vasospasm may be mainly vascular smooth muscle contraction, which damages the arterial wall, leading to secondary structural changes in the arterial wall which occur after angiographic vasospasm.

RÉSUMÉ: Mécanisme du vasospasme cérébral à la suite d'une hémorragie sous-arachnoïdienne chez le singe. Dans cet article, nous revoyons nos études récentes sur le mécanisme du vasospasme à la suite d'une hémorragie sous-arachnoïdienne (HSA) chez le singe. Le vasospasme de l'artère cérébrale moyenne (ACM) était maximal à 7 jours, en résolution à 14 jours et absent à 28 jours post-HSA. La fibrose artérielle n'a pas été détectée pendant le vasospasme, bien qu'il existait une hyperplasie intimale avec fibrose 28 jours post-HSA. À la microscopie électronique, les cellules musculaires lisses des artères en vasospasme avaient des membranes cellulaires ridées et avaient l'apparence de cellules contractées pharmacologiquement, suggérant que le muscle lisse de l'artère en vasospasme est contracté. Une analyse morphométrique des artères obtenues 7 jours post-HSA n'a pas montré d'augmentation significative de la surface de la paroi artérielle des artères en vasospasme comparées à des ACMs normales. Ces résultats suggèrent que le vasospasme chez le singe n'est pas dû à l'hypertrophie, à l'hyperplasie ou à la fibrose de la paroi artérielle. Il est possible que le vasospasme soit essentiellement une contraction du muscle lisse vasculaire qui endommage la paroi artérielle, amenant des changements structuraux secondaires de la paroi artérielle.

Can. J. Neurol. Sci. 1992; 19: 419-427

The delayed and protracted arterial narrowing which characterizes cerebral vasospasm following subarachnoid hemorrhage (SAH) has proven extremely resistant to treatment.^{1,2} The poor efficacy of vasodilator drug treatment for vasospasm suggests vasospastic arteries are not simply vasoconstricted. In support of this, pharmacologic studies show vasospastic arteries have decreased contractility, increased spontaneous tone, and increased stiffness when compared to normal or physiologically-contracted cerebral arteries.³⁻⁵ Hence, many investigators have not emphasized the role of smooth muscle contraction and vasoconstriction in vasospasm, focusing instead on what pathologic changes within the vasospastic arterial wall could narrow the lumen and account for the resistance of these arteries to vasodilation. Kassell, et al., for example, suggested vasospasm is a proliferative vasculopathy in which lumen narrowing is due to hypertrophy or hyperplasia of the arterial wall.⁶ They cited as

evidence the striking intimal proliferation sometimes seen after SAH in humans and cats.

Other pathologic changes, such as smooth muscle cell vacuolation and necrosis, adventitial inflammation, vessel wall edema, and fibrosis of the tunica media have been reported in vasospastic arteries and after exposure of cerebral arteries to a variety of agents including physiologic vasoconstrictors.⁷⁻⁹ These changes, particularly arterial fibrosis, might also contribute to vasospasm by fixing cerebral arteries in a contracted state, accounting for the pharmacologic and clinical observations noted above.

Alternatively, vasospasm may be an abnormal form of smooth muscle contraction, possibly mediated by vasotoxic substances released from subarachnoid clot.¹ Rather than being directly related to lumen narrowing, arterial wall pathology may simply reflect response of the arterial wall to injury incurred during the period of prolonged contraction. Persistent, resistant

From the Division of Neurosurgery (RLM, BKAW), Department of Surgery (MGAG), Department of Physiology (JDY), and Medicine-Dentistry Electron Microscopy Unit (MHC), Faculty of Medicine, and Faculty of Rehabilitation Medicine (TPM), University of Alberta, Edmonton

Received December 13, 1991. Accepted March 30, 1992

Presented in part at the XXVIth Canadian Congress of Neurological Sciences in Halifax, June 1991. Winner of the K.G. McKenzie Memorial Prize 1991

Reprint requests to: R.L. Macdonald, M.D., Ph.D., 60 Fairleigh Crescent, Toronto, Ontario, Canada M6C 3R9

contraction and cell injury might occur because contraction is mediated by biochemical processes not normally occurring in smooth muscle.

Immunofluorescence microscopy and amino acid analysis,¹⁰ computer-assisted image analysis,¹¹ scanning electron microscopy (SEM) of exposed vascular smooth muscle,¹² and transmission electron microscopy (TEM) were used to study vasospastic cerebral arteries removed at various times following SAH in monkeys to see which of the above processes best characterizes vasospasm in monkeys.

MATERIALS AND METHODS

Protocols

Nine female cynomolgus monkeys (*Macaca fascicularis*) weighing between 2.93 and 4.70 kg were randomized into 3 equal groups to be killed 7, 14, and 28 days after SAH (Figure 1). On day 0, animals underwent baseline cerebral angiography

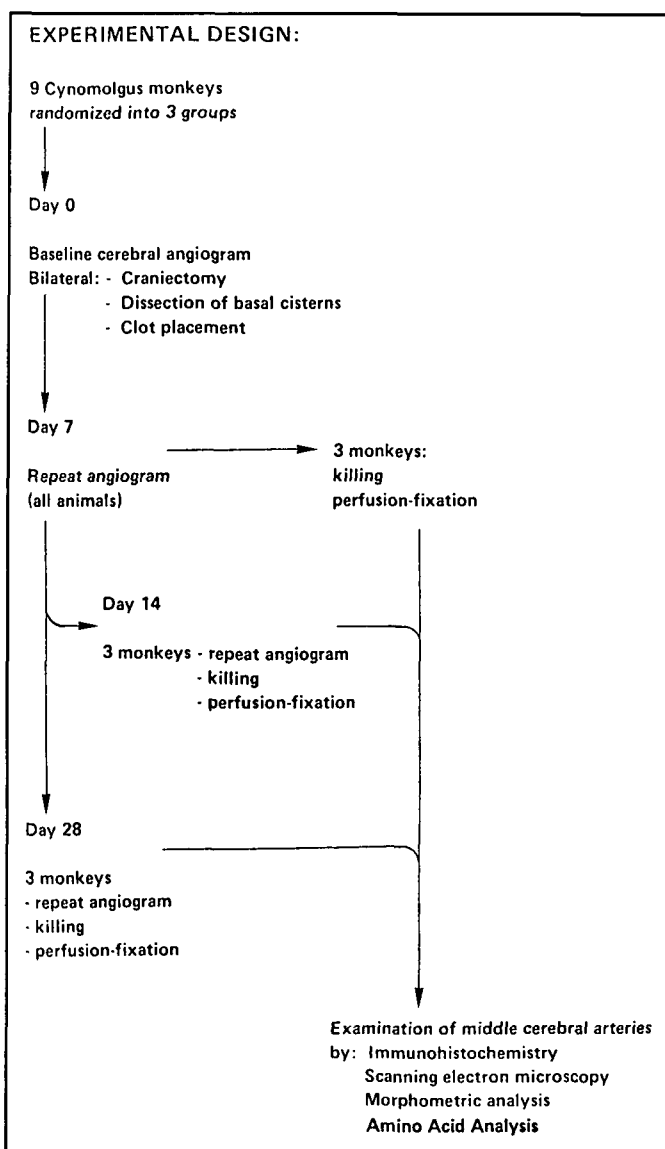


Figure 1 — Diagram of experimental protocol for immunofluorescence microscopy studies, computer-assisted image analysis, amino acid analysis, and scanning and transmission electron microscopy.

and bilateral subarachnoid placement of autologous blood clot to simulate SAH. Methods for baseline assessment, cerebral angiography, microsurgical opening of the basal cisterns, and induction of SAH have been published.¹⁰⁻¹² Angiography was repeated 7 days later in all animals. Animals killed on days 14 and 28 also had angiography repeated immediately prior to killing. Animals were killed by lethal injection of sodium pentobarbital followed by perfusion with fixative solution. Both MCAs and the basilar artery (BA) were removed and examined by immunofluorescence microscopy and amino acid analysis, BA serving as normal control artery.¹⁰ For immunofluorescence microscopy, sections of MCA and BA were exposed to primary antibodies directed against desmin, vimentin, α -actin, myosin, laminin, types I, III, IV, and V collagen, and fibronectin. For slides incubated with anti- α -actin antibodies, cells in tunica intima which showed immunoreactivity to α -actin were counted in 4 sections from each artery. Amino acid analysis was performed on a Beckman model 6300 high-performance amino acid analyzer (Beckman Instruments Inc., Palo Alto, California).

Middle cerebral arteries from animals killed 7 days after SAH were also studied by computer-assisted image analysis, SEM, and TEM. For image analysis, total vessel wall area, lumen area, and area of tunica media plus tunica intima were measured on arterial cross-sections¹¹. Normal MCAs and MCAs contracted *in vitro* with prostaglandin $F_{2\alpha}$ were studied by SEM after removal of the tunica adventitia with HCl¹².

Methods for statistical analysis have been published.¹⁰⁻¹² Protocols were approved by the Animal Ethics Review Committee of the University of Alberta. Guidelines of the Canadian Council on Animal Care for care and surgery of monkeys were adhered to.

RESULTS

Clinical Condition, Angiographic Vasospasm

No delayed-onset focal neurologic deficits were noted. Comparisons of angiograms taken on day 0 and on day 7 revealed significant reduction in MCA diameter for animals killed 7 days after SAH ($50\% \pm 16\%$, $p < 0.001$) and at day 7 in animals later killed on day 14 ($55\% \pm 8\%$, $p < 0.001$) and on day 28 ($54\% \pm 4\%$, $p < 0.001$) (Figures 2 to 4).¹⁰ By day 14, significant but mild MCA narrowing persisted ($16\% \pm 10\%$, $p < 0.05$). Animals killed on day 28 had no significant vasospasm.

Immunofluorescence Microscopy

Extracellular Matrix Proteins The patterns of immunoreactivity were similar for interstitial collagens (types I and III) and for type V collagen.¹⁰ There was no increase in these collagens in tunica media or adventitia at any time following SAH. In 4 of 6 MCAs from monkeys killed on day 28, intimal proliferation was observed over 25% to 50% of the arterial circumference. Circumferential intimal proliferation did not occur and these changes did not encroach significantly on the lumen. Types I, III, and V collagen, however, were deposited in thickened intima 28 days after SAH.

For type IV collagen, smooth muscle cells in tunica media were surrounded by a fine reticular pattern of fluorescence. In tunica intima, type IV collagen was observed around myointimal cells and beneath endothelial cells. Other than deposition around cells in areas of intimal proliferation seen in MCAs 28

days after SAH, there were no increases in type IV collagen immunoreactivity in tunica media or adventitia. Amino acid analysis showed no increase in hydroxyproline at any time after SAH.¹⁰

Fibronectin immunoreactivity was observed in the extracellular matrix of tunica media and tunica intima of normal BA (Figure 5). Seven days after SAH, there was a slight increase in tunica media fibronectin. By day 14, fibronectin in the media was increased more prominently. This increase had subsided somewhat by day 28 although fibronectin was observed in hyperplastic intima at this time. Immunoreactivity for laminin was present around smooth muscle and myointimal cells in BA and MCA at each time period after SAH as well as around the proliferated intimal cells 28 days after SAH.

Cytoskeletal Proteins In normal BA, immunoreactivity to α -actin, myosin, desmin, and vimentin was seen within smooth muscle cells in tunica media and in myointimal cells in tunica intima. There was a change in the pattern of staining due to muscle contraction during vasospasm but no increase in the

amount of staining was observed except at 28 days after SAH when cells in the excess intimal tissue consistently showed immunoreactivity to α -actin, myosin, desmin, and vimentin.

Scanning Electron Microscopy

Digestion of arteries with HCl removed adventitial connective tissue from cerebral arteries, exposing smooth muscle of tunica media.¹² In noncontracted BA, the outer surfaces of the smooth muscle cells was generally smooth and cells were long and tube-shaped with slightly tapering ends.

Contraction of monkey cerebral arteries with $\text{PGF}_{2\alpha}$ markedly altered the morphology of the smooth muscle cells. The cells developed widened areas alternating with narrow regions along their length. Over the widenings, the cell membrane exhibited numerous ridges and folds running transversely across the cells. Arteries exposed to subarachnoid blood clot for 7 days and with angiographically-confirmed vasospasm showed changes similar to those observed in vessels treated with $\text{PGF}_{2\alpha}$.

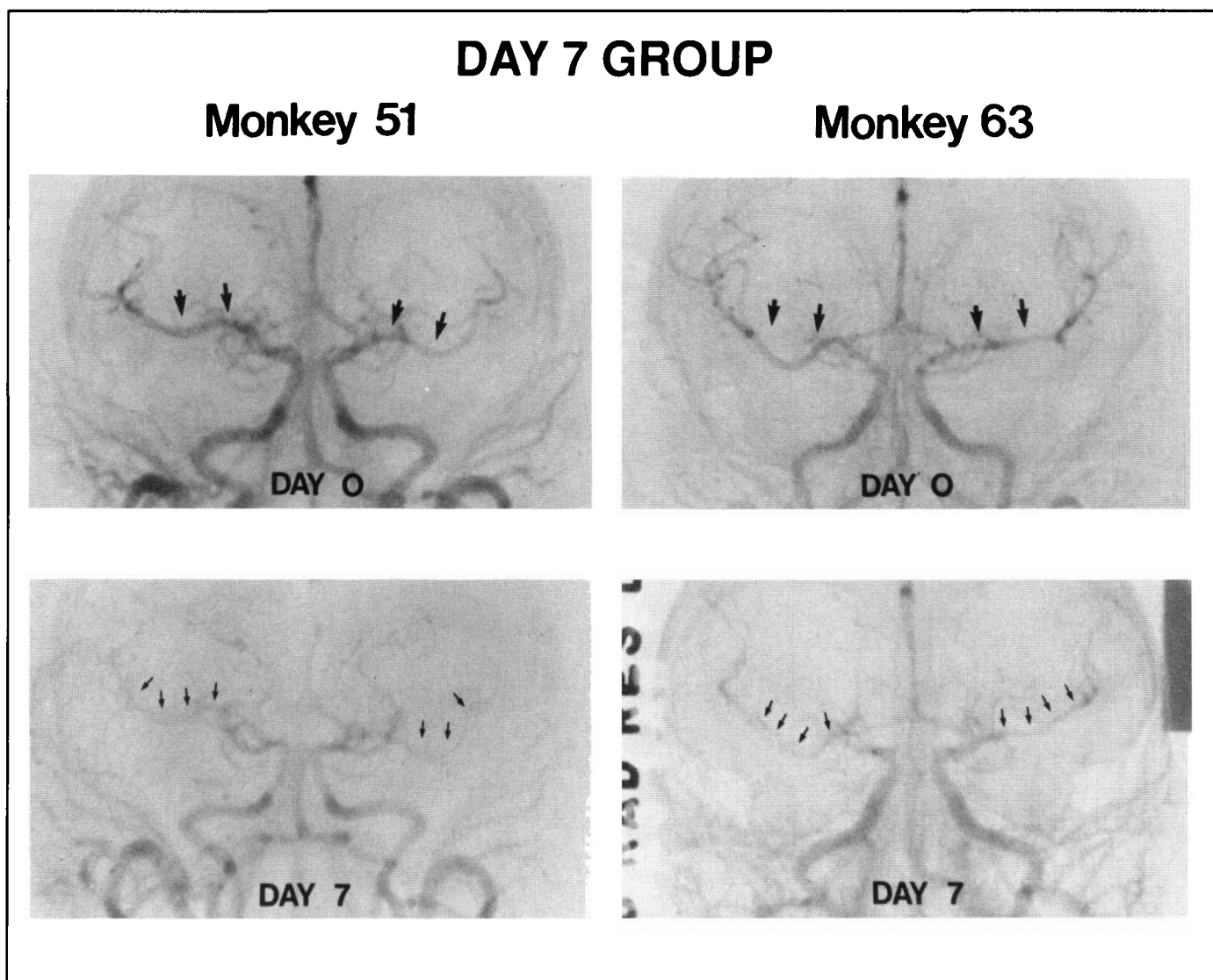


Figure 2 — Photographs of angiograms taken at baseline (day 0) and 7 days after subarachnoid hemorrhage in monkeys killed 7 days after subarachnoid hemorrhage. There is significant narrowing of both middle cerebral arteries on day 7 (arrows).

Computer-Assisted Image Analysis

Vessel diameter (determined both by angiography and by image analysis) and lumen area were significantly smaller ($p < 0.005$) in vasospastic MCAs as compared to normal MCAs

(Table 1).¹¹ Vasospasm was not associated, however, with a significant increase in total wall area or area of tunica media plus intima. Total wall area increased approximately 13% (not significant) and this increase occurred mainly in the tunica

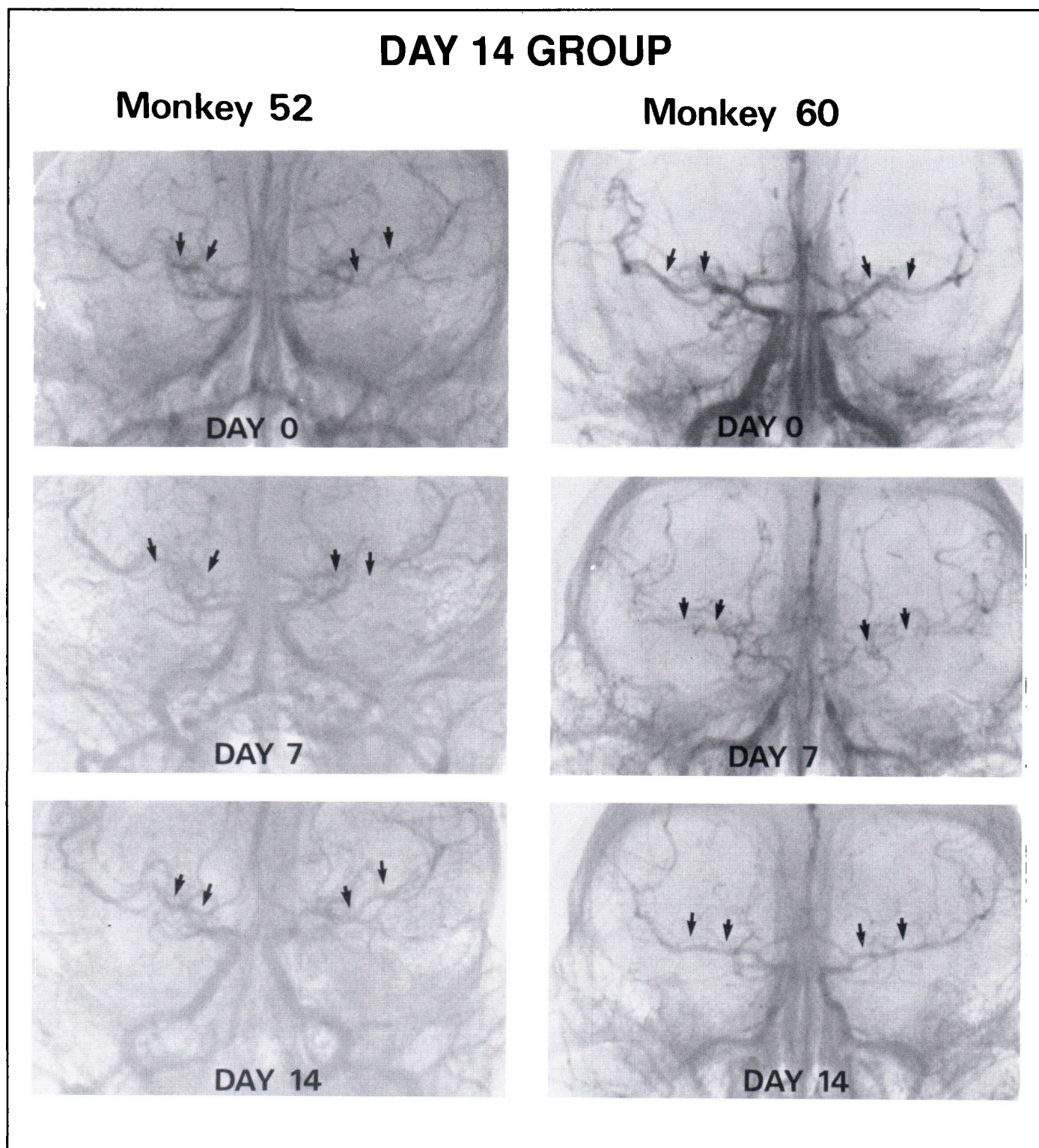


Figure 3 — Photographs of angiograms taken at baseline (day 0) and 7 and 14 days after subarachnoid hemorrhage in monkeys killed 14 days after subarachnoid hemorrhage. There is significant narrowing of both middle cerebral arteries on day 7 which is resolving by day 14 (arrows).

adventitia as there was no change in area of tunica media plus intima.

Pathologic Examination, Transmission Electron Microscopy

Animals killed on day 7 had residual clots in the subarach-

noid space. By day 14, small fragments of lightly-colored residual debris were present. On day 28, the subarachnoid space was grossly normal.

On TEM of MCAs 7 days after SAH, changes typical of vasoconstriction were noted, including increased radial thick-

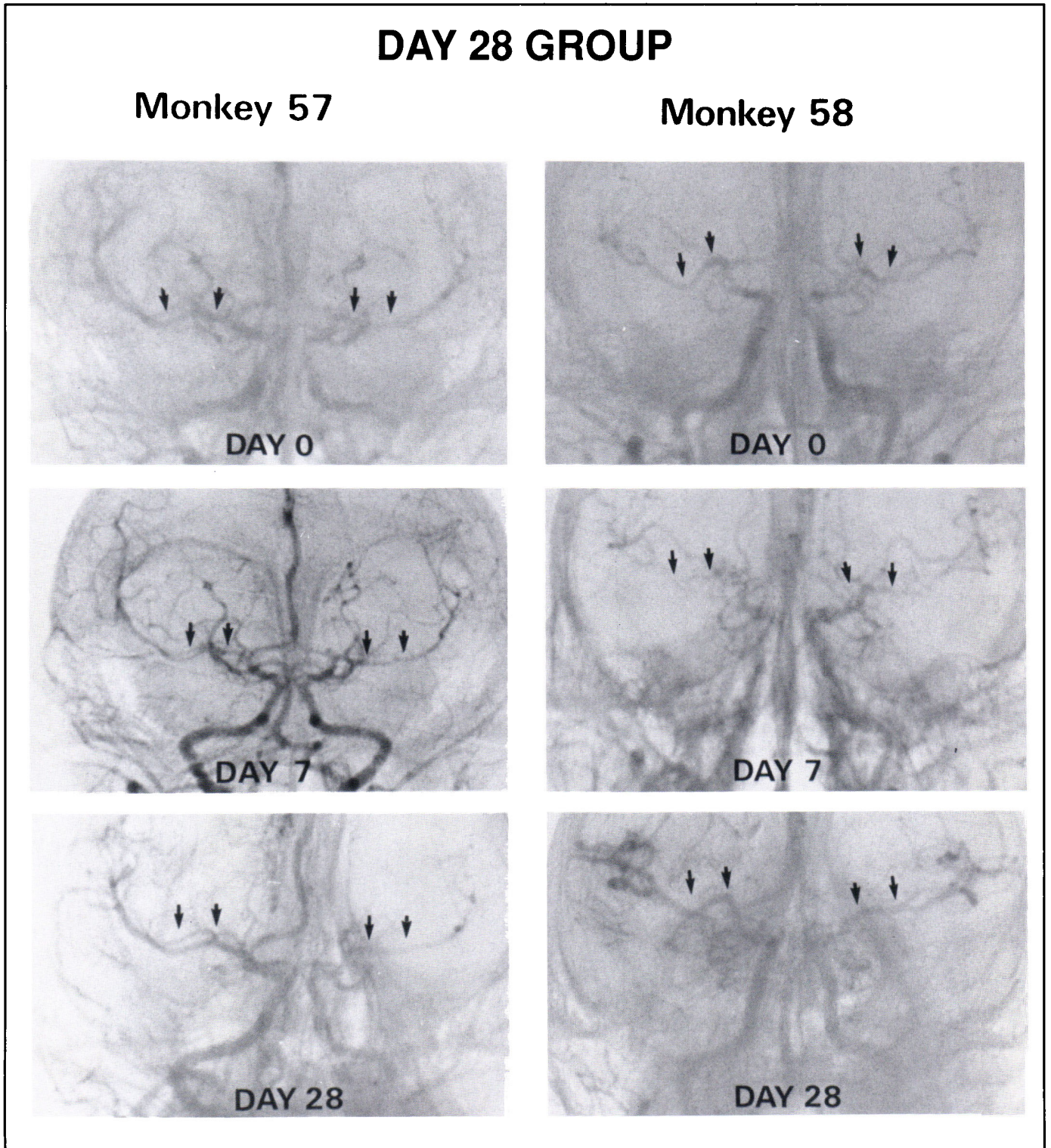


Figure 4 — Photographs of angiograms taken at baseline (day 0) and 7 and 28 days after subarachnoid hemorrhage in monkeys killed 28 days after subarachnoid hemorrhage. There is significant narrowing of both middle cerebral arteries on day 7 which has resolved by day 28 (arrows).

Table 1. Computer-Assisted Image (Morphometric) Analysis of Control Middle Cerebral Arteries and of Middle Cerebral Arteries 7 days after Subarachnoid Hemorrhage

Factor	Control MCA	SAH MCA
angiographic diameter (mm)	0.90 ± 0.04	0.45 ± 0.05 ^a
morphometric diameter (mm)	0.80 ± 0.09	0.40 ± 0.11 ^a
lumen area (mm ²)	0.60 ± 0.18	0.14 ± 0.09 ^a
vessel wall area (mm ²)	0.16 ± 0.02	0.18 ± 0.12
area of tunica intima plus tunica media (mm ²)	0.078 ± 0.008	0.075 ± 0.016

SAH, subarachnoid hemorrhage; MCA, middle cerebral artery

^avalues significantly less than values for control MCA ($p < 0.005$)

ness of the vessel wall, shortening and folding of smooth muscle cells, smooth muscle cell vacuolation, and convolution of the internal elastic lamina. In addition, dense body formation and necrosis of smooth muscle were occasionally present. The radial dimension of the intercellular space was increased during vasospasm. Proliferating myointimal cells were not observed. Inflammatory cells, macrophages, and degenerating blood clot were observed in tunica adventitia.

DISCUSSION

Theories of Mechanisms of Vasospasm

While advances have been made in treatment of cerebral vasospasm,^{13,14} little consensus exists concerning the mechanism of arterial narrowing. One theory is that vasospasm is primarily smooth muscle contraction.^{1,8} Vasospastic arteries,

FIBRONECTIN

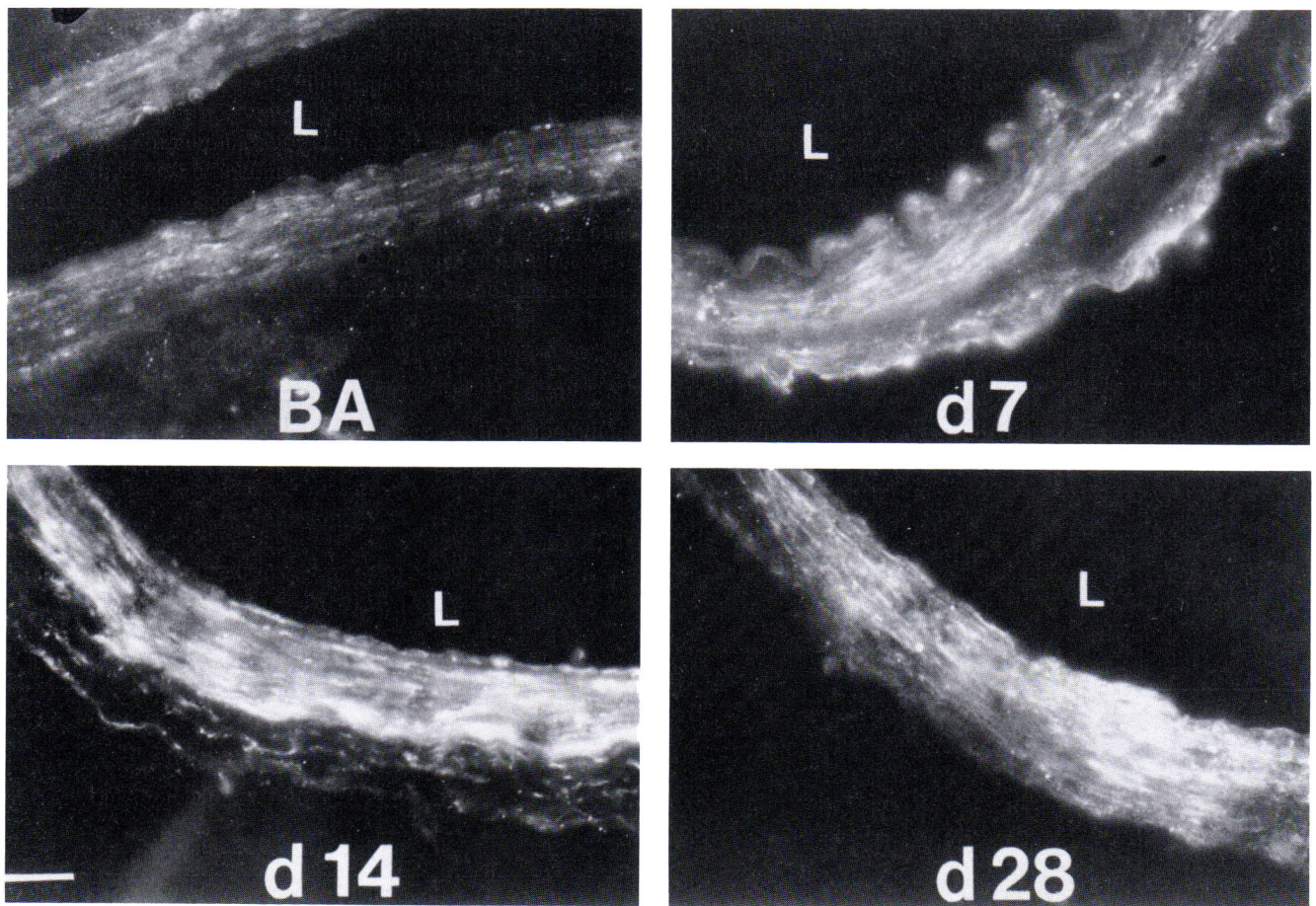


Figure 5 — Fluorescence photomicrographs of normal basilar artery (BA) and of middle cerebral artery cross-sections from animals killed 7 (D7), 14 (D14), and 28 (D28) days after subarachnoid hemorrhage and exposed to biotinylated anti-fibronectin antibodies and labelled secondarily with streptavidin-Texas Red. There is a slight increase in intensity of staining in tunica media on day 7. The increase is more obvious on day 14 and is subsiding 28 days after subarachnoid hemorrhage. L, lumen. Scale bar (= 100 μ m) applies to all 4 photomicrographs in the illustration [Reproduced from Macdonald RL, Weir BKA, Young JD, et al. Cytoskeletal and extracellular matrix proteins in cerebral arteries following subarachnoid hemorrhage in monkeys. *J Neurosurg* 1992; 76: 81-90 (reference 10) with permission].

however, develop pharmacologic and pathologic abnormalities which seem out of keeping with tonic smooth muscle contraction.^{3-5,8,9} Pathologic changes suggested to contribute to vasospasm include arterial wall inflammation and fibrosis, and intimal proliferation. Proponents of the vasoconstriction theory would suggest these changes are a result of smooth muscle contraction during vasospasm being prolonged and probably mediated by nonphysiologic mechanisms which cause cell damage. Contraction and cell damage may be induced by, for example, prolonged release of high concentrations of vasotoxic oxyhemoglobin from lysing subarachnoid erythrocytes.^{1,15}

Role of Inflammation

We have not investigated the role of inflammation in vasospasm. Anti-inflammatory drugs were found to be efficacious against vasospasm in dogs and in humans,¹⁶ although these drugs have other mechanisms of action which might improve outcome after SAH. Peterson and coworkers produced inflammation with resultant vasospasm of the BA in dogs by placing dextran and latex beads in the subarachnoid space,¹⁷ although other investigators have found these substances to be inert in cats.¹⁸ Immunosuppression with cyclosporine significantly diminished vasospasm following SAH in dogs¹⁹ and monkeys,²⁰ although the effect was minimal in the latter model.

Hoshi, et al., found immunoglobulin and complement deposits in cerebral arteries in patients dying from a variety of cerebrovascular diseases.²¹ While 74% of patients dying with vasospasm after SAH had deposits of these substances in their arteries, a similar number of arteries from patients dying of meningoencephalitis also had deposits, although it is unclear if they had vasospasm. Other investigators have been unable to find immunoglobulins within the walls of vasospastic human arteries.²²

These studies, as well as pathologic studies showing the presence of inflammation in vasospastic arteries,¹⁶ suggest inflammatory processes may contribute to vasospasm, although the mechanism of this effect remains unclear.

Role of Intimal Proliferation

Kassell, et al., theorized that lumen narrowing following SAH was due to arterial damage with proliferation of cells in the tunica intima, a process akin to that occurring in atherosclerotic plaques.⁶ Presumably, SAH could damage medial smooth muscle and induce a similar process.

If intimal proliferation caused lumen narrowing after SAH, then large increases in arterial wall cross-section area would be expected during vasospasm. The present study found vasospasm was not associated with a significant increase in arterial wall area. A small increase in total wall area during vasospasm was found to be confined to the tunica adventitia. Histopathologically, this was due to blood clot and inflammatory cells adherent to the adventitia after subarachnoid blood clot placement. Intimal proliferation was observed in our studies, although it developed after angiographic vasospasm resolved. These observations are consistent with studies of vasospastic human and animal arteries.^{9,10,23,24}

Development of intimal proliferation after vasospasm suggests that vasospasm, rather than the initial effects of SAH, damages the arterial wall. One might expect intimal prolifera-

tion to be of importance when severe vessel injury occurs at the time of SAH, as may occur with intramural hemorrhage at the site of aneurysm rupture.²⁵

Arterial Wall Fibrosis

The present investigations, using immunofluorescence microscopy and quantitative analysis of hydroxyproline, failed to find changes in arterial wall collagens until 28 days after SAH. Hydroxyproline is an amino acid residue which is found largely in collagens, although elastins contain small amounts. Intimal proliferation, which occurred 28 days after SAH, after arterial narrowing had resolved, did contain typical vessel wall collagens. Previous qualitative descriptions of light and electron microscopy of cerebral arteries after human and experimental SAH suggest there is increased collagen in tunica media of vasospastic arteries.^{1,7-9,25} Some investigators have failed to find fibrosis in arterial walls after SAH in humans and experimental animals.^{8,10,23,26}

When fibrosis has been detected, it generally develops late after SAH, usually following the period of worst myonecrosis.⁸ It has been suggested that collagen synthesis contributes to arterial narrowing after SAH.⁵ Since vasospasm resolves by 3 weeks after SAH, one would therefore also expect fibrosis to resolve. This has usually not been the case. In addition, pharmacologic abnormalities of cerebral arteries, such as wall stiffening and loss of compliance, have not been shown to resolve as vasospasm does, indicating that the relation between these changes, arterial fibrosis, and maintenance of arterial narrowing after SAH may be more complex than initially believed. It is also not known if arterial wall stiffening and persistence of vasospasm are due to modifications in the existing collagen matrix or in other extracellular matrix components which were not examined in this study. Yamamoto, et al., have reported that myofibroblasts appear in the arterial wall after SAH and that these cells can narrow arteries without undergoing contraction and without inducing fibrosis in the arterial wall.²⁷

Fibronectin, a normal extracellular matrix protein which has been shown to increase after balloon-dilation injury to arteries,²⁸ was observed to increase after SAH, and again, this increase followed the period of most severe arterial narrowing. The timing of this increase suggests SAH does not cause a primary vasculopathy leading to arterial narrowing but rather that subarachnoid clot liberates spasmogens which cause vasoconstriction.^{1,15} A secondary vessel wall response to injury occurs following this "vasospasm" probably as a result of smooth muscle damage incurred by contraction mediated by nonphysiologic pathways. Alternatively, increased fibronectin is consistent with the appearance of myofibroblasts within the arterial wall since these cells are associated with fibronectin in healing wounds.¹⁰

Role of Smooth Muscle and Smooth Muscle Contraction

The present scanning electron microscopy studies found the adventitial surface of relaxed vascular smooth muscle to be smooth with only mild and focal pleating of the cell membrane. Vasoconstriction is known to cause folding and corrugation of the cell membrane,²⁹ changes which are similar to those observed in $\text{PGF}_{2\alpha}$ -treated and vasospastic arteries of this study.

Although it is possible that the smooth muscle cell corrugation is secondary to a structural change in, for example, the extracellular matrix of the arterial wall, the similar appearance

of vasospastic cells to that of contracted cells suggests the change is due to contraction. Although smooth muscle can contract in a tonic fashion, the biochemical basis for prolonged and seemingly temporarily irreversible contraction in vasospasm is unknown. Matsui and colleagues reported that prolonged activation of signal transduction systems may form the basis of vasospastic smooth muscle contraction in dogs.^{30,31}

Significance of Other Pathological Changes

In addition to fibrosis, inflammation, and intimal proliferation, other pathologic changes have been reported in vasospastic arteries from humans and experimental animals.^{8,9} These include smooth muscle cell vacuolation and necrosis, fragmentation of the internal elastic lamina, endothelial cell vacuolation, disruption of intercellular tight junctions, and endothelial cell desquamation.^{1,8,9} Most of these changes have also been reported in arteries contracted *in vitro* with conventional vasoconstrictor drugs.^{7,8,32-36}

SUMMARY

The monkey model employed in these studies produces vasospasm which is similar to vasospasm following SAH in humans.^{1,37} The animals, however, do not commonly develop severe arterial narrowing and ischemic neurologic deficits which are seen in humans. Immunofluorescence microscopy, amino acid analysis, and TEM show notable increases in arterial wall collagen or substantial alterations in smooth muscle cytoskeletal proteins do not occur during vasospasm. Image-analysis confirms significant proliferation of cells or of extracellular material does not occur in arterial walls during vasospasm. Lumen narrowing, therefore, seems due to smooth muscle contraction. Direct visualization of smooth muscle cells by SEM and study by TEM confirms that smooth muscle cells are contracted 7 days after SAH, when vasospasm is most severe. Fibronectin deposition is most prominent 14 days after SAH, when vasospasm is resolving. Intimal proliferation, which contains α -actin positive cells and vessel wall collagens, also develops subsequent to vasospasm. These results suggest that pathologic changes are a response of the arterial wall to injury incurred during prolonged vasoconstriction which characterizes vasospasm. Pathologic changes themselves may not contribute to arterial narrowing, at least in monkeys. These investigations do not rule out the possibility that alteration in other components of the extracellular matrix, or in cross-linking of components studied in this report, could contribute to vasospasm. A role for myofibroblasts also is not inconsistent with the present findings.²⁷ We suspect, however, that vasospasm is temporarily irreversible contraction in vascular smooth muscle. This mechanism may also cause the ultrastructural and pharmacologic abnormalities in vasospastic arteries, although the biochemical basis of the contraction is unknown.

ACKNOWLEDGEMENTS

Presented in part at the XXVIth Canadian Congress of Neurological Sciences in Halifax, June, 1991. The work in this manuscript has been published previously in references 10, 11 and 12.

We thank Dr. A. Acheson and Eileen Reklow for assistance with immunofluorescence microscopy, Mike Natriss, Wing Tsang, and Rajan George for help with amino acid analysis, and Sam Motyko, Karen Popowich, and Peter Jeremy for illustrations.

Dr. Macdonald is a fellow of the Alberta Heritage Foundation for Medical Research. This study was supported by grants to Dr. Weir from the National Institutes of Health (5R01 NS2594 6-03) and the Medical Research Council of Canada (MA 9158).

REFERENCES

1. Weir B. Aneurysms Affecting the Nervous System. Baltimore: Williams and Wilkins, 1987.
2. Wilkins RH. Attempts at prevention or treatment of intracranial arterial spasm. An update. *Neurosurgery* 1986;18: 808-825.
3. Kim P, Sundt TM Jr, Vanhoutte PM. Alterations of mechanical properties in canine basilar arteries after subarachnoid hemorrhage. *J Neurosurg* 1989; 71: 430-436.
4. Kanamaru K, Weir BKA, Findlay JM, et al. Pharmacologic studies on relaxation of spastic primate cerebral arteries in subarachnoid hemorrhage. *J Neurosurg* 1989; 71: 909-915.
5. Vorkapic P, Bevan RD, Bevan JA. Pharmacologic irreversible narrowing in chronic cerebrovasospasm in rabbits is associated with functional damage. *Stroke* 1990; 21: 1478-1484.
6. Kassell NF, Peerless SJ, Drake CG. Cerebral vasospasm: acute proliferative vasculopathy? I. Hypothesis. *In: Wilkins RH, ed. Cerebral Arterial Spasm. Baltimore: Williams and Wilkins, 1980: 85-87.*
7. Yoshioka J, Yabuno N, Morooka H, et al. Morphological changes in cerebral vessels in experimental cerebral vasospasm. *Neurol Med Chir (Tokyo)* 1981; 21: 211-219.
8. Findlay JM, Weir BKA, Kanamaru K, et al. Arterial wall changes in cerebral vasospasm. *Neurosurgery* 1980; 25: 736-746.
9. Mayberg MR, Okada T, Bark DH. Morphologic changes in cerebral arteries after subarachnoid hemorrhage. *In: Winn HR, Mayberg MR, eds. Neurosurgery Clinics of North America. Vol 1: Cerebral Vasospasm. Philadelphia: W.B. Saunders Co., 1990: 417-432.*
10. Macdonald RL, Weir BKA, Young JD, et al. Cytoskeletal and extracellular matrix proteins in cerebral arteries following subarachnoid hemorrhage in monkeys. *J Neurosurg* 1992; 76: 81-90.
11. Macdonald RL, Weir BKA, Grace MGA, et al. Morphometric analysis of monkey cerebral arteries exposed *in vivo* to whole blood, oxyhemoglobin, methemoglobin, and bilirubin. *Blood Vessels* 1991; 28: 498-510.
12. Macdonald RL, Weir BKA, Chen MH, et al. Scanning electron microscopy of normal and vasospastic monkey cerebrovascular smooth muscle cells. *Neurosurgery* 1991; 29: 544-550.
13. Ohman J, Servo A, Heiskanen O. Effect of intrathecal fibrinolytic therapy on clot lysis and vasospasm in patients with aneurysmal subarachnoid hemorrhage. *J Neurosurg* 1991; 75: 197-201.
14. Kassell NF, Haley EC, Torner JC, et al. Nicardipine and angiographic vasospasm. *J Neurosurg* 1991; 74: 341A (abstract).
15. Macdonald RL, Weir BKA, Grace M, et al. Etiology of cerebral vasospasm in primates. *J Neurosurg* 1991; 75: 415-424.
16. Chyatte D. Anti-inflammatory agents and cerebral vasospasm. *In: Winn HR, Mayberg MR, eds. Neurosurgery Clinics of North America. Vol 1: Cerebral Vasospasm. Philadelphia: W.B. Saunders Co., 1990: 433-450.*
17. Peterson J, Kwun BD, Nishizawa S, et al. Immunoreactivity, immunosuppression, and cerebral vasospasm following SAH. *Stroke* 1988; 19: 130 (abstract).
18. Duff TA, Louie J, Feilbach JA, et al. Erythrocytes are essential for development of cerebral vasculopathy resulting from subarachnoid hemorrhage in cats. *Stroke* 1988; 19: 68-72.
19. Peterson J, Nishizawa S, Hackett J, et al. Cyclosporine A reduces cerebral vasospasm after subarachnoid hemorrhage in dogs. *Stroke* 1990; 21: 133-137.
20. Handa Y, Hayashi M, Takeuchi H, et al. Effect of cyclosporine on the development of cerebral vasospasm in a primate model. *Neurosurgery* 1991; 28: 380-386.
21. Hoshi T, Shimizu T, Kito K, et al. Immunological study of late cerebral vasospasm in subarachnoid hemorrhage. Detection of immunoglobulins, C3, and fibrinogen in cerebral arterial walls by immunofluorescence method. *Neurol Med Chir (Tokyo)* 1984; 24: 647-654.

22. Smith RR, Clower BR, Honma Y, et al. The constrictive angiopathy of subarachnoid hemorrhage: an immunopathological approach. *In*: Wilkins RH, ed. Cerebral Vasospasm. New York: Raven Press, 1988: 247-252.
23. Eldevik OP, Kristiansen K, Torvik A. Subarachnoid hemorrhage and cerebrovascular spasm. Morphological study of intracranial arteries based on animal experiments and human autopsies. *J Neurosurg* 1981; 55: 869-876.
24. Mayberg MR, Okada T, Bark DH. The significance of morphological changes in cerebral arteries after subarachnoid hemorrhage. *J Neurosurg* 1990; 72: 626-633.
25. Clower BR, Smith RR, Haining JL, et al. Constrictive endarteropathy following experimental subarachnoid hemorrhage. *Stroke* 1981; 12: 501-508.
26. Pickard JD, Graham DI, Matear E, et al. Ultrastructure of cerebral arteries following experimental subarachnoid haemorrhage. *J Neurol Neurosurg Psychiatry* 1985; 48: 256-262.
27. Yamamoto Y, Smith RR, Bernanke DH. Accelerated nonmuscle contraction after subarachnoid hemorrhage: culture and characterization of myofibroblasts from human cerebral arteries in vasospasm. *Neurosurgery* 1992; 30: 337-345.
28. Jensen BA, Holund B, Clemmensen I. Demonstration of fibronectin in normal and injured aorta by indirect immunoperoxidase technique. *Histochemistry* 1983; 77: 395-403.
29. Fujiwara T, Uehara Y. Scanning electron microscopical study of vascular smooth muscle cells in the mesenteric vessels of the monkey: arterial smooth muscle cells. *Biomed Res* 1982; 3: 649-658.
30. Matsui T, Takuwa Y, Johshita H, et al. Possible role of protein kinase C-dependent smooth muscle contraction in the pathogenesis of chronic cerebral vasospasm. *J Cereb Blood Flow Metab* 1991; 11: 143-149.
31. Matsui T, Johshita H, Asano T. The state of protein kinase C activation in the arterial segment excised from the spastic basilar artery. *In*: Sano K, Takakura K, Kassell NF, Sasaki T, eds. Cerebral Vasospasm. Tokyo, University of Tokyo Press, 1990: 124-126.
32. Joris I, Majno G. Cell-to-cell herniae in the arterial wall. I. The pathogenesis of vacuoles in the normal media. *Am J Pathol* 1977; 87: 375-397.
33. Van Citters RL, Wagner BM, Rushmer RF. Architecture of small arteries during vasoconstriction. *Circ Res* 1962; 10: 668-675.
34. Joris I, Majno G. Endothelial changes induced by arterial spasm. *Am J Pathol* 1981; 102: 346-358.
35. Alksne JF, Greenhoot JH. Experimental catecholamine-induced chronic cerebral vasospasm. Myonecrosis in vessel wall. *J Neurosurg* 1974; 41: 440-445.
36. Ohta T, Kajikawa H, Funatsu N, et al. Cerebral vasospasm and its relaxation responses to vasodilators: pathological study of severe prolonged vasospasm. *In*: Wilkins RH, ed. Cerebral Arterial Spasm. Baltimore: Williams and Wilkins, 1980: 132-139.
37. Nosko M, Weir B, Krueger C, et al. Nimodipine and chronic vasospasm in monkeys: Part 1. Clinical and radiological findings. *Neurosurgery* 1985; 16: 129-136.