

Original Article

*T. Bai and Q. Wei equally contributed to this work.

Cite this article: Bai T, Wei Q, Xie W, Wang A, Wang J, Ji Gong-J, Wang K, Tian Y (2019). Hippocampal-subregion functional alterations associated with antidepressant effects and cognitive impairments of electroconvulsive therapy. *Psychological Medicine* **49**, 1357–1364. <https://doi.org/10.1017/S0033291718002684>

Received: 13 December 2017

Revised: 22 August 2018

Accepted: 22 August 2018

First published online: 19 September 2018

Key words:

Depression; electroconvulsive therapy; fMRI; functional connectivity; hippocampal subregions

Authors for correspondence:

Yanghua Tian, Kai Wang,

E-mail: ayfytyh@126.com, wangkai1964@126.com

com

Hippocampal-subregion functional alterations associated with antidepressant effects and cognitive impairments of electroconvulsive therapy

Tongjian Bai^{1,4,5,*}, Qiang Wei^{1,4,5,*}, Wen Xie², Anzhen Wang², Jiaojian Wang³, Gong-Jun Ji^{4,5,6}, Kai Wang^{1,4,5,6} and Yanghua Tian^{1,4,5}

¹Department of Neurology, the First Affiliated Hospital of Anhui Medical University, Hefei, 230022, China; ²Anhui Mental Health Center, Hefei, Anhui Province, China; ³Key Laboratory for NeuroInformation of the Ministry of Education, School of Life Science and Technology, University of Electronic Science and Technology of China, Chengdu 625014, China; ⁴Collaborative Innovation Center of Neuropsychiatric Disorders and Mental Health, Hefei 230022, China; ⁵Anhui Province Key Laboratory of Cognition and Neuropsychiatric Disorders, Hefei 230022, China and ⁶Department of Medical Psychology, Chaohu Clinical Medical College, Anhui Medical University, Hefei, China

Abstract

Background. Electroconvulsive therapy (ECT), an effective antidepressive treatment, is frequently accompanied by cognitive impairment (predominantly memory), usually transient and self-limited. The hippocampus is a key region involved in memory and emotion processing, and in particular, the anterior-posterior hippocampal subregions has been shown to be associated with emotion and memory. However, less is known about the relationship between hippocampal-subregion alterations following ECT and antidepressant effects or cognitive impairments.

Methods. Resting-state functional connectivity (RSFC) based on the seeds of hippocampal subregions were investigated in 45 pre- and post-ECT depressed patients. Structural connectivity between hippocampal subregions and corresponding functionally abnormal regions was also conducted using probabilistic tractography. Antidepressant effects and cognitive impairments were measured by the Hamilton Depressive Rating Scale (HDRS) and the Category Verbal Fluency Test (CVFT), respectively. Their relationships with hippocampal-subregions alterations were examined.

Results. After ECT, patients showed increased RSFC in the hippocampal emotional subregion (HIPE) with the left middle occipital gyrus (LMOG) and right medial temporal gyrus (RMTG). Decreased HDRS was associated with increased HIPE-RMTG RSFC ($r = -0.316$, $p = 0.035$) significantly and increased HIPE-LMOG RSFC at trend level ($r = -0.283$, $p = 0.060$). In contrast, the hippocampal cognitive subregion showed decreased RSFC with the bilateral angular gyrus, and was correlated with decreased CVFT ($r = 0.418$, $p = 0.015$ for left; $r = 0.356$, $p = 0.042$ for right). No significant changes were found in structural connectivity.

Conclusion. The hippocampal-subregions functional alterations may be specially associated with the antidepressant and cognitive effects of ECT.

Introduction

Electroconvulsive therapy (ECT) is considered as an effective treatment for depression with rapid remission (Fink, 2000; Spaans *et al.*, 2015). ECT has been clinically applied for decades with well documented positive benefits. Prior evidence also showed that ECT would cause cognitive impairment, especially retrograde and anterograde memory deficits (Rami-Gonzalez *et al.*, 2001). These neurocognitive side-effects, subsequently, have generally resulted in negative attitudes regarding ECT among patients with depression who may otherwise benefit from the treatment (Chakrabarti *et al.*, 2010), although research has suggested that this is only short-lived and self-limited side effects (Semkovska and McLoughlin, 2010). The neural mechanism underlying the antidepressive effect and memory impairment associated with ECT, however, remains unclear (Jiang *et al.*, 2016; Nobler and Sackeim, 2008). A better understanding of these processes is needed to fine-tune ECT in order to induce less negative side effects and thus enhance the positive attitudes among patients who may benefit from it.

It is well established that the hippocampus is one of the most vital brain region involved in memory processes and is responsible for regulating emotion (Femenia *et al.*, 2012; Goosens, 2011). The aberrance of hippocampal function and structure has been implicated in emotional disorders, such as depression (Cao *et al.*, 2012; McKinnon *et al.*, 2009; Small *et al.*, 2011; Tahmasian *et al.*, 2013). It is worth noting that, both abnormal hippocampal function and structure could be normalized by effective antidepressant treatments, such as ECT (Abbott

© Cambridge University Press 2018. This is an Open Access article, distributed under the terms of the Creative Commons Attribution-NonCommercial-NoDerivatives licence (<http://creativecommons.org/licenses/by-nc-nd/4.0/>), which permits non-commercial re-use, distribution, and reproduction in any medium, provided the original work is unaltered and is properly cited. The written permission of Cambridge University Press must be obtained for commercial re-use or in order to create a derivative work.

et al., 2014; Dukart *et al.*, 2014; Joshi *et al.*, 2016). Although few human studies have addressed the neural underpinnings of ECT-induced memory impairment, animal model has suggested that it is closely related to altered synaptic plasticity in the hippocampus (Reid and Stewart, 1997). Taken together, these findings may indicate that the hippocampus plays a significant role in both the antidepressant effect and cognitive impairment associated with ECT.

The hippocampus has multiple subregions corresponding to different functions, including the processes of memory consolidation and emotional regulation. The hippocampus is divided into two subregions, the ventral and dorsal part in rodents, which correspond to the anterior and posterior hippocampus, respectively, in humans (Fanselow and Dong, 2010; Poppenk *et al.*, 2013). In humans, the posterior hippocampus (dorsal hippocampus in rodents) is primarily involved in memory function through structural connections with memory-associated regions (Buckner *et al.*, 2008; Cenquizca and Swanson, 2007). In contrast, the anterior hippocampus (the ventral hippocampus in rodents) is primarily involved in the process of regulating emotion through connections with emotion-associated structures (Cenquizca and Swanson, 2007; Parent *et al.*, 2010; Roberts *et al.*, 2007). Consistently, based on the task-related functional magnetic resonance imaging (fMRI) data from the BrainMap database, the left hippocampus is segmented into the anterior-most emotional cluster, the middle cognitive cluster and the posterior-most perceptual cluster via the method of coactivation-based parcellation (Robinson *et al.*, 2015). Indeed, dysfunction of the anterior hippocampus has been implicated in various mood disorders (Abdallah *et al.*, 2017; Chen and Etkin, 2013; Finkelmeyer *et al.*, 2016) and while the posterior hippocampus is closely linked with memory performance in humans (Ludwig *et al.*, 2008; Poppenk and Moscovitch, 2011). In addition, both animal and human studies reported that antidepressants specifically increased anterior hippocampal neurogenesis (Boldrini *et al.*, 2009; Santarelli *et al.*, 2003) that is crucial for the success of antidepressant treatments (Sahay and Hen, 2007).

According to studies supporting diverse traits of hippocampal subregions and ECT-induced alterations in memory and emotion processes, we proposed that anterior-hippocampal alterations would be associated with the antidepressant effects of ECT, in contrary, the alterations in the posterior-hippocampus would be associated with cognitive impairments. In the current study, hippocampal alterations were examined with resting-state functional connectivity (RSFC) based on the seed of hippocampal subregions and also by structural connectivity using probabilistic tractography to analyze interactions between functionally abnormal regions.

Materials and methods

Participants

Patients were recruited from the Anhui Mental Health Center, Hefei, China and diagnosed with depression according to the Diagnostic and Statistical Manual of Mental Disorders, Fourth Edition. Patients were excluded due to the following exclusion criteria: (1) a history of ECT in the last 3 months; (2) age over 65 years; (3) diagnosed with substance misuse, schizoaffective disorder or schizophrenia; (4) past or current neurological illness; (5) other contraindications of MRI scan and ECT administration. A total of 53 patients completed twice MRI scans and one course of ECT. This study was approved by the Anhui Medical

University Ethics Committee, and written informed consent was obtained from all patients.

Clinical evaluation

Patients received clinical assessments and MRI scanning both before the first ECT administration and after the last ECT administration (72 h apart). Clinical symptoms were assessed by the 17-item Hamilton Depression Rating Scale (HDRS) and cognitive function was evaluated using the verbal fluency test (CVFT). During the CVFT, participants were required to say as many words as possible describing an animal and a vegetable within 1 min, respectively. One point was scored when participants gave a correct term for either the correct description of an animal or a vegetable. The total score was used as memory performance for further analysis.

ECT procedure

ECT procedures were conducted as previously described (Bai *et al.*, 2017). Briefly, pre-treatment examinations were conducted on all patients to exclude contraindications of ECT and anesthesia. Patients fasted for 8–12 h before each ECT session. ECT was administered using a Thymatron System IVY Integrated ECT Instrument (Somatics, Inc, Lake Bluff, IL) located in the Anhui Mental Health Center. All patients received ECT with bifrontal electrode placement. Six to 12 sessions were administered three times per week. The initial percent energy was set according to the age-based method. During each ECT procedure, patients were under anesthesia with propofol, as well as the secondary medications succinylcholine and atropine.

MRI data acquisition

Resting-state and structural images of patients were acquired at the First Affiliated Hospital of Anhui Medical University. Patients were instructed to keep their eyes closed and move and think as little as possible during the MRI scan. Resting-state MRI scans were conducted under a 3.0 T MRI scanner (Signa HDxt 3.0 T, GE Healthcare, Buckinghamshire, UK) composed of 240 echo-planar imaging volumes with the following parameters: TR = 2000 ms; TE = 22.5 ms; flip angle = 30°; matrix size = 64 × 64, field of view = 220 × 220 mm; slice thickness = 4 mm; 33 continuous slices (one voxel = 3.4 × 3.4 × 4.6 mm). Total acquisition of resting-state MRI lasted 8 min. A T1-weighted anatomical image with 188 slices was also acquired for each patient to further elucidate and discard gross radiological alterations. (TR = 8.676 ms; TE = 3.184 ms; inversion time = 800 ms; flip angle = 8°; field of view = 256 × 256 mm²; slice thickness = 1 mm; voxel size = 1 × 1 × 1 mm³). Diffusion tensor imaging (DTI) data were collected using spin echo single-shot echo planar imaging sequencing (repetition time (TR)/echo time (TE) = 11 000 ms/72 ms; matrix, 256 × 256; field of view = 256 × 256 mm²; 50 contiguous axial slices with slice thickness of 3 mm) with diffusion-sensitizing gradient orientations along 64 non-collinear directions ($b = 1000 \text{ s/mm}^2$) and using three scans without diffusion weighting ($b = 0 \text{ s/mm}^2$, b_0).

Functional data preprocessing

Resting-state fMRI data were preprocessed with a Microsoft Windows platform using the Data Processing Assistant for Resting-State Functional MR Imaging toolkit (DPARSF)

(Chao-Gan and Yu-Feng, 2010), a software package based on Statistical Parametric Mapping software (SPM8; www.fil.ion.ucl.ac.uk/spm) and Resting-State Functional MR Imaging Toolkit (REST; <http://www.restfmri.net>) (Song *et al.*, 2011). The first 10 volumes were discarded to exclude the influence of unstable longitudinal magnetization. The remaining volumes were processed using the following steps: slice timing correction; realignment; normalizing the structural T1 image to the Montreal Neurological Institute (MNI) space using the Diffeomorphic Anatomical Registration Through Exponentiated Lie algebra (DARTEL) and transferring the functional images to the MNI space based on the transformation matrix; nuisance regressors using linear detrending; 24 Friston motion parameters; white matter high signal; and cerebrospinal fluid and global signals as regressors. Subsequently, the fMRI data were smoothed with a full width at a half maximum of 4 mm. Then, the data were filtered with a temporal band-pass of 0.01–0.1 Hz. Finally, due to excessive motion (>3 mm in any of the x , y , or z directions or $>3.0^\circ$ in any angular motion), eight patients were ultimately excluded and 45 patients were included for further analysis.

The definition of left hippocampal subregions

The hippocampal subregions were referred to a recent data-driven characterization that revealed a subspecialization in the hippocampus using coactivation-based parcellation (Robinson *et al.*, 2015). Taken the ambiguity of right hippocampal segmentation into account in our study, only the left hippocampal subregions were selected as regions of interest (ROI). The left hippocampus was segmented into three subregions: the anterior-most subregion, involved in emotional processes (HIPE); the middle subregion, involved in cognitive processes (HIPc); and the most posterior subregion, involved in perceptual function. Noteworthy, the overlapping voxels between adjacent clusters (Fig. 1a) that may influence subsequent analysis were removed and the remaining clusters were selected as ROIs (Fig. 1b).

RSFC

The RSFC was calculated using DPARSF software. For each individual, Pearson's correlation coefficients were computed between the mean time series of each ROI and the time series of each voxel in the remainder of the brain. To improve normality, correlation coefficients were converted to z -values using Fisher's r -to- z transformation and results were displayed using RSFC maps for each participant. Afterward, paired t tests were used to quantitatively compare the differences in RSFC of each ROI between pre- and post-ECT within the whole-brain mask using statistical parametric mapping. Statistical maps were then thresholded using a cluster-level family-wise error-corrected threshold of $p < 0.05$ (cluster-forming threshold at voxel-level $p < 0.001$) (Woo *et al.*, 2014) based on the SPM8 software and *xjView* toolbox (<http://www.alivelearn.net/xjview>). The BrainNet Viewer package was used to map the remaining regions onto cortical surfaces (Xia *et al.*, 2013).

Structural connectivity

DTI data of 38 patients were collected and performed in the analysis of structural connectivity. Structural connectivity was estimated for two paired regions, the left hippocampal emotional region and the left middle occipital gyrus (LMOG), as well as

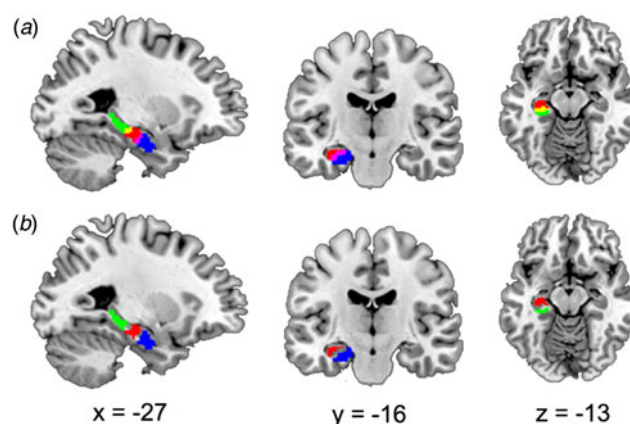


Fig. 1. Sagittal, coronal, and axial views displaying the ROI. (a) Hippocampal subregions were derived from a recent data-driven study that revealed a subspecialization in the hippocampus using coactivation-based parcellation. The left hippocampus was segmented into three subregions, the HIPE (blue), the HIPc (red), and the HIPp (green). There were overlapping areas between HIPE and HIPc (the magenta area) and overlapping areas between HIPc and HIPp (yellow). (b) After excluding overlapping areas, the remaining regions HIPE (blue), HIPc (red) and HIPp (green), were used as ROI for further analysis. ROI, region of interest; HIPE, hippocampal emotional region; HIPc, hippocampal cognitive region; HIPp, hippocampal perceptual region. These ROIs were based on the public results from the work of Robinson *et al.* (2015) (<http://anima.fz-juelich.de/>).

the left hippocampal cognitive region and the left angular gyrus, as they were ipsilateral and their respective dysfunctional connectivities were associated with clinical changes (see below). DTI data were processed using the fMRI of the Brain Software Library (FSL) (<http://fsl.fmrib.ox.ac.uk/fsl/fslwiki/FSL>). First, each diffusion-weighted volume was affine-aligned to its corresponding unweighted B0 image ($b = 0$ s/mm²) to correct for potential motion artifacts and eddy-current distortions. Second, fractional anisotropy was calculated by fitting the diffusion tensor model at each voxel. Finally, the probabilistic diffusion model (BED-POSTX) was used to calculate the probability distributions of fiber direction at each voxel in each individual diffusion space.

To obtain the functional ROIs in individual diffusion spaces, three steps were performed using FSL software: (a) coregister T1 to B0 image, (b) normalize T1 to the MNI space and get the inverse matrix, and (c) apply the inverse matrix to functional ROIs in the MNI space. Probabilistic tractography was then applied by sampling 5000 streamline fibers per voxel in the seed ROI. Only samples that reached cortical ROIs were retained. The properties of hippocampo-cortical fibers between the pre- and post-ECT groups were then compared at a spectrum of different thresholds (0.01, 0.05, 0.1, 0.15 of the maximal value in the tractography map) using paired t tests (threshold at $p < 0.05$). To illustrate the distribution of the hippocampo-cortical fibers across subjects, the tracts were normalized to the MNI space by the matrix generated by T1 normalization. Finally, all tracts were converted to a binary mask (threshold: 0.01 of the maximal value in the tractography map) and added together to produce a population-based probabilistic map (Ji *et al.*, 2014).

Correlations analysis

Spearman's correlation was performed to explore associations between the altered hippocampal connectivity (functional and structural connectivity) and clinical changes (HDRS and CVFT). Significance was determined at $p < 0.05$ (two-tailed), with no

correction. Depressive symptoms of all patients ($n = 45$) were assessed with HDRS, only 34 patients completed the CVFT. One patient was excluded as an outlier that exceeded three standard deviations of the mean of CVFT. Finally, 45 patients were included for subsequent correlation analysis on the changes of HDRS, and 33 patients were included for correlation analysis on the changes of CVFT.

Results

Demographic and clinical characteristic

Forty-five depressed patients with an average age 38.02 ± 11.65 (17 males) were included for the final analyses. Patients showed significant improvements in depressive symptoms after a series of ECT, as demonstrated by a HDRS of 22.67 ± 4.55 (pre-ECT) compared with a mean of 5.16 ± 4.49 (post-ECT) ($t = 19.27$, $p < 0.001$). There were also significant differences in CVFT between pre-ECT and post-ECT patients (29.41 ± 9.55 for pre-ECT, 22.35 ± 8.10 for post-ECT, $t = 4.08$, $p < 0.001$).

Pre- and post-ECT contrasts with RSFC of hippocampal subregions

Increased HIPE connectivity with three brain areas after ECT was found: the right medial temporal gyrus (RMTG), the LMOG, and the left putamen (Fig. 2a, Table 1). Changes in HDRS were associated with changes in HIPE-LMOG RSFC at the trend level ($r = -0.283$, $p = 0.060$) and changes in HIPE-RMTG RSFC ($r = -0.316$, $p = 0.035$) (Fig. 2b and c). Decreased HIPc connectivity with two clusters after ECT was found: the right angular gyrus (RAG) and the left angular gyrus (LAG). There were two clusters that showed increased connectivity with HIPc after ECT: the left postcentral gyrus/inferior parietal lobule and the medial frontal gyrus (Fig. 3a, Table 1). A significant relationship was also found between the change in CVFT and the change in HIPc-LAG RSFC ($r = 0.418$, $p = 0.015$), as well as HIPc-RAG RSFC ($r = 0.356$, $p = 0.042$) (Fig. 3b and c). There was no significant relationship between the change of function in HIPE and the change of CVFT, or between the change of function in HIPc and the change in HDRS. No altered connectivity was identified in regards to the hippocampal perceptual subregion.

Pre- and post-ECT contrasts with structural connectivity of hippocampal subregions

Structural connectivity between HIPE-LMOG and HIPc-LAG were identified at all four thresholds. The mean image of tractography resulted in a threshold of 0.01 and is shown in the MNI space (Fig. 4a, b). There were no significant FA differences between patients pre- and post-ECT in any of the four thresholds ($p > 0.05$ for all, Fig. 4c, d).

Discussion

In the present study, we found different functional alterations in hippocampal subregions induced by ECT in patients with depression. Specifically, ECT increased connectivity in the HIPE, which may be associated with the alleviation of depressive symptoms. In contrast, ECT decreased connectivity in the HIPc, which may be related to increased cognitive impairment. Unexpectedly, ECT had no effects on the structural connectivity between the

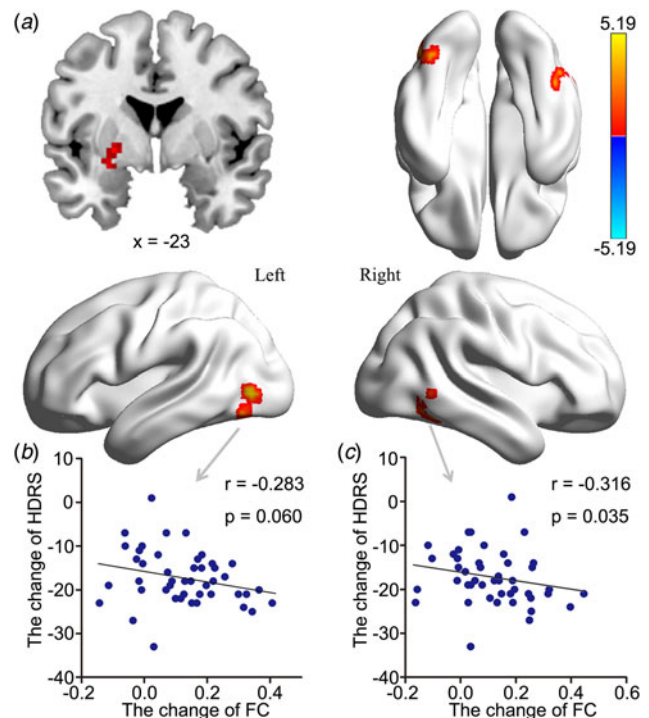


Fig. 2. The effect of ECT on RSFC of the HIPE and its relationship with clinical-symptom changes. (a) There was greater RSFC between the HIPE and the LMOG, left putamen and RMTG after ECT ($Z > 3.1$, $p < 0.001$, cluster-level FWE corrected). (b) There was a significant relationship between increased HIPE-LMOG connectivity and reduced HDRS at trend level. (c) There was a significant relationship between increased HIPE-RMTG connectivity and reduced HDRS (two-tailed, no correction). All scores were calculated using post-ECT scores subtracted from pre-ECT scores. ECT, electroconvulsive therapy; RSFC, resting-state functional connectivity; HIPE, hippocampal emotional region; LMOG, left middle occipital gyrus; RMTG, right medial temporal gyrus; FWE, family-wise error; HDRS, Hamilton Depressive Rating Scale.

hippocampus and functionally abnormal regions, which may suggest that the effects of ECT on brain connectivity may be reversible.

Previous studies revealed a significant relationship between hippocampal functional changes and antidepressive efficacy during ECT (Abbott *et al.*, 2014). However, little is known regarding alterations in hippocampal subregions segmented along the posterior-to-anterior axis in depressed patients treated with ECT. The present study identified an association between altered functions in the anterior hippocampus and effective improvement. Consistent with our results, a post-mortem study on depressed patients revealed that antidepressant drugs increased anterior hippocampal neurogenesis (Boldrini *et al.*, 2009), that could be an important factor in the success of antidepressant treatments (Santarelli *et al.*, 2003). The HIPE (anterior hippocampus in previous studies) used in the present study is known to be closely correlated with functions associated with facial emotion (Robinson *et al.*, 2015), and its abnormal processing is thought to be a primary clinical feature of depression (Gollan *et al.*, 2008; Surguladze *et al.*, 2004). Indeed, the abnormal neural response to facial emotions was also observed in the anterior hippocampus in previous studies on patients with depression (Lau *et al.*, 2010). In addition, the altered hippocampal response to affective facial expressions has been shown to be related to symptomatic improvement following antidepressant treatment (Fu *et al.*, 2007).

Table 1. Regions showing significant differences between pre and post-ECT patients with depression

Regions	MNI coordinate (x, y, z)	Voxel number	Peak t value
Seed of HIPe			
L middle occipital gyrus	-45, -75, 0	45	5.19
L putamen	-24, 0, -3	29	5.04
R medial temporal gyrus	48, -57, -6	32	4.85
Seed of HIPc			
L angular gyrus	-42, -66, 36	70	-4.80
R angular gyrus	51, -63, 21	69	-4.66
L postcentral gyrus/inferior parietal lobule	-33, -27, 51	112	5.25
B medial frontal gyrus	-3, -6, 54	79	5.79

ECT: electroconvulsive therapy; MNI: Montreal Neurologic Institute; HIPe: hippocampal emotional region; HIPc: hippocampal cognitive region; R: right; L: left; B: bilateral

ECT increased the RSFC of the HIPe with the right medial/inferior temporal gyrus (including the fusiform gyrus), the LMOG (including the fusiform gyrus) and the left putamen. Increased RSFC in the medial/inferior temporal gyrus was linked to the remission of depressive severity. Interestingly, all these regions are also involved in facial emotion processing (Freiwald *et al.*, 2016; Fusar-Poli *et al.*, 2009). Dysfunctions of the occipital gyrus, temporal gyri, and putamen have all been implicated in depressed patients and individuals at risk of depression during the task of processing facial emotion (Chan *et al.*, 2009; Kerestes *et al.*, 2016; Surguladze *et al.*, 2005). Based on prior evidence, as well as our results, we speculate that the alleviation of affective symptoms is associated with an improvement in processing facial emotion.

According to the meta-analysis that was used to define ROI, we speculate that the HIPc (hippocampal body) proposed in the current study is substantially involved in memory processes, including paired association recall, cued explicit recognition and encoding (Robinson *et al.*, 2015). In contrast to our results, it has been shown the hippocampal posterior subregion preferentially contributes to memory function (Poppenk and Moscovitch, 2011). The inconsistency may result from the different segmentation of the hippocampus. Indeed, a study that divided the hippocampus into three segments showed that impaired connectivity in the hippocampal body (analogous to the HIPc in the present study) of Alzheimer's patients is positively correlated with cognitive performance (Zarei *et al.*, 2013). In addition, the HIPc defined in the present study has previously been identified in posterior segments in most other studies (Ludwig *et al.*, 2008; Poppenk and Moscovitch, 2011). In line with the above results, our results revealed that ECT decreased RSFC between the HIPc and the bilateral AG in patients with depression, which was positively correlated with memory impairment.

The AG is a region that may have multiple functions, including semantic processing, attention, and memory retrieval (Seghier, 2013). Neuroimaging studies have implicated the strong connectivity between the AG and the hippocampus (Rushworth *et al.*, 2006; Uddin *et al.*, 2010). This strong connectivity is thought to facilitate memory processing (Seghier, 2013; Vilberg and Rugg, 2008). Furthermore, the AG has direct connections with the parahippocampal cortex (Ranganath and Ritchey,

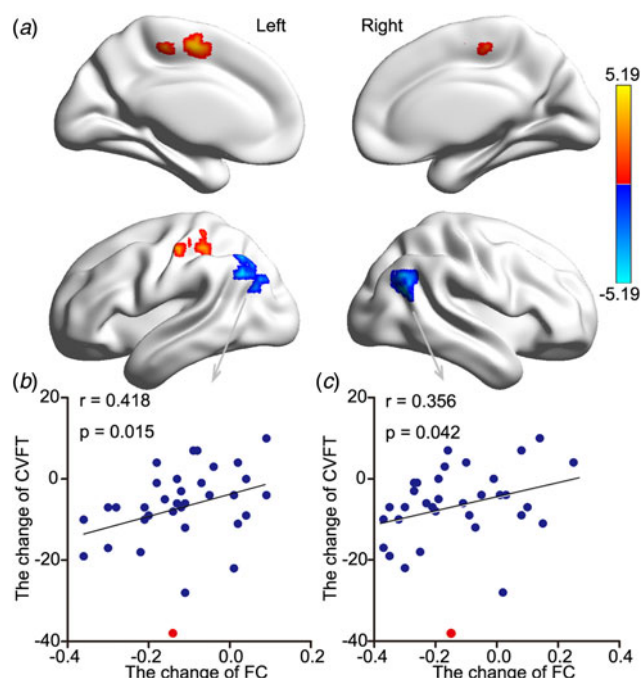


Fig. 3. The effect ECT RSFC of the HIPc and its relationship with memory change. (a) There was lower RSFC between the HIPc and both the LAG and right RAG after ECT. In contrast, there was increased RSFC between the left postcentral gyrus/inferior parietal lobule and the medial frontal gyrus ($Z > 3.1$, $p < 0.001$, cluster-level FWE corrected). (b) There was a significant relationship between decreased HIPc-LAG connectivity and decreased memory performance. (c) There was a significant relationship between increased HIPc-RAG connectivity and reduced memory performance (two-tailed, no correction). Memory performance was evaluated using the CVFT. All scores were calculated using post-ECT scores subtracted from pre-ECT scores (two-tailed, no correction). The red point was regarded as singular data (defined as outside three standard deviations of the mean) and was not included in correlation analysis. ECT, electroconvulsive therapy; RSFC, resting-state functional connectivity; HIPc, hippocampal cognitive region; LAG, left angular gyrus; RAG, right angular gyrus; FWE, family-wise error; CVFT, Category Verbal Fluency Test.

2012), which is strongly connected with the posterior hippocampus (Libby *et al.*, 2012). Indeed, abnormal functions associated with the AG, as well as impaired hippocampus-AG connectivity, have been found in patients with memory impairment (Damoiseaux *et al.*, 2016; Greicius *et al.*, 2004). For example, bilateral AG lesions resulted in an impoverished free recall of autobiographical memory and impaired memory confidence (Berryhill *et al.*, 2007; Simons *et al.*, 2010). Importantly, enhancement of AG-hippocampus connectivity improved memory performance in patients that underwent high-frequency repetitive transcranial magnetic stimulation targeting the AG (Wang *et al.*, 2014). Taken together, we infer that the impaired connectivity between the hippocampus and memory-associated cerebral regions contributes to the memory impairment in depression after ECT.

It is notable that there was increased RSFC between the HIPc and the left postcentral gyrus/inferior parietal lobule and the medial frontal gyrus in depression after ECT. However, this increased connectivity was not associated with changes in depressive symptoms or memory performance. The neurocognitive mechanism involved in this result remains unclear. Given there is a prevalent comorbidity of depression and cognitive impairment (Steffens *et al.*, 2006), the interactive relationship between these impairments may be one potential cause. In fact, the neural correlates of depression and cognitive impairment comorbidity have been shown to involve multiple brain regions, including

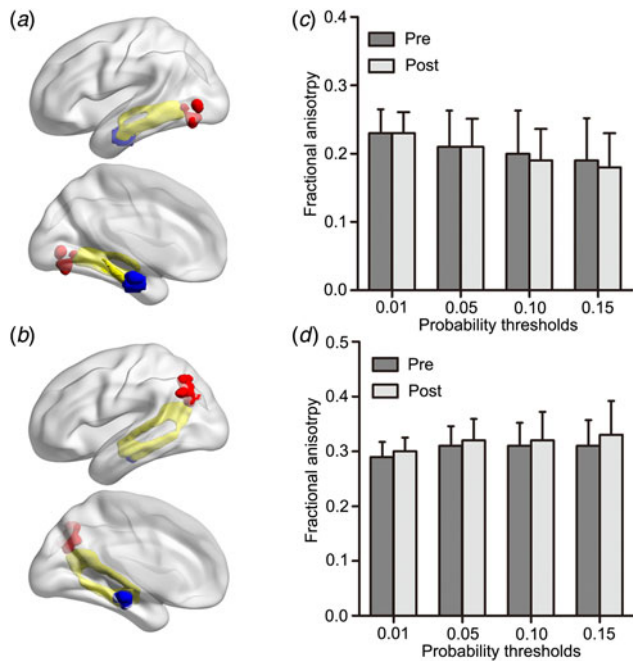


Fig. 4. (a) Probabilistic tractography results (yellow) between the HIPe (blue) and LMOG (red), (b) as well as between the HIPc (blue) and LAG (red) are shown in the MNI space. Probabilistic maps were summed for pre-ECT and post-ECT patients and masked (threshold = 0.01). Only the voxels where more than 70% of the subjects' data overlapped are shown. No significant differences in fractional anisotropy were found across (c) HIPe-LMOG or (d) HIPc-LAG connectivity between pre and post-ECT patients using a spectrum of probability thresholds (0.01, 0.05, 0.10, 0.15). HIPe, hippocampal emotional region; LMOG, left middle occipital gyrus; HIPc, hippocampal cognitive region; LAG, left angular gyrus; MNI, Montreal Neurological Institute; ECT, electroconvulsive therapy.

the hippocampal and inferior parietal lobules (Goveas *et al.*, 2011; Xie *et al.*, 2012).

Although the poorer performance of verbal fluency test following ECT has been documented in the previous study, it is more frequently treated as impairment of executive function, not memory impairment (Semkovska and McLoughlin, 2010). In truth, there are two classes of verbal fluency test, i.e. category verbal fluency and letter verbal fluency. Increasing evidence suggests that these two classes may depend on distinct cognitive processes underlied by different neural mechanisms. Specially, letter verbal fluency mainly reflects the executive function underlied by frontal cortex, in contrast, category verbal fluency most likely relies on medial temporal cortex (predominantly in the hippocampus), mediated the storage and retrieval of semantic knowledge (Henry and Crawford, 2004). Hippocampal involvement in category verbal fluency has consistently been validated functional imaging studies (Sheldon and Moscovitch, 2012; Whitney *et al.*, 2009). Increasingly, CVFT is suggested as an indication of semantic memory and hippocampal function (Glikmann-Johnston *et al.*, 2015; Shapira-Lichter *et al.*, 2013). However, CVFT merely indicates the memory ability for learned information but not the new, which generally regarded as the archetypal function of the posterior hippocampus. Hence, it is without a doubt that CVFT is not the best neuropsychological assessments to test our hypothesis. Further studies are needed to replicate our study with representative assessments of hippocampal function, such as the auditory verbal learning test.

It is worth noting that a relatively lenient statistical threshold was used in our study to test for the correlations between

hippocampal-connection changes and clinical variables. We conducted multiple correlations with no correction, which may potentially increase the risk of obtaining false-positive results. However, our results were acquired based on explicit prior assumptions and showed remarkable consistency with assumptions using a few of correlations analysis (three for emotional effect and four for cognitive effect). For paired ipsilateral regions (HIPe-LMOG and HIPc-LAG) which showed a significant correlation between inter-regions functional connectivity and clinical variables, impressive anatomical connectivity was also presented with DTI. These may potentially reduce the risk of drawing a conclusion based on false-positive results. Certainly, we must acknowledge that our results presented low magnitude of correlations. For example, most of the correlation coefficients just achieved statistical significance at the 0.05 level in our study and we labeled a p value >0.05 (p value = 0.06) as a 'trend'. The low magnitude of correlations may be caused by small sample size and high between-participants heterogeneity. The seeds defined with population-level, not individual-level atlases would erode actual individual variations (Wang *et al.*, 2015), which may lessen the correlations between hippocampal connectivity and clinical variables. Besides, the absence of long scan duration would reduce the reliability of measuring functional connectivity (Birn *et al.*, 2013; Termenon *et al.*, 2016), which also may contribute to the low magnitude of correlation in our results. Thus, future studies are necessary to replicate our results with more large-size and homogeneous sample, longer scan duration and hippocampal seeds based on individual-level atlases.

We also admit to several additional limitations in this study. First, no healthy controls were included. Second, the sample size is too small that may have led to sampling bias. Third, twice verbal fluency tests were given and, in general, performances were evaluated after the second test. However, most patients performed worse during the second test and we believe the results of the CVFT were not biased by practice. Finally, only functional changes in the left hippocampal subregions were assessed and in future studies, it will be necessary to explore alterations in both the right and left hippocampal-subregions.

These limitations notwithstanding, our results suggest that altered functions of the HIPe may be associated with remission of depression, while altered functions of the HIPc may be associated with impaired cognition, which indicates a functional dissociation between subregions of the hippocampus.

Acknowledgements. This work was supported by funding from the National Nature Science Foundation of China (No. 81471117, No. 81671354, No. 81601187, No. 91432301 and No. 91732303), the National Basic Research Program of China (No. 2015CB856400), the National Key Technology Research and Development Program of the Ministry of Science and Technology of China (No. 2015BAI13B01) and Anhui Provincial Science Fund for Distinguished Young Scholars (No. 1808085J23).

Conflict of interest. None.

References

- Abbott CC, Jones T, Lemke NT, Gallegos P, McClintock SM, Mayer AR, Bustillo J and Calhoun VD (2014) Hippocampal structural and functional changes associated with electroconvulsive therapy response. *Translational Psychiatry* 4, e483.
- Abdallah CG, Wrocklage KM, Averill CL, Akiki T, Schweinsburg B, Roy A, Martini B, Southwick SM, Krystal JH and Scott JC (2017) Anterior hippocampal dysconnectivity in posttraumatic stress disorder: a dimensional and multimodal approach. *Translational Psychiatry* 7, e1045.

- Bai T, Xie W, Wei Q, Chen Y, Mu J, Tian Y and Wang K (2017) Electroconvulsive therapy regulates emotional memory bias of depressed patients. *Psychiatry Research* 257, 296–302.
- Berryhill ME, Phuong L, Picasso L, Cabeza R and Olson IR (2007) Parietal lobe and episodic memory: bilateral damage causes impaired free recall of autobiographical memory. *Journal of Neuroscience* 27, 14415–14423.
- Birn RM, Molloy EK, Patriat R, Parker T, Meier TB, Kirk GR, Nair VA, Meyerand ME and Prabhakaran V (2013) The effect of scan length on the reliability of resting-state fMRI connectivity estimates. *NeuroImage* 83, 550–558.
- Boldrini M, Underwood MD, Hen R, Rosoklija GB, Dwork AJ, John Mann J and Arango V (2009) Antidepressants increase neural progenitor cells in the human hippocampus. *Neuropsychopharmacology* 34, 2376–2389.
- Buckner RL, Andrews-Hanna JR and Schacter DL (2008) The brain's default network: anatomy, function, and relevance to disease. *Annals of the New York Academy of Sciences* 1124, 1–38.
- Cao X, Liu Z, Xu C, Li J, Gao Q, Sun N, Xu Y, Ren Y, Yang C and Zhang K (2012) Disrupted resting-state functional connectivity of the hippocampus in medication-naïve patients with major depressive disorder. *Journal of Affective Disorders* 141, 194–203.
- Conquiza LA and Swanson LW (2007) Spatial organization of direct hippocampal field CA1 axonal projections to the rest of the cerebral cortex. *Brain Research Reviews* 56, 1–26.
- Chakrabarti S, Grover S and Rajagopal R (2010) Electroconvulsive therapy: a review of knowledge, experience and attitudes of patients concerning the treatment. *World Journal of Biological Psychiatry* 11, 525–537.
- Chan SW, Norbury R, Goodwin GM and Harmer CJ (2009) Risk for depression and neural responses to fearful facial expressions of emotion. *British Journal of Psychiatry* 194, 139–145.
- Chao-Gan Y and Yu-Feng Z (2010) DPARSF: a MATLAB toolbox for “pipeline” data analysis of resting-state fMRI. *Frontiers in Systems Neuroscience* 4, 13.
- Chen AC and Etkin A (2013) Hippocampal network connectivity and activation differentiates post-traumatic stress disorder from generalized anxiety disorder. *Neuropsychopharmacology* 38, 1889–1898.
- Damoiseaux JS, Viviano RP, Yuan P and Raz N (2016) Differential effect of age on posterior and anterior hippocampal functional connectivity. *NeuroImage* 133, 468–476.
- Dukart J, Regen F, Kherif F, Colla M, Bajbouj M, Heuser I, Frackowiak RS and Draganski B (2014) Electroconvulsive therapy-induced brain plasticity determines therapeutic outcome in mood disorders. *Proceedings of the National Academy of Sciences of the United States of America* 111, 1156–1161.
- Fanselow MS and Dong HW (2010) Are the dorsal and ventral hippocampus functionally distinct structures? *Neuron* 65, 7–19.
- Femenia T, Gomez-Galan M, Lindskog M and Magara S (2012) Dysfunctional hippocampal activity affects emotion and cognition in mood disorders. *Brain Research* 1476, 58–70.
- Fink M (2000) ECT has proved effective in treating depression. *Nature* 403, 826.
- Finkelmeyer A, Nilsson J, He J, Stevens L, Maller JJ, Moss RA, Small S, Gallagher P, Coventry K, Ferrier IN and McAllister-Williams RH (2016) Altered hippocampal function in major depression despite intact structure and resting perfusion. *Psychological Medicine* 46, 2157–2168.
- Freiwald W, Duchaine B and Yovel G (2016) Face processing systems: from neurons to real-world social perception. *Annual Review of Neuroscience* 39, 325–346.
- Fu CH, Williams SC, Brammer MJ, Suckling J, Kim J, Cleare AJ, Walsh ND, Mitterschiffthaler MT, Andrew CM, Pich EM and Bullmore ET (2007) Neural responses to happy facial expressions in major depression following antidepressant treatment. *American Journal of Psychiatry* 164, 599–607.
- Fusar-Poli P, Placentino A, Carletti F, Landi P, Allen P, Surguladze S, Benedetti F, Abbamonte M, Gasparotti R, Barale F, Perez J, McGuire P and Politi P (2009) Functional atlas of emotional faces processing: a voxel-based meta-analysis of 105 functional magnetic resonance imaging studies. *Journal of Psychiatry & Neuroscience* 34, 418–432.
- Glikmann-Johnston Y, Oren N, Hendler T and Shapira-Lichter I (2015) Distinct functional connectivity of the hippocampus during semantic and phonemic fluency. *Neuropsychologia* 69, 39–49.
- Gollan JK, Pane HT, McCloskey MS and Coccaro EF (2008) Identifying differences in biased affective information processing in major depression. *Psychiatry Research* 159, 18–24.
- Goossens KA (2011) Hippocampal regulation of aversive memories. *Current Opinion in Neurobiology* 21, 460–466.
- Goveas J, Xie C, Wu Z, Douglas Ward B, Li W, Franczak MB, Jones JL, Antuono PG, Yang Z and Li SJ (2011) Neural correlates of the interactive relationship between memory deficits and depressive symptoms in nondemented elderly: resting fMRI study. *Behavioural Brain Research* 219, 205–212.
- Greicius MD, Srivastava G, Reiss AL and Menon V (2004) Default-mode network activity distinguishes Alzheimer's disease from healthy aging: evidence from functional MRI. *Proceedings of the National Academy of Sciences of the United States of America* 101, 4637–4642.
- Henry JD and Crawford JR (2004) A meta-analytic review of verbal fluency performance following focal cortical lesions. *Neuropsychology* 18, 284–295.
- Ji GJ, Zhang Z, Xu Q, Zang YF, Liao W and Lu G (2014) Generalized tonic-clonic seizures: aberrant interhemispheric functional and anatomical connectivity. *Radiology* 271, 839–847.
- Jiang J, Wang J and Li C (2016) Potential mechanisms underlying the therapeutic effects of electroconvulsive therapy. *Neuroscience Bulletin* 33, 339–347.
- Joshi SH, Espinoza RT, Pirnia T, Shi J, Wang Y, Ayers B, Leaver A, Woods RP and Narr KL (2016) Structural plasticity of the hippocampus and amygdala induced by electroconvulsive therapy in Major depression. *Biological Psychiatry* 79, 282–292.
- Kerestes R, Segreti AM, Pan LA, Phillips ML, Birmaher B, Brent DA and Ladouceur CD (2016) Altered neural function to happy faces in adolescents with and at risk for depression. *Journal of Affective Disorders* 192, 143–152.
- Lau JY, Goldman D, Buzas B, Hodgkinson C, Leibenluft E, Nelson E, Sankin L, Pine DS and Ernst M (2010) BDNF gene polymorphism (Val66Met) predicts amygdala and anterior hippocampus responses to emotional faces in anxious and depressed adolescents. *NeuroImage* 53, 952–961.
- Libby LA, Ekstrom AD, Ragland JD and Ranganath C (2012) Differential connectivity of perirhinal and parahippocampal cortices within human hippocampal subregions revealed by high-resolution functional imaging. *Journal of Neuroscience* 32, 6550–6560.
- Ludwig E, Trautner P, Kurthen M, Schaller C, Bien CG, Elger CE and Rosburg T (2008) Intracranially recorded memory-related potentials reveal higher posterior than anterior hippocampal involvement in verbal encoding and retrieval. *Journal of Cognitive Neuroscience* 20, 841–851.
- McKinnon MC, Yucel K, Nazarov A and MacQueen GM (2009) A meta-analysis examining clinical predictors of hippocampal volume in patients with major depressive disorder. *Journal of Psychiatry & Neuroscience* 34, 41–54.
- Nobler MS and Sackeim HA (2008) Neurobiological correlates of the cognitive side effects of electroconvulsive therapy. *Journal of ECT* 24, 40–45.
- Parent MA, Wang L, Su J, Netoff T and Yuan LL (2010) Identification of the hippocampal input to medial prefrontal cortex in vitro. *Cerebral Cortex* 20, 393–403.
- Poppenk J and Moscovitch M (2011) A hippocampal marker of recollection memory ability among healthy young adults: contributions of posterior and anterior segments. *Neuron* 72, 931–937.
- Poppenk J, Evensmoen HR, Moscovitch M and Nadel L (2013) Long-axis specialization of the human hippocampus. *Trends in Cognitive Sciences* 17, 230–240.
- Rami-Gonzalez L, Bernardo M, Boget T, Salamero M, Gil-Verona JA and Junque C (2001) Subtypes of memory dysfunction associated with ECT: characteristics and neurobiological bases. *Journal of ECT* 17, 129–135.
- Ranganath C and Ritchey M (2012) Two cortical systems for memory-guided behaviour. *Nature Reviews Neuroscience* 13, 713–726.
- Reid IC and Stewart CA (1997) Seizures, memory and synaptic plasticity. *Seizure* 6, 351–359.

- Roberts AC, Tomic DL, Parkinson CH, Roeling TA, Cutter DJ, Robbins TW and Everitt BJ (2007) Forebrain connectivity of the prefrontal cortex in the marmoset monkey (*Callithrix jacchus*): an anterograde and retrograde tract-tracing study. *Journal of Comparative Neurology* **502**, 86–112.
- Robinson JL, Barron DS, Kirby LA, Bottenhorn KL, Hill AC, Murphy JE, Katz JS, Salibi N, Eickhoff SB and Fox PT (2015) Neurofunctional topography of the human hippocampus. *Human Brain Mapping* **36**, 5018–5037.
- Rushworth MF, Behrens TE and Johansen-Berg H (2006) Connection patterns distinguish 3 regions of human parietal cortex. *Cerebral Cortex* **16**, 1418–1430.
- Sahay A and Hen R (2007) Adult hippocampal neurogenesis in depression. *Nature Neuroscience* **10**, 1110–1115.
- Santarelli L, Saxe M, Gross C, Surget A, Battaglia F, Dulawa S, Weisstaub N, Lee J, Duman R, Arancio O, Belzung C and Hen R (2003) Requirement of hippocampal neurogenesis for the behavioral effects of antidepressants. *Science* **301**, 805–809.
- Seghier ML (2013) The angular gyrus: multiple functions and multiple subdivisions. *Neuroscientist* **19**, 43–61.
- Semkowska M and McLoughlin DM (2010) Objective cognitive performance associated with electroconvulsive therapy for depression: a systematic review and meta-analysis. *Biological Psychiatry* **68**, 568–577.
- Shapira-Lichter I, Oren N, Jacob Y, Gruberger M and Hendler T (2013) Portraying the unique contribution of the default mode network to internally driven mnemonic processes. *Proceedings of the National Academy of Sciences of the United States of America* **110**, 4950–4955.
- Sheldon S and Moscovitch M (2012) The nature and time-course of medial temporal lobe contributions to semantic retrieval: an fMRI study on verbal fluency. *Hippocampus* **22**, 1451–1466.
- Simons JS, Peers PV, Mazuz YS, Berryhill ME and Olson IR (2010) Dissociation between memory accuracy and memory confidence following bilateral parietal lesions. *Cerebral Cortex* **20**, 479–485.
- Small SA, Schobel SA, Buxton RB, Witter MP and Barnes CA (2011) A pathophysiological framework of hippocampal dysfunction in ageing and disease. *Nature Reviews Neuroscience* **12**, 585–601.
- Song XW, Dong ZY, Long XY, Li SF, Zuo XN, Zhu CZ, He Y, Yan CG and Zang YF (2011) REST: a toolkit for resting-state functional magnetic resonance imaging data processing. *PLoS ONE* **6**, e25031.
- Spaans HP, Sienaert P, Bouckaert F, van den Berg JF, Verwijk E, Kho KH, Stek ML and Kok RM (2015) Speed of remission in elderly patients with depression: electroconvulsive therapy v. medication. *British Journal of Psychiatry* **206**, 67–71.
- Steffens DC, Otey E, Alexopoulos GS, Butters MA, Cuthbert B, Ganguli M, Geda YE, Hendrie HC, Krishnan RR, Kumar A, Lopez OL, Lyketsos CG, Mast BT, Morris JC, Norton MC, Peavy GM, Petersen RC, Reynolds CF, Salloway S, Welsh-Bohmer KA and Yesavage J (2006) Perspectives on depression, mild cognitive impairment, and cognitive decline. *Archives of General Psychiatry* **63**, 130–138.
- Surguladze SA, Young AW, Senior C, Brebion G, Travis MJ and Phillips ML (2004) Recognition accuracy and response bias to happy and sad facial expressions in patients with major depression. *Neuropsychology* **18**, 212–218.
- Surguladze S, Brammer MJ, Keedwell P, Giampietro V, Young AW, Travis MJ, Williams SC and Phillips ML (2005) A differential pattern of neural response toward sad versus happy facial expressions in major depressive disorder. *Biological Psychiatry* **57**, 201–209.
- Tahmasian M, Knight DC, Manoliu A, Schwerthoffer D, Scherr M, Meng C, Shao J, Peters H, Doll A, Khazaie H, Drzezga A, Bauml J, Zimmer C, Forstl H, Wohlschlagel AM, Riedl V and Sorg C (2013) Aberrant intrinsic connectivity of hippocampus and amygdala overlap in the fronto-insular and dorsomedial-prefrontal cortex in major depressive disorder. *Frontiers in Human Neuroscience* **7**, 639.
- Termenon M, Jaillard A, Delon-Martin C and Achard S (2016) Reliability of graph analysis of resting state fMRI using test-retest dataset from the human connectome project. *NeuroImage* **142**, 172–187.
- Uddin LQ, Supekar K, Amin H, Rykhlevskaia E, Nguyen DA, Greicius MD and Menon V (2010) Dissociable connectivity within human angular gyrus and intraparietal sulcus: evidence from functional and structural connectivity. *Cerebral Cortex* **20**, 2636–2646.
- Vilberg KL and Rugg MD (2008) Memory retrieval and the parietal cortex: a review of evidence from a dual-process perspective. *Neuropsychologia* **46**, 1787–1799.
- Wang JX, Rogers LM, Gross EZ, Ryals AJ, Dokucu ME, Brandstatt KL, Hermiller MS and Voss JL (2014) Targeted enhancement of cortical-hippocampal brain networks and associative memory. *Science* **345**, 1054–1057.
- Wang D, Buckner RL, Fox MD, Holt DJ, Holmes AJ, Stoeklein S, Langs G, Pan R, Qian T, Li K, Baker JT, Stufflebeam SM, Wang K, Wang X, Hong B and Liu H (2015) Parcellating cortical functional networks in individuals. *Nature Neuroscience* **18**, 1853–1860.
- Whitney C, Weis S, Krings T, Huber W, Grossman M and Kircher T (2009) Task-dependent modulations of prefrontal and hippocampal activity during intrinsic word production. *Journal of Cognitive Neuroscience* **21**, 697–712.
- Woo C-W, Krishnan A and Wager TD (2014) Cluster-extent based thresholding in fMRI analyses: pitfalls and recommendations. *NeuroImage* **91**, 412–419.
- Xia M, Wang J and He Y (2013) Brainnet viewer: a network visualization tool for human brain connectomics. *PLoS ONE* **8**, e68910.
- Xie C, Goveas J, Wu Z, Li W, Chen G, Franczak M, Antuono PG, Jones JL, Zhang Z and Li SJ (2012) Neural basis of the association between depressive symptoms and memory deficits in nondemented subjects: resting-state fMRI study. *Human Brain Mapping* **33**, 1352–1363.
- Zarei M, Beckmann CF, Binnewijzend MA, Schoonheim MM, Oghabian MA, Sanz-Arigita EJ, Scheltens P, Matthews PM and Barkhof F (2013) Functional segmentation of the hippocampus in the healthy human brain and in Alzheimer's disease. *NeuroImage* **66**, 28–35.