

Spontaneous Intracranial Hypotension: Recommendations for Management

Farnaz Amoozegar, Darryl Guglielmin, William Hu, Denise Chan, Werner J. Becker

ABSTRACT: A literature search found no clinical trials or guidelines addressing the management of spontaneous intracranial hypotension (SIH). Based on the available literature and expert opinion, we have developed recommendations for the diagnosis and management of SIH. For typical cases, we recommend brain magnetic resonance (MR) imaging with gadolinium to confirm the diagnosis, and conservative measures for up to two weeks. If the patient remains symptomatic, up to three non-directed lumbar epidural blood patches (EBPs) should be considered. If these are unsuccessful, non-invasive MR myelography, radionuclide cisternography, MR myelography with intrathecal gadolinium, or computed tomography with myelography should be used to localize the leak. If the leak is localized, directed EPBs should be considered, followed by fibrin sealant or neurosurgery if necessary. Clinically atypical cases with normal brain MR imaging should be investigated to localize the leak. Directed EPBs can be used if the leak is localized; non-directed EPBs should be used only if there are indirect signs of SIH.

RÉSUMÉ: Hypotension intracrânienne spontanée : recommandations de traitement. Nous n'avons trouvé aucun essai clinique ou ligne directrice sur le traitement de l'hypotension intracrânienne spontanée (HIS) lors d'une recherche de la littérature. Nous avons élaboré des recommandations sur le diagnostic et le traitement de l'HIS fondées sur la littérature disponible et l'avis d'experts. Chez les cas typiques, nous recommandons de procéder à une IRM cérébrale avec gadolinium pour confirmer le diagnostic et de prescrire un traitement conservateur pour une période de temps allant jusqu'à deux semaines. Si le patient demeure symptomatique, on devrait envisager de faire jusqu'à trois blood patches épidurales lombaires non dirigées. Si ce traitement ne donne pas de résultat, une myélographie non effractive par résonance magnétique, une cisternographie isotopique, une myélographie par résonance magnétique avec gadolinium intrathécal ou une myélographie par tomodensitométrie devrait être effectuée afin de localiser la fuite. Si la fuite est localisée, on devrait envisager de faire des blood patches dirigées suivies de l'administration d'un scellant de fibrine ou avoir recours à la neurochirurgie si nécessaire. Chez les cas atypiques au point de vue clinique, qui ont une IRM cérébrale normale, on devrait essayer de localiser la fuite. Des blood patches dirigées peuvent être utilisés si la fuite est localisée. Des blood patches non dirigées ne devraient être utilisées que s'il y a des signes indirects d'HIS.

Can J Neurol Sci. 2013; 40: 144-157

Spontaneous intracranial hypotension (SIH) is a syndrome in which a cerebrospinal fluid leak occurs within the spinal axis, and may lead to a constellation of neurological symptoms. A postural or orthostatic headache is the most common of these symptoms¹.

Spontaneous intracranial hypotension was first recognized by Georg Schaltenbrand in the 1930s. Many terms have been used to describe the condition: low pressure headache, intracranial hypotension, and cerebral spinal fluid (CSF) hypovolemia. The International Classification of Headache Disorders uses "Headache attributed to spontaneous (or idiopathic) low CSF pressure"². However, because most cases are secondary to a spontaneous spinal CSF leak, the term spontaneous spinal CSF leak or spontaneous intracranial hypotension is preferred^{1,3}. None of these terms are completely satisfactory, however. Not all cases show a low CSF pressure on lumbar puncture, and not all of the CSF leaks are spontaneous as trauma may play a role in some cases. "Headache attributed to CSF leak" might be the best term, with cases subdivided into spontaneous and post-traumatic cases. The term "SIH" will be used here as most cases likely do have some degree of relative intracranial hypotension even though their CSF pressure may be within normal limits when measured during a lumbar puncture. Intracranial

hypotension as a result of trauma is not as well documented but several cases have been reported in the literature^{4,5}.

1. Epidemiology and Pathophysiology

There have been no large studies looking at the incidence or prevalence of SIH. The estimated annual incidence is about 5 per 100,000. The onset of symptoms is usually in the fourth to fifth decades of life with a peak incidence around age 40. Spontaneous intracranial hypotension affects women more than men by a ratio of 1.5:1⁶.

Spontaneous intracranial hypotension is caused by spontaneous spinal CSF leaks. These usually do not cause local symptoms, and there is no risk of meningitis, as CSF is absorbed

From the Department of Anesthesia (DG), Department of Diagnostic Imaging (WH, DC), Department of Clinical Neurosciences (FA, WJB), University of Calgary Foothills Medical Centre, Calgary, Alberta, Canada.

RECEIVED FEBRUARY 21, 2012. FINAL REVISIONS SUBMITTED OCTOBER 10, 2012.
Correspondence to: Calgary Headache Assessment & Management Program, Department of Clinical Neurosciences, University of Calgary, South Health Campus, 4448 Front Street SE, Calgary, Alberta, T3M 1M4, Canada.
Email: farnaz.amoozegar@albertahealthservices.ca

into the perispinal soft tissues. The majority of CSF spinal leaks are usually found at the cervicothoracic junction or in the thoracic spine^{1,3}. The cause of the leak remains unknown in the majority of patients and is likely multifactorial. Underlying fragility of the spinal meninges is often suspected. A history of trauma can be elicited in about one third of patients, suggesting mechanical factors as well^{1,3}.

In some patients, an inherited connective tissue disorder plays a role in the development of CSF leaks. Of these, Marfan syndrome, Ehlers-Danlos syndrome (type II), and autosomal dominant polycystic kidney disease are the most important. Some patients are found to have osseous spinal pathology, including degenerative disk disease with osteophytes piercing the dura^{1,3}. Congenital bony spurs can be found as well. At surgery, a wide variety of dural abnormalities can be seen, including dural holes or rents, meningeal diverticula, or localized absence of the dura^{1,3}.

2. Clinical Features

The International Headache Society (IHS) published diagnostic criteria (ICHD-II) for SIH in 2004 (Appendix I). However, SIH spans a wide spectrum of clinical and radiographic findings, which is not reflected by these criteria. Schievink proposed diagnostic criteria in 2008 (Appendix 2), but these also are not fully sensitive, and do not diagnose all cases of SIH.

The prototypical and most common manifestation of SIH is an orthostatic headache. It can occur within seconds to minutes of taking an upright position, but can be delayed by hours. The headache usually improves or resolves after lying down, typically within 30 minutes. The headache is usually holocephalic and diffuse, but may be localized to one region of the head or may be asymmetric^{1,3,7}. The initial onset of headache in the majority of patients is gradual or subacute, and headache severity can vary from mild to severe^{1,3,6}.

Other headache patterns can occur and some patients may not have a postural component to their headaches. Others have exertional headaches, headaches at the end of the day, or even paradoxical headaches, in which the headache is better upright and worse with recumbency. Spontaneous intracranial hypotension can be an important cause of new daily persistent headache, and should be considered in the differential diagnosis of thunderclap headache^{1,3,6,8-10}. In rare cases of SIH, there may be no headache present. This has been reported mainly in elderly patients who have undergone CSF shunting (for a communicating hydrocephalus for example) with an overdraining CSF shunt¹¹.

The exact cause of the headache is unknown, but may be related to downward displacement of the brain due to loss of CSF buoyancy, causing traction on pain-sensitive structures. Compensatory dilation of pain-sensitive intracranial venous structures may also play a role^{1,3,6}. The pathophysiology of paradoxical headaches related to SIH remains unclear. It is speculated that the compensatory dilation of venous structures may play a more dominant role in association with a dysfunctional autoregulatory system, leading to increased cerebrovascular volume in recumbency rather than with upright posture¹². In the rare cases where there is no headache, as described above, it is possible that a balance may occur between

the buoyancy of the brain with its reduced weight and CSF volume, resulting in no sagging of the brain¹¹.

Other relatively common symptoms of SIH include posterior neck pain or stiffness, nausea and vomiting, and photophobia and phonophobia. These may be secondary to meningeal irritation. Some patients have changes in hearing (echoing, under water sensation), tinnitus, and a disturbed sense of balance, secondary to traction of cranial nerves. Rare additional symptoms include visual blurring, visual field defects, diplopia, facial numbness or facial pain, facial weakness or spasm, parkinsonism, ataxia, and dementia. Distortion of the pituitary stalk may lead to hyperprolactinemia, galactorrhea and severe brain displacement may lead to diencephalic herniation with stupor or coma^{1,3,6}.

Spinal manifestations of SIH are uncommon, with interscapular pain the most frequent. Rarely, local back pain at the site of the leak, quadriparesis and radicular symptoms can occur.

3. Current Diagnosis and Management

The diagnosis and management of SIH can be challenging. Currently, there are no standard guidelines and randomized studies are lacking. Most of the relevant literature consists of smaller studies, case series, and expert opinion.

For diagnosis, the history and physical exam remain important. Magnetic resonance imaging (MRI) of the brain has revolutionized the diagnosis of SIH and is performed in the majority of cases. Radionuclide cisternography, myelography and lumbar puncture remain important tools, but each has limitations. We will look at each of these modalities with the available data, to determine a rational approach to the diagnosis of SIH.

It is important to note that not all cases of postural headache are due to a CSF leak. Rarer conditions, including postural tachycardia syndrome and increased compliance of the lower spinal CSF space should be considered, especially when all tests are negative¹³. It is theorized that patients with increased compliance of the lower spinal CSF space have an abnormal distribution of craniospinal elasticity, causing caudal displacement of the hydrostatic indifferent point when patients are supine, leading to reduced CSF pressure^{13,14}. In one study¹⁴, of 125 consecutive patients seen with orthostatic headache, six showed no radiologic evidence of CSF leaks. These six patients underwent brain and spine MRI, radionuclide cisternography, computed tomogram (CT) myelography, and had normal CSF opening pressures.

If conservative measures are not effective, the mainstay of SIH treatment is the epidural blood patch (EBP). However, this is not always successful. Directed blood patches, percutaneous placement of fibrin sealant, and neurosurgical interventions are other treatment options. Based on the available data, we present recommendations to provide a practical approach to the treatment of SIH. Because randomized controlled trial evidence is not available for any of the required clinical decisions, we have not graded our recommendations.

GOALS OF THE REVIEW

Our goal is to present a logical and practical approach to the diagnosis and treatment of SIH. Our specific aims are to:

- 1) Clarify which tests to order when SIH is suspected, and in what sequence.
- 2) Provide recommendations on when to initiate specific treatment options.

METHODS

A search of the medical literature was conducted on Ovid Medline and PubMed from 1990 to the present. The Mesh headings included: spontaneous intracranial hypotension, idiopathic intracranial hypotension, low-pressure headache, and CSF leak. These terms were searched independently and in combination with the following: CT, MRI, neuroimaging, radionuclide cisternogram/cisternography, CSF flow study, myelogram, treatment, epidural blood patch, fibrin glue, and neurosurgery. The most relevant and larger studies were then reviewed, in addition to a number of case series and case reports. Case reports are only highlighted below if they add further information. No randomized or controlled treatment trials were found.

SUMMARY OF THE EVIDENCE

I. Diagnosis of SIH

a. CT Brain

No studies have assessed brain CT scanning in SIH but reviews and anecdotal experience indicate that CT is not sensitive for signs of SIH. A brain CT scan may occasionally show subdural fluid collections, cerebellar tonsillar herniation, ventricular collapse and obliteration of the subarachnoid cisterns but is often more useful in excluding other causes of headache.

b. MRI Brain and Spine

Several case series have demonstrated that the majority, but not all patients with SIH have brain MRI abnormalities. These can be remembered by the acronym SEEPS¹:

S = subdural fluid collections (mostly hygromas, occasionally hematomas)

E = enhancement of the pachymeninges (uniform, smooth and diffuse)

E = engorgement of venous structures

P = pituitary hyperemia

S = sagging of the brain (descent of the cerebellar tonsils, effacement of the basal cisterns, bowing of the optic chiasm, flattening of the pons).

One study, which examined the sensitivity of MRI of the brain and spine in detecting abnormalities in patients with a clinical diagnosis of SIH¹⁵, assessed 18 patients retrospectively between 1998 and 2007. Spontaneous intracranial hypotension was diagnosed clinically and by CSF opening pressure (OP). Sixteen of 18 patients had typical orthostatic headache and 12 of 18 had a low OP. Brain MR imaging detected abnormalities in 15 of the 18 patients (83%): diffuse pachymeningeal enhancement in 15 (83%), descent of the cerebellar tonsil in 13 (72%), brainstem sagging in 13 (72%), enlargement of the pituitary gland in 12 (67%), and subdural fluid collections in 13 (72%). Spinal MR imaging detected abnormalities in 17 of the 18 patients (94%): distention of the epidural veins in 14 (78%), epidural fluid collection on fat-saturated T2-weighted images in 16 (89%), and abnormal visualization of the nerve root sleeve in 1 (6%).

Sensitivity for SIH was 83% for brain MR imaging and 94% for spinal MR imaging.

Other studies have also demonstrated that the most common finding of SIH on MRI of the brain is diffuse pachymeningeal enhancement, followed by subdural fluid collections and sagging of the brain¹⁶⁻²².

In spinal MRI, the most common findings are epidural fluid collections and collapse of the dural sac^{23,24}. One case series²⁴ analyzed nine patients and demonstrated epidural fluid collections in seven. In six, the dural sac had collapsed, with a festooned appearance. Intense epidural enhancement on post-contrast studies was also seen and felt to be due to marked dilatation of the epidural venous plexus. In three cases, an irregular root sleeve suggested a possible point of CSF leakage. The authors comment that the: *“pattern of spinal abnormalities is different from that seen in cranial MRI for anatomical reasons: in the spinal canal the dura is not adherent to the bone; therefore, collapse of the dural sac and dilatation of epidural venous plexus occur, rather than subdural hematomas.”*

It is important to note that not all patients with SIH have brain MRI abnormalities. Schoffer and colleagues²⁰ found that three of their four patients exhibited diffuse spinal and intracranial pachymeningeal gadolinium (gad) enhancement and extradural or subdural fluid collections on MRI. One patient had no MRI abnormalities despite prominent postural headache and reduced CSF pressure at lumbar puncture. In another study²², 14 of 15 patients with SIH had abnormal brain MRI findings.

Specific signs on brain MRI in SIH include the venous distension sign, which assesses the inferior margin of the midportion of the dominant transverse sinus. Normally, on T1-weighted sagittal views, this margin shows a concave or straight configuration, while in SIH it usually assumes a distended convex configuration (the venous distension sign). The sensitivity of the venous distension sign for the diagnosis of SIH was found to be 94%; specificity was also 94%²⁵. The “venous hinge” sign: reduction of the angle between the vein of Galen and internal cerebral vein, which returns to baseline after treatment, has also been reported²⁶.

Most of the findings of SIH on MRI can be explained by compensatory changes related to loss of CSF volume. The Monroe-Kelly hypothesis states that the sum of the volumes of intracranial blood, CSF, and cerebral tissue must remain constant in an intact cranium. Loss of CSF from a leak, can be compensated for by increasing the vascular component, accounting for: pachymeningeal enhancement, engorgement of venous structures, and pituitary hyperaemia. Subdural hygromas (subdural collections of CSF) may compensate to some extent for the loss of CSF volume. Subdural hematomas may be caused by tearing of bridging veins or rupture of the dilated thin-walled blood vessels in the subdural zone. Sagging of the brain may be caused by loss of CSF buoyancy^{1,3,6}.

Improvement of MRI abnormalities can be seen within hours to weeks of successful treatment of the CSF leak. Clinical improvement usually occurs first, before changes on MRI are seen. Larger subdural hematomas can take up to a few months to improve¹.

c. Radionuclide Cisternography (RNC)

Several studies have indicated that cisternography is a relatively sensitive method to detect indirect signs of SIH, and

can be helpful for detecting the leak. Its usefulness is limited because of poor resolution and the exact site of the CSF leak remains unclear in up to a third of patients. However, with the introduction of simultaneous CT/SPECT imaging, the sensitivity for detecting the level of CSF leaks has improved. Radionuclide cisternography can be done with Indium-111 or technetium-99m labeled Diethylenetriaminepentaacetate (DTPA). Technetium-99m has a shorter half-life than Indium-111. Overall, Indium is preferred over technetium as it allows for delayed imaging, up to 48 hours, due to its longer half-life. Scans should be performed at several points after the injections, up to 24-48 hours later, to improve chances of detecting fast or slow leaks.

The most common findings on RNC include: early accumulation of tracer in the kidneys and bladder, slow ascent of the radionuclide along the spinal axis, paucity of activity over the cerebral convexities at 24 hours, and abnormal root sleeve visualization^{1,3}. These are all indirect signs of a CSF leak. It may also show the actual site of the CSF leak demonstrated by extravasation of radionuclide, which is the only direct sign of SIH in this modality.

Hyun and colleagues²⁷ retrospectively investigated the value of cisternography in 30 patients with SIH. This was diagnosed as orthostatic headache with at least one of: MRI findings of SIH, CSF leak demonstrated by CT myelogram, or CSF OP < 6 cm H₂O. All patients in the study underwent RNC and the actual site of CSF leak(s) was seen in 80% of patients (i.e. direct evidence of the leak). Ninety percent of the patients showed indirect signs of SIH.

Morioka and colleagues²⁸ looked in more detail at the direct and indirect signs of CSF leaks. A total of 67 patients with clinically suspected SIH underwent RNC, and 27 patients were found to have direct findings of CSF leakage; i.e. the site of the CSF leak was identified. In these 27 patients, early visualization of bladder activity was found in all. No activity was shown in 25.9% over the brain convexities. Rapid disappearance of spinal activity and abnormal root sleeve visualization were present in two (7.4%) and five (18.5%) patients, respectively.

The sensitivity of RNC varies widely in different case series. One group²⁹ reported four clinically typical cases of SIH that underwent RNC and found that RNC accurately detected and localized a CSF leak in all four patients. All patients experienced symptomatic relief following directed epidural blood patch. Another group³⁰ reported a 93.3% sensitivity of finding the actual CSF leak for RNC in 15 patients with typical symptoms of SIH.

In 57 patients with suspected SIH, Moriyama's group³¹ found direct signs of radioisotope leakage into the spinal epidural space in 25 patients, using RNC. The authors performed a quantitative analysis of radioisotope clearance curves and found that in patients without a radiographically demonstrated radioisotope leak, exponential curves were observed. Clearance in patients with an overt radioisotope leak however, was not a simple exponential curve. The authors concluded that a small CSF leak below the limit of radioisotope cisternography resolution might be detected using the quantitative techniques they described.

Another group³² performed SPECT/CT fusion imaging in RNC for three patients with SIH. Leakage was detected in all three patients. With SPECT/CT, the extradural tracer accumulation could be correlated to an anatomical structure, which was not possible by evaluation of the scintigraphic studies

alone. They concluded that SPECT/CT for RNC was a valuable tool to facilitate the diagnosis of cerebrospinal fluid leakage. One limitation with RNC is that even with a careful lumbar puncture with a small needle, iatrogenic CSF leaks can occur from the procedure. This may produce abnormal results on RNC studies and other imaging modalities (such as MR myelography) at the lumbosacral level. Indirect signs of a CSF leak, such as early visualization of the bladder, may also occur. Therefore, if there are findings restricted to the lumbosacral level with or without indirect signs of a CSF leak, the results should be interpreted with caution³³.

d. CT/MR Myelography

Myelography with iodinated contrast followed by thin-cut CT of the entire spine (CT myelography or CTM) is felt by many to be the study of choice to define the location and extent of a CSF leak^{1,3}. Myelography with intrathecal gadolinium injection followed by MRI can also be performed (MR myelography with intrathecal gad or igMRM)^{1,3,34}. Intrathecal administration of gadolinium is currently an off-label use but current clinical experience suggests that it is safe for igMRM if specifically diluted³⁵. The CSF leaks seen may be very small and single or large, multiple and extensive. Single or multiple meningeal diverticula may also be demonstrated. More recently, non-invasive MRM, or niMRM (no injection of gadolinium) is being increasingly performed³⁰.

With high flow leaks, dynamic studies are recommended and the patient can be injected while in the CT/MR scanner³⁶. With low flow leaks, delayed imaging can be performed (up to 72 hours later) and even after the patient has been up walking. Some authors advocate 3D CTM³⁷.

A study in 2008³⁴ found igMRM to be safe and accurate in SIH. This group evaluated 19 patients with SIH based on ICHD-II criteria and found objective signs of CSF leakage in 89% (17 of 19 patients). In 14 of these patients, the site of the dural tear was shown accurately, while the other three patients showed diffuse contrast leakage and the site of the leak could not be identified. Two of the 19 patients did not demonstrate any signs of a leak. There were no procedure-related complications in the first 24 hours and at 12 month follow-up. An editorial³⁵ discusses igMRM further.

More recently, 14 patients with SIH were assessed for CSF leaks using igMRM³⁸. A CSF leak was found in 9 of the 14 patients (64%), without any complications.

Yoo and colleagues³⁰ compared non-invasive MRM (niMRM) with RNC in its ability to detect the site of CSF leakage. niMRM is a high resolution T2 weighted spinal MRI with fat suppression without intrathecal gad injection that allows good visualization of the CSF. Fifteen patients with SIH were studied. Patients had at least two of the following: 1) orthostatic headache, 2) low CSF opening pressure, and 3) diffuse pachymeningeal enhancement on brain MRI. Non-invasive MRM was also performed in 15 patients without SIH. Two blinded radiologists evaluated the niMRM studies. All patients with a clinical diagnosis of SIH were presumed to have a CSF leak. The sensitivity and specificity of the niMRM for detecting a CSF leak was 86.7% and 86.7% for reader one, and 80.0% and 93.3% for reader two, respectively. The sensitivity of RNC was 93.3%. It concluded that niMRM is an effective tool for detecting the site of a CSF leak.

A group in Japan³⁹ studied 27 patients with direct findings of CSF leakage on RNC with niMRM. The MR visibility of the CSF leakage was graded as definite (leakage clearly visible), possible (leakage poorly seen), or absent (not shown). A CSF leakage was identified in 22 (81.5%) of 27 patients. Of the 22 patients, 16 were graded as definite and six as possible. In the remaining five patients with absent findings, RNC showed only slight radionuclide activity outside of the arachnoid space. They concluded that niMRM can be useful in the detection of CSF leakage.

Wang and colleagues⁴⁰ compared niMRM versus CTM in nineteen patients with SIH. niMRM did not differ from CTM in the detection rates of CSF leaks along the nerve roots (84% vs. 74%, $p = 0.23$), high-cervical retrospinal CSF collections (32% vs. 16%, $p = 0.13$), and epidural CSF collections (89% vs. 79%, $p = 0.20$). However, niMRM demonstrated a wider distribution of spinal levels of CSF leaks (2.2 +/- 1.7 vs. 1.5 +/- 1.5, $p = 0.011$) and a wider distribution of epidural collections (12.2 +/- 5.9 vs. 7.1 +/- 5.8, $p < 0.001$) than CTM. The authors concluded that niMRM is accurate in localizing CSF leaks. This noninvasive technique may be an alternative to CTM and avoids the large amount of radiation required for CTM.

Despite high radiation exposure, CTM has higher spatial resolution than MRI or RNC, and may be useful where a focused evaluation is required. For example, if MR indicates abnormalities in a region of the spine but the site of a CSF leak is not identified, a CTM could be performed focusing only on the area of interest, and thereby limiting the amount of radiation.

e. Digital subtraction myelography

This involves digital subtraction X-rays acquired during intrathecal injection of contrast via lumbar puncture.

A case has been described⁴¹ where spinal MRI demonstrated a large cervicothoracic epidural fluid collection but conventional and dynamic CT myelography failed to localize the dural tear because of rapid equilibration of myelographic contrast between the thecal sac and the extradural collection. Digital subtraction myelography however, precisely localized the CSF leak. This specialized technique may be useful as an adjunct to more commonly used modalities, particularly for high flow leaks.

Orthostatic headaches may occur without evidence of CSF leak(s) on multiple tests. In that case, one must consider a few possibilities, including a very slow leak, which cannot be identified with the current diagnostic modalities, increased compliance of the lower spinal CSF space without actual leak, or an alternate diagnosis^{28,42}.

f. Lumbar Puncture

In SIH, danger of cerebral herniation from lumbar puncture has not been documented. The dural hole made by an LP needle is small, and CSF pressure is already low. However, neuroimaging should be done prior to lumbar puncture to ensure that it would be safe. Aggravation of symptoms can occur after LP, but this occurs only in about 5% and symptoms are generally mild^{1,3}. A smaller needle size and a skilled clinician help to reduce the chances of a post-LP headache⁴³.

Typically, CSF opening pressure is < 6 cm of water, but it can be immeasurable or even negative. It can also be normal in some

cases (quite variable depending on case series). In Watanabe's study¹⁵, 17 patients had CSF OP measurements. Of these, ten were negative, one was zero, one was less than 5 cm of water, and five were within normal range (between 5-20 cm H₂O). Another group¹⁹ analyzed 12 consecutive patients with SIH. All were found to have low CSF OP (0-5 cm H₂O).

Cerebral spinal fluid analysis may be normal or show: lymphocytic pleocytosis, elevated protein, or xanthochromia (due to increased permeability of dilated meningeal blood vessels and decreased CSF flow). In Ferrante's group¹⁹, of 12 patients, seven had elevated protein and four had pleocytosis.

A group in Japan⁴⁴ investigated the association of duration of symptoms with findings on CSF. They analyzed 115 consecutive patients retrospectively with spontaneous CSF leaks demonstrated by cisternography. Patients with symptoms <3 months had more significant abnormalities. Median OP was 8 cm H₂O for those with symptoms <3 months vs. 13 for those with symptoms for longer. Protein concentration was 63 mg/dL vs. 26, and cells per mL were 7.3 vs. 0.7 for the respective groups.

Tables 1 and 2 summarize the diagnostic yield of the various tests based on the available case series.

Before performing tests to localize the CSF leak, consideration could be given to provocative maneuvers just prior to the test. These could include any triggers that bring on the headache, such as valsalva maneuvers (coughing, straining, bending, etc) or sustaining an upright position. It is possible that provocative maneuvers may increase the yield of the tests, but there have been no studies in the literature looking at the role of provocative maneuvers.

II. Management of SIH

No major studies have been done on treatment outcomes for SIH. Many cases resolve spontaneously without specific therapy, but a significant portion of patients can have symptoms that persist from weeks to years.

i. Conservative measures

Bed rest, oral hydration, caffeine intake, and abdominal binders are recommended for SIH but how much they help is

Table 1: Diagnostic yield of enhanced brain and spinal MRI for detection of the indirect signs of SIH based on case series studies

Modality	Diagnostic Yield for indirect signs of SIH
MRI Brain	<ul style="list-style-type: none"> 83% (15/18 pts,¹⁵) 75% (3/4 pts,²⁰) 93% (14/15 pts,²²)
MRI Spine	<ul style="list-style-type: none"> 94% (17/18,¹⁵) 77% (7/9,²⁴)

MRI=magnetic resonance imaging; SIH=spontaneous intracranial hypotension; pts=patients

Table 2: Diagnostic yield of RNC, CTM, intrathecal gad MRM (igMRM), and non-invasive MRM (niMRM) for direct detection of CSF leaks based on case series studies

Modality	Diagnostic yield for direct visualization of CSF leak
RNC	<ul style="list-style-type: none"> • 80% (24/30,²⁷) • 40% (27/67,²⁸) • 100% (4/4,²⁹) • 93.3% (14/15,³⁰) • 44% (25/57,³¹) • 100% (3/3, RNC + SPECT/CT,³²)
CTM	<ul style="list-style-type: none"> • 74% (14/19,⁴⁰)
igMRM	<ul style="list-style-type: none"> • 89% (17/19,³⁴) • 64% (9/14,³⁸)
niMRM	<ul style="list-style-type: none"> • 86% (13/15,³⁰) • 81.5% (22/27,³⁹) • 84% (16/19,⁴⁰)

CSF=cerebral spinal fluid; RNC=radionuclide cisternography; CTM=computed tomography with myelography; MRM=magnetic resonance myelography; SPECT=single-photon emission computed tomography

questionable. They can be helpful in post-dural puncture headaches, where these treatments are derived from. No studies have examined the efficacy of these therapies in SIH. Mineralocorticoids, steroids, IV or oral caffeine, and theophylline can be used, but large studies to evaluate these treatments are lacking⁴⁵⁻⁴⁷.

Most authors agree it is reasonable to try conservative measure for one to two weeks before proceeding with more invasive treatment modalities.

ii. Epidural blood patch

The mainstay of treatment for SIH is the epidural blood patch (EBP): injection of autologous blood into the spinal epidural space. If the EBP is successful, relief of symptoms can be instantaneous or can take hours^{1,3}. Initially 10 to 20 mL of blood is often used, but there are many differences, with some centers injecting as much as the patient can tolerate. Initial EBPs are usually in the lumbar region.

The terms blind and non-directed EBP have both been used to indicate that the level of the leak is not known and the EBP is done empirically, usually in the lumbar region (occasionally thoracic). We will use the term "non-directed EBP" and indicate the area where the EBP has been performed (i.e. lumbar or thoracic). In directed EBPs, the level of the leak is known and the EBP is done at that specific level.

The mechanism by which the EBP works is not known. It likely forms a dural tamponade, thereby sealing the leak. It may also restrict CSF flow and interfere with CSF absorption, and/or change dural resistance/stiffness^{1,3,6,48}. Animal research into how a blood patch might raise CSF pressure has suggested that complex mechanisms may be involved. Research in a rat model

concluded that sealing the dural defect does not correct CSF pressure, at least in the short term, unless an epidural tamponade effect is also maintained⁴⁹. Only epidural injections of whole blood or fibrin glue near the leak produced sustained increases in CSF pressure. Saline injections or anticoagulated blood produced only transient CSF pressure elevations⁴⁹.

Research in a swine model indicated that vascular reflexes may be involved in the immediate relief of headache that can follow epidural injections. After a cervical puncture and drainage of CSF, an immediate, almost doubling, of cerebral blood flow occurred. After a blood injection in the lumbar epidural space far from the leak, the blood flow immediately returned to normal levels⁵⁰.

If the initial non-directed EBP is unsuccessful, a second, larger-volume EBP should be considered (20mL plus), and some recommend a third lumbar EBP before proceeding with localization of the leak and directed EBPs. A minimum of five days between EBPs is advised.

In the post-dural puncture headache (PDPH) literature, a higher volume EBP can have more neurological complications⁵¹, and a lower volume (<20 mL) EBP is recommended. However, in most cases of SIH, the anatomy, dural tears, and CSF dynamics are more complex, and the CSF leaks are usually at higher levels than the lumbar region. A higher volume EBP is felt to be more effective in order to compensate for these complexities.

No complication rates have been published for EBPs. However, when patients with SIH have significant symptoms that interfere with their functioning or quality of life and conservative measures have failed, the potential benefits of an EBP are felt to outweigh the risks.

When the location of the leak is unknown, an initial translaminar lumbar EBP is usually recommended⁵²⁻⁵⁴ and this technique is most familiar to anesthesiologists and interventional radiologists who usually do these procedures. Others advocate for an initial cervicothoracic patch⁵⁵.

During translaminar injection, the patient feels pressure along the spine. Our local practice has been to inject as high a blood volume as the patient can reasonably tolerate, such that they prefer not to continue but are not in distress. This is typically between 25-50mL. The sense of pressure almost immediately improves with termination of the injection, and is dramatically improved within 15-30 minutes, due to redistribution of blood in the epidural space⁵⁶. Injection is also immediately terminated if the patient develops any radicular symptoms, or any other complication.

Many authors perform lumbar EBPs in a prone, steep Trendelenburg position to encourage cephalad spread of the epidural blood, and keep patients in this position for 2-24 hours after the procedure^{53,54,57}. Blood has been shown to coagulate faster than normal when in contact with CSF⁵⁸, so prolonging any patient position for longer than a few hours would seem to be unnecessary if that was the only consideration. Decreasing flow across the leak may be another reason to keep the patient in the Trendelenburg position for longer periods of time. We advise patients to refrain from strenuous activity for several days post-procedure to limit the potential for a sudden rise in CSF pressure to dislodge a stable clot, but recognize that a single cough or sneeze may have greater effect.

Antibiotic prophylaxis for EBP is used or recommended by some centers, but strict attention to sterile technique, proper procedures, and patient selection are the more important factors in preventing EBP related infections. Epidural blood patch is a clean procedure⁵⁹, and the risks of antibiotic related complications outweigh the belief that their use will reduce neuraxial infection rates. Similarly, the practice of taking blood cultures with the blood draw does not guarantee the identification of the responsible organism in the case of post-procedure infection, and broad spectrum antibiotics should always be used when this is initially suspected.

The use of acetazolamide has been suggested by Ferrante to improve the efficacy of the blood patch procedure^{60,61}. While their reasoning is rational, real evidence that acetazolamide pre-treatment improves success does not yet exist. There is also no evidence nor reasonable mechanism that pre-EBP dosing could result in prevention of post-EBP intracranial hypertension when this complication is sometimes quite remote in time from the procedure⁶²⁻⁶⁵. We agree that without likely harm, the suggested mechanism of decreasing CSF flow or pressure across a leak at the time of EBP may make it worth using in appropriate patients.

The use of fluoroscopy and contrast as part of the technique is variably utilized in anesthesia practice, but is prevalent among interventional radiologists. It can be useful to confirm epidural location of the injection and to document the level of and spread of the injection, but it has not been shown to improve efficacy. We encourage use of fluoroscopy and contrast during a blood patch for SIH, but recognize it is not essential for success.

Transforaminal epidural blood patch has been used when the location of the leak has been demonstrated by imaging and translaminar attempts have not been successful^{66,67}. This is usually of lower volume (~2-5mL) but larger volumes have also been injected. We have concerns about the possibility of neurologic injury with transforaminal patches. Because there may be diverticula or other altered anatomy within the affected foramina, this may make fluoroscopic guidance less reliable in avoiding direct injury. Secondary injury due to compromising blood flow in the radicular blood vessels is also a possibility. To our knowledge, these complications have not been reported. Caution should be utilized with this technique, and advanced training, real-time spinal angiograms⁶⁷, and/or CT guidance should be considered.

With our limited understanding of the mechanism by which the EBP is successful, it is difficult to weigh the risks of the procedure with regard to the volume of blood to inject⁵¹, the most appropriate injection level, timing of the EBP, and use of multiple EBPs.

Complications following EBP are rare, but numerous case reports of complications exist and some are potentially serious⁶⁸. Therefore, undertaking an EBP or multiple EPB's need to be carefully considered and weighed against the patient's disability from headache. Patients should expect some neck or back pain that may last a few days to several weeks. This can be somewhat remediated through the use of ice, heat and mild analgesics as it may result from blood tracking back into the muscular and subcutaneous tissues. Transient bradycardia and temperature elevation has also been observed. There is potential for dural puncture and worsening of the patient's headache. The utilization of EBP for this complication would be identical to PDPH under

other circumstances. Other much less frequent risks include persistent hematoma or abscess, delayed neurologic injury, chronic back pain, arachnoiditis (possibly from blood crossing into the CSF), intracranial hypertension with neurological deterioration⁶⁹, acute meningeal irritation, and post-procedure visual impairment⁷⁰. Progressive severe back or radicular pain after EBP is always abnormal, and should be promptly evaluated to exclude neuraxial hematomas and other serious etiologies. Contraindications to EBP include local infection at the proposed site of injection, sepsis, coagulopathy and inability to cooperate. Review papers often report that an initial EBP of 10 - 20 mL will relieve symptoms in one third to one half of patients. A second, larger volume EBP is said to result in an additional 20 to 33% of patients experiencing long-term resolution of symptoms. With further attempts, up to 50% of the remaining patients are said to respond^{1,3,71}. However, the success rates are quite variable depending on the case series.

One of the largest case series to date⁷² observed 111 patients with SIH diagnosed according to the ICHD-II classification. Of these, 57 patients were treated with non-directed lumbar EBPs. Of these, 50 patients underwent EBP using autologous blood mixed with contrast medium (1 mL Gd in 12 patients and 5 mL iopamidol in 38 patients). All patients were also premedicated with acetazolamide (250 mg given 18 hours and 6 hours before EBP was performed). Complete symptom resolution occurred in 89.5% after the first EBP, 7% after the second EBP, and 3.5% after the third EBP. All patients achieved complete recovery, an unusually high success rate. This may have been due to the exclusion of atypical forms of SIH, which may not have been diagnosed by the ICHD-II classification, as well as differences in the procedure and volume of EBP. Patients remained in 30° Trendelenburg for 1 hour pre and 24 hours post-procedure, and a relatively large-volume patch (15-35 mL blood) was used.

Berroir et al reported on 30 patients with a clinical diagnosis of SIH⁷³. All had orthostatic headache. Some had MRI changes of SIH, and some did not. None had a lumbar puncture to measure CSF OP or imaging to localize the leak. Non-directed lumbar EBPs were performed in all with a complete cure in 77% of patients; 57% after one EBP and an additional 20% after the second EBP. The authors concluded that SIH with typical orthostatic headache can be diagnosed without lumbar puncture and cured by early EBP in most patients.

A group in Taiwan⁷⁴ retrospectively reviewed 11 SIH cases. Eight of their patients received non-directed lumbar EBPs and six of these were symptom-free within two weeks. Two patients received spinal MRI immediately after the EBP, and this revealed that most of the blood had spread to the upper cervical area from the lumbar injection.

Another group in France⁷⁵ reported success with non-directed lumbar EBPs in five out of six consecutive patients with SIH. EBPs were performed at the L1-2 level. Three of six patients required one EBP, one required two EBPs, and one required three EBPs. In the sixth patient, where the EBP was considered unsuccessful, an incomplete response was still seen and CT myelogram demonstrated a large CSF leak. The authors recommend up to three non-directed EBPs before proceeding with other treatments.

A recent case series⁷⁶, reported that 13 of 15 patients or 86% had success with non-directed lumbar EBPs: 73% had complete symptom resolution after one EBP, and 13% with two EBPs.

A case report⁷⁷ of a 39-yr-old man who presented with a history and diagnostic imaging findings consistent with SIH is instructive. Headache was unrelieved by a 20 mL non-directed lumbar EBP. Two weeks later, a non-directed EBP of 45 mL administered in the lower thoracic epidural space achieved partial relief. A third non-directed EBP one month after the first one of 32 mL of blood injected into the mid-thoracic epidural space resulted in complete headache resolution. The authors concluded that the ideal volume of blood to inject for EBP for maximal effectiveness is unknown, and suggested a volume titrated to patient symptoms.

A group of authors in Italy have proposed a novel hypothesis in regards to SIH and EBPs⁷⁸. They reported 28 patients with SIH who received a non-directed EBP with autologous blood and fibrin glue in the lumbar region, despite various locations of CSF leaks. At three years follow-up (data available for 11 patients) 83.3% were completely symptom-free and 8.3% had sporadic orthostatic headache. The authors proposed that in the SIH syndrome, the dural leak, even in those cases in which it can be clearly identified, is not the primary cause of the disorder. They proposed that negative pressure in the inferior vena cava, which develops while standing or walking, results in a negative pressure in the epidural space which tends to draw CSF out of the subarachnoid space along nerve roots. This might explain why a number of authors have reported finding simultaneous multiple CSF leaks⁴⁰. The goal of the EBP then may not be to seal CSF leaks directly, but instead to help reverse the CSF-epidural space pressure gradient along the entire cord. Other authors have questioned the theory's validity^{72,79}.

The Mayo clinic evaluated the efficacy of EBPs in 25 consecutive patients with SIH⁷¹. Patients received either non-directed lumbar or directed EBPs. Overall, they found that 9 of 25 patients (36%) responded well to the first EBP, 5 of 15 (33%) had good results with a second EBP, and 4 of 8 patients (50%) who received three or more EBPs (range 3-6, mean 4) had a good response. Of the 49 EBPs given, 24 were at the level of the leak.

There are several case reports of successful SIH treatment with directed EBPs in the thoracic and cervical region⁸⁰⁻⁸². For higher cervical EBPs, some authors^{80,82} recommend delivery of the autologous blood via an epidural catheter inserted from a lower cervical spinal level. Some also recommend doing the procedure under CT guidance^{81,82}.

In Wang's study of 19 patients, 14 patients received directed EBPs (mean volume 24 mL). Ten of the 14 patients or 71% experienced sustained relief after the first attempt⁴⁰. The EBPs were well-tolerated with only minor and transient adverse events (tightness in the shoulder, tinnitus, band like paresthesia at the mid-thoracic level, and upper back pain) in six patients (35%).

A Korean group evaluated the efficacy of directed EBPs versus non-directed EBPs⁸³. Thirty-one patients received a directed EBP and 25 received a non-directed EBP (19 at the lumbar spine and 6 in the upper thoracic area). The rationale for choosing the lumbar versus upper thoracic area for the non-directed EBP was not explained. This study was not blinded or randomized and was retrospective in design. The decision to have a directed or non-directed EBP was based on the treating physician's preference and the CSF leak site was not identified in the group receiving a non-directed EBP. Also, the non-directed EBP group received 9-20 mL of autologous blood, the directed

EBP group received 10-15 mL of autologous blood mixed with contrast medium (1-2 mL iopamidol) under fluoroscopic guidance. Therefore this study must be interpreted with caution as the patient groups were not comparable. A good outcome was defined as complete recovery or minimal symptoms and a poor outcome was persistent symptoms requiring a repeat EBP. Thirty-one patients received a targeted EBP, and 27 (87%) had a good outcome. The other four patients had a repeat directed EBP and went on to have a good outcome. Of 25 patients with a non-directed EBP, 13 (52%) had a good outcome. No procedure-related complications were encountered, but it should be noted that targeted EBPs may be associated with higher risks, including compression of the spinal cord and nerve roots, intrathecal blood injection, and chemical meningitis.

iii. Fibrin glue placement

Computed tomography-guided percutaneous fibrin sealant injections can be done at the site of a leak if a directed EBP is unsuccessful. It can be effective in patients failing one or more directed EBPs⁸⁴. Generally "Tissucol Immuno" (bovine) fibrin glue is used. This has been shown effective in a swine model⁸⁵.

Fibrin glue (fibrin sealant) mimics blood coagulation by forming a stable fibrin clot that can assist hemostasis and wound healing⁸⁴. Side effects include infection or bleeding at the site, arachnoiditis, or fibrous scar formation. Rarely sensitization and anaphylaxis can occur, so three to six months is recommended between injections. Pre-treatment with diphenhydramine may be helpful.

In a report of four patients with intractable postural headaches⁶⁶ treated with percutaneous fibrin sealant, three had CSF leaks in the lower cervical spine and one in the lower thoracic spine. Fibrin sealant (4-20 mL) was injected at the site of the leak. Two patients had complete resolution of symptoms within a few days and did not require surgery. The authors conclude: "percutaneous placement of a fibrin sealant is a safe, minimally invasive treatment for spontaneous spinal CSF leaks".

iv. Neurosurgery

Surgery should be considered when the following criteria are met:

- Symptoms are severe enough to warrant surgical intervention
- Site(s) of leak have been identified
- Symptoms have been refractory to other measures

Surgery is often, but not always, successful in relieving symptoms due to a localized CSF leak. Leaking meningeal diverticula can be ligated with metal aneurysm clips or the leak can be sealed with a muscle pledget. Gel foam and fibrin sealant can be used around the leak. Occasionally, the dural rent can be repaired with primary suturing^{6,86}.

Cohen-Gadol and colleagues⁸⁷ described their surgical experience with thirteen consecutive patients with SIH. Eight patients demonstrated one site for CSF leak, three patients showed two, and two patients had multiple sites of leakage. During surgery, the site of the leak could not be seen in four patients. The other nine patients had variable procedures, including primary closure of a meningeal diverticulum, packing of the epidural space with muscle, fibrin glue and gelfoam mixed

with patient’s own blood, and ligation of non-appendicular nerve roots. Eight patients had resolution of symptoms, three became significantly better, and two had transient improvement. Average follow-up was 20 months. The authors concluded that surgery for CSF leak was not straightforward and image-proven leaks could be difficult to identify at surgery. However, even if primary closure was not possible, adjuvant techniques could be effective.

Schievink described a novel technique for refractory SIH: lumbar dural reduction surgery⁸⁸. A lumbar laminectomy was performed with resection of a strip of dura, followed by closure of the dural defect in a patient with an extensive cervicothoracic leak and intractable headaches who had failed multiple other procedures. The patient had major symptom improvement at one year follow-up. Schievink concluded that “dural reduction surgery may be considered in carefully selected patients with intracranial hypotension”.

Table 3 summarizes the efficacy of the various procedures based on the available case series

RECOMMENDATIONS

The first step in treating SIH is ensuring proper diagnosis. Typical cases of SIH can be diagnosed clinically, although brain CT and/or MRI are useful in ruling out other causes of headache. Brain MRI with contrast can confirm the clinical diagnosis, although it will be normal in a small minority of patients with

SIH. Atypical cases will need neuroimaging to establish the diagnosis.

The investigation and management of SIH is controversial, and approaches vary from center to center. In considering the options available, several considerations should be kept in mind.

1. Although it may seem more satisfying to fully investigate a patient and establish a firm anatomical diagnosis with localization of the CSF leak, the clinical response rate to non-directed lumbar epidural blood patches is high. It is questionable whether the time delay, expense, and in some cases radiation exposure of further testing to localize the leak have a positive risk/benefit ratio in the initial management of patients with clinically typical SIH, or SIH confirmed by brain MRI scan.
2. The main reason for localizing the leak in the initial investigation of patients with SIH is to allow for a directed blood patch as opposed to a non-directed blood patch. Although there is some evidence that directed blood patches may have higher response rates, at the present time this evidence is not strong.
3. Most spontaneous CSF leaks occur in the lower cervical – upper thoracic area. One could argue that initial epidural blood patches given prior to localization of the leak should be given at that level rather than at the lumbar level. Epidural blood patches at higher spinal levels do however require a higher level of expertise, and may have greater potential for adverse events, although the relative risks of blood patches at higher spinal levels as compared to those at the lumbar level have not been established.

Below is a proposed approach for the investigation and management of SIH patients. This approach is also summarized in Figures 1 and 2. It starts by dividing patients into typical and atypical cases of SIH.

Typical SIH cases

Clinically typical SIH can be defined as clear orthostatic headache that exacerbates within minutes of assuming the upright posture, and is relieved within 30 minutes of lying down so that the patient has no headache or only a mild headache. The headache should be a new headache syndrome for the patient, and unlike previous headaches. It should have a definable time of onset. There should be no papilloedema and no focal signs on neurological examination to suggest other causes of headache.

- In typical SIH, brain MRI with gad is helpful to confirm the diagnosis, but should not delay treatment. If MRI is not readily available, a head CT to rule out other pathologies is helpful. At the same time, the patient can be advised to take conservative measures, including strict bed rest for several days to encourage sealing over of the leak, and liberal fluid and caffeine intake to reduce symptoms.
- If conservative measures have not been helpful within one to two weeks, the patient should have a non-directed lumbar EBP, with as high a volume of blood as tolerated. Whether MRI brain shows signs of SIH or is normal, typical cases of SIH should proceed to this step. If this is successful, the patient can be followed as needed. If it is not successful, a second non-directed lumbar EBP should be done after a minimum of five days with as high a volume as possible. If

Table 3: Efficacy of the various procedures based on case series studies

Procedure	Efficacy or success of procedure
Non-directed EBP*	<ul style="list-style-type: none"> • 100% (57 pts, 50 received blood + contrast: 89.5% after 1 EBP, 7% after 2 EBPs, 3.5% after 3 EBPs⁷²) • 77% (23/30 pts, 57% after 1 EBP, 20% after 2 EBPs⁷³) • 75% (6/8 pts⁷⁴) • 83% (5/6, at L1-2, 3 pts: 1 EBP, 1 pt: 2 EBPs, 1 pt: 3 EBPs⁷⁵) • 86% (13/15 pts: 73% after 1 EPB, 13% after 2 EBPs⁷⁶) • 83% (9/11, EBP + fibrin glue⁷⁸) • 52% (13/25⁸³)
Directed EBP	<ul style="list-style-type: none"> • 71% (10/14 pts⁴⁰) • 87% (27/31⁸³)
Fibrin Glue	<ul style="list-style-type: none"> • 50% (2/4 pts⁶⁶)
Neurosurgery	<ul style="list-style-type: none"> • 62% (8/13 pts): complete resolution of symptoms, 23% (3/13 pts): significant improvement, and 15% (2/13 pts): transient resolution of symptoms⁸⁷

* Reference 71 is not listed as it combined non-directed and directed EBPs (epidural blood patch) without distinguishing which led to success

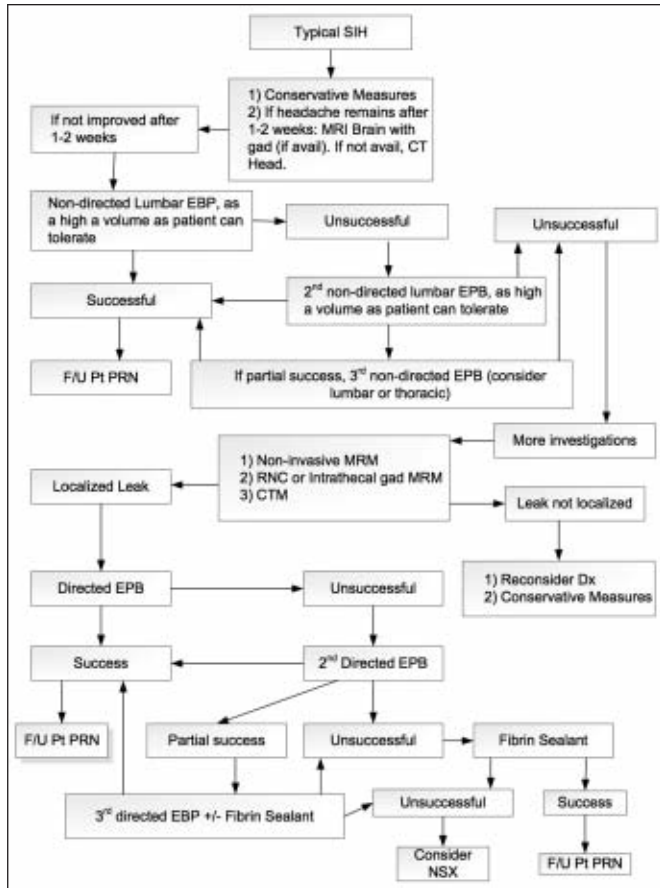


Figure 1: Approach to Diagnosis and Management of Typical SIH

- this provides partial benefit but the patient relapses, a third non-directed lumbar or thoracic EBP should be considered. However, if the first and second non-directed EBPs provide no significant headache relief, then a third EBP is likely not warranted.
- If three non-directed EPBs have not provided lasting relief, or if two EBPs have provided no significant relief, the next step would be to try to localize the site of the CSF leak. The modality to choose first depends on test availability and patient characteristics. A pacemaker would prohibit use of MRI, and desire to avoid radiation would indicate avoidance of a CT myelogram, etc. If all modalities are available, a non-invasive MR myelogram would be the test of choice, given its non-invasiveness, lack of radiation, and similar yield to CT myelography for finding the CSF leak. If this test does not provide the needed information, an MR myelogram with intrathecal gadolinium or RNC would be recommended next. A CT myelogram would be used primarily if these tests are not successful in demonstrating the leak, as it involves significant radiation exposure. Digital subtraction myelography, if available, may be considered for localizing fast CSF leaks.
 - If the above tests fail to localize the CSF leak, then there is not much that can be done besides watchful waiting and symptomatic therapy, (i.e. caffeine and analgesics). A course

of steroids can be considered although no large studies have assessed their efficacy in SIH. SIH can spontaneously resolve over time. If the patient's symptoms persist, repeating a non-directed EBP or tests to localize the leak after several months may be useful. The diagnosis should also be reviewed and other causes of postural headache considered, particularly if none of the tests show any signs of SIH.

- If tests localize the leak(s), a directed EBP is the next step. If the first directed EBP is not effective, a second attempt is warranted. If this is also not effective, a directed percutaneous fibrin sealant patch could be considered. If there is partial success with a second directed EBP, then a third could be done before proceeding to fibrin sealant. Finally, if fibrin sealant is unsuccessful, neurosurgery is likely the next best option.

Atypical Cases of SIH

Clinically atypical SIH can include patients with new daily persistent headache and patients with thunderclap headache in whom no other etiology has been found. It can also include patients in whom the influence of changes in posture on the headache are suggestive of SIH but are not as clear cut as in typical SIH cases. Patients with atypical SIH can also develop

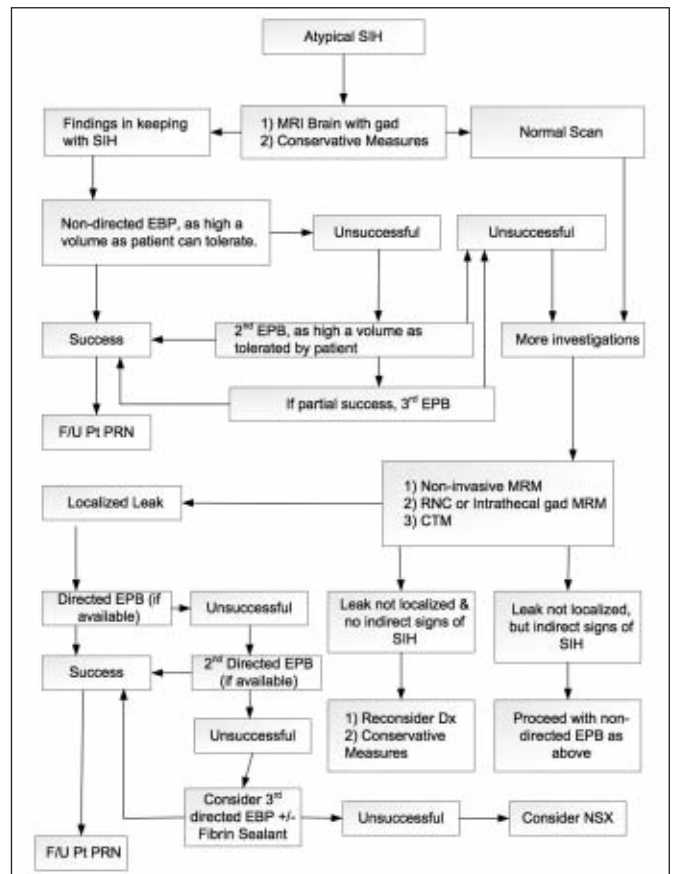


Figure 2: Approach to Diagnosis and Management of Atypical SIH

unusual symptoms such as dementia and a reduced level of consciousness.

When the clinical presentation is atypical but SIH is suspected, the diagnosis needs to be confirmed before patients are exposed to procedures such as an EBP. The first step would be a brain MRI with gad to provide evidence that SIH is the correct diagnosis. An MRI of the entire spine could also be useful early, as a proportion of patients with SIH have a normal brain MRI. Adding the spinal images allows for a higher yield in confirming the diagnosis.

If brain MRI and/or spinal MRI demonstrate clear signs of SIH, despite an atypical clinical picture, non-directed EBPs can be performed as described above.

- If non-directed EBPs are unsuccessful or brain and / or spinal MRI do not support a diagnosis of SIH but SIH is still suspected clinically, tests to localize the leak are appropriate. The sequence of tests would be the same as recommended above. In atypical SIH, even if a test does not localize the leak, it can be helpful in confirming the diagnosis by showing indirect signs of SIH (e.g. early renal uptake in RNC).
- If the leak cannot be localized but the tests show indirect signs of SIH, the patient can proceed with non-directed EBPs, as detailed above.
- If the leak cannot be localized and the tests do not indicate any signs of SIH, then similar to the typical cases mentioned above, reinvestigation after a number of months may be useful. However, in atypical cases, one must reconsider the accuracy of the diagnosis even more strongly, given that neither the clinical picture nor the tests are in keeping with SIH.

SUMMARY OF RECOMMENDATIONS

1. Most patients with clinically typical SIH can be managed conservatively with bed rest and symptomatic headache treatment (analgesics, caffeine) for up to one to two weeks to see if spontaneous improvement will occur.
2. Given the broad differential diagnosis for headache, when SIH is suspected, neuroimaging should be done to exclude other diagnoses. A gadolinium enhanced MRI scan is the imaging modality of first choice, as it may also provide direct support for the presence of SIH. If MRI is unavailable, CT can be used to help exclude other causes for the patient's headache.
3. For patients with clinically typical SIH, a brain MRI scan with gadolinium enhancement should be considered and done in a timely fashion to confirm the diagnosis.
4. Lumbar puncture with a CSF pressure measurement can be done to confirm the diagnosis of SIH, but brain MRI scan with gadolinium enhancement is the preferred first test as it is less invasive, and lumbar puncture may show a CSF pressure within normal limits despite the presence of a CSF leak.
5. For patients with clinically typical SIH, with or without brain MRI confirmation of the diagnosis, up to three non-directed blood patches at least five days apart can be considered before tests to localize the leak are done.
6. If patients with suspected SIH have not responded at all to two non-directed blood patches, investigation(s) to demonstrate the CSF leak should be pursued.
7. Non-directed blood patches should be of as high a volume as tolerated by the patient.
8. As most spontaneous CSF leaks are at the lower cervical or upper thoracic level, patients should be kept in the Trendelenburg position for at least two hours after the blood patch procedure, and kept recumbent on their back for an additional two hours if possible. Patients should remain in bed as much as possible over the next 24 hours, and avoid strenuous activity for one week.
9. Patients with atypical symptoms in whom a diagnosis of SIH is suspected should be investigated with a brain MRI scan with gadolinium enhancement and if necessary a spinal MRI scan to look for confirmatory evidence that a CSF leak is present before proceeding with blood patch procedures.
10. For patients with atypical symptoms in whom a diagnosis of SIH is suspected and in whom brain and/or spinal MRI scans are normal, investigations to detect the site of a CSF leak should be pursued if warranted by the clinical features and lack of another diagnosis.
11. The first investigation of choice for determining the site of a CSF leak is a niMRM, as this test is non-invasive and does not expose the patient to radiation.
12. MRM with intrathecal gad (igMRM) or a radionuclide cisternogram should be considered if the niMRM is unavailable or does not reveal a CSF leak.
13. For patients where a CSF leak is strongly suspected clinically or where brain and / or spinal MRI scans indicate that a leak is present, or who have shown indirect signs of a CSF leak on other investigations, but where niMRM, igMRM, and a radionuclide cisternogram have failed to show the site of the leak, a CT myelogram, can be considered.
14. For symptomatic patients where the site of a CSF leak has been demonstrated, a directed blood patch at the level of the leak should be considered. Alternatively, if not tried previously, non-directed blood patches can be administered first, followed by directed blood patches later if necessary. However, there is some evidence that the chances of success are better with a directed blood patch.
15. For a patient where the site of the CSF leak has been demonstrated, if directed blood patches have failed one or more patches utilizing fibrin glue can be considered.
16. For patients where directed patches with fibrin glue have been unsuccessful, neurosurgical closure of the CSF leak should be considered.

FUTURE RESEARCH

Large multi-center randomized studies are needed both in the diagnosis and management of SIH. More information is needed on which tests are the most useful in localizing the site of a CSF leak. In addition, standard protocols need to be established so that the same type of sequences and scans are done at different centers.

Research is also required to determine how EBPs, fibrin placement and neurosurgery can be optimized in SIH management.

Finally, more knowledge is needed to improve management of patients where a diagnosis of SIH appears clinically likely but diagnostic tests are negative.

REFERENCES

1. Schievink WI. Spontaneous spinal cerebrospinal fluid leaks and intracranial hypotension. *JAMA*. 2006;295(19):2286-96.
2. Headache classification subcommittee of the international headache society. The international classification of headache disorders: 2nd Edition. *Cephalalgia*. 2004;24 Suppl 1:9-160.
3. Schievink WI, Maya MM, Louy C, Moser FG, Tourje J. Diagnostic criteria for spontaneous spinal CSF leaks and intracranial hypotension. *AJNR Am J Neuroradiol*. 2008 May;29(5):853-6. Epub 2008 Feb 7.
4. Huntoon MA, Watson JC. Intracranial hypotension following motor vehicle accident: an overlooked cause of post-traumatic head and neck pain? *Pain Pract*. 2007;7(1):47-52.
5. Ishikawa S, Yokoyama M, Moriyama E, et al. Epidural blood patch therapy for chronic whiplash associated disorder. *IARS Abstracts*. Available from: <http://www.abstractsonline.org/viewer/viewAbstractPrintFriendly.asp>
6. Mokri B. Headache associated with low CSF pressure. *Medlink Neurology*. Available from: www.medlink.com. April 2006.
7. Schwedt TJ, Dodick DW. Spontaneous intracranial hypotension. *Curr Pain Headache Rep*. 2007 Feb;11(1):56-61.
8. Balgera R, Rigamonti A, Sozzi G, Agostoni E. An atypical case of spontaneous intracranial hypotension. *Neurol Sci*. 2009 Feb;30(1):71-3.
9. Matharu MS, Schwedt TJ, Dodick DW. Thunderclap headache: an approach to a neurologic emergency. *Curr Neurol Neurosci Rep*. 2007 Mar;7(2):101-9.
10. Ferrante E, Savino A. Thunderclap headache caused by spontaneous intracranial hypotension. *Neurol Sci*. 2005 May;26 Suppl 2:s155-7.
11. Mokri B, Atkinson JLD, Piepgras DG. Absent headache despite CSF volume depletion (intracranial hypotension). *Neurology*. 2000 Dec 12;55(11):1722-4.
12. Mokri B, Aksamit AJ, Atkinson JLD. Paradoxical postural headaches in cerebrospinal fluid leaks. *Cephalalgia*. 2004;24:883-7.
13. Mokri B, Low, PA. Orthostatic headaches without CSF leak in postural tachycardia syndrome. *Neurology*. 2003 Oct 14;61(7):980-2.
14. Leep Hunderfund AN, Mokri B. Orthostatic headache without CSF leak. *Neurology*. 2008 Dec 2;71(23):1902-6.
15. Watanabe A, Horikoshi T, Uchida M, Koizumi H, Yagishita T, Kinouchi H. Diagnostic value of spinal MR imaging in spontaneous intracranial hypotension syndrome. *AJNR Am J Neuroradiol*. 2009 Jan;30(1):147-51. Epub 2008 Sep 3.
16. Haritanti A, Karacostas D, Drevlengas A, et al. Spontaneous intracranial hypotension: Clinical and neuroimaging findings in six cases with literature review. *Eur J Radiol*. 2009 Feb;69(2):253-9.
17. Tosaka M, Sato N, Fujimaki H, et al. Diffuse pachymeningeal hyperintensity and subdural effusion/hematoma detected by fluid-attenuated inversion recovery MR imaging in patients with spontaneous intracranial hypotension. *AJNR Am J Neuroradiol*. 2008 Jun;29(6):1164-70. Comment: *AJNR Am J Neuroradiol*. 2009 Mar;30(3):E41; author reply E42.
18. Chiapparini L, Ciceri E, Nappini S, et al. Headache and intracranial hypotension: neuroradiological findings. *Neurol Sci*. 2004 Oct;25 Suppl 3:S138-41.
19. Ferrante E, Savino A, Sances G, Nappi G. Spontaneous intracranial hypotension syndrome: report of twelve cases. *Headache*. 2004 Jun;44(6):615-22.
20. Schoffer KL, Benstead TJ, Grant I. Spontaneous intracranial hypotension in the absence of magnetic resonance imaging abnormalities. *Can J Neurol Sci*. 2002 Aug;29(3):253-7.
21. Ferrante E, Riva M, Gatti A, et al. Intracranial hypotension syndrome: neuroimaging in five spontaneous cases and etiopathogenetic correlations. *Clin Neurol Neurosurg*. 1998 Mar;100(1):33-9.
22. Lin WC, Lirng JF, Fuh JL, et al. MR findings of spontaneous intracranial hypotension. *Acta Radiol*. 2002 May;43(3):249-55.
23. Chen CJ, Lee TH, Hsu HL, Tseng YC, Wong YC, Wang LJ. Spinal MR findings in spontaneous intracranial hypotension. *Neuroradiology*. 2002 Dec;44(12):996-1003.
24. Chiapparini L, Farina L, D'Incerti L, et al. Spinal radiological findings in nine patients with spontaneous intracranial hypotension. *Neuroradiology*. 2002 Feb;44(2):143-50; discussion 151-2.
25. Farb RI, Forghani R, Lee SK, Mikulis DJ, Agid R. The venous distension sign: a diagnostic sign of intracranial hypotension at MR Imaging of the brain. *AJNR Am J Neuroradiol*. 2007 Sept;28:1489-93.
26. Shankar JJ, Chakraborty S, Lum C. The venous hinge - An objective sign for the diagnosis and follow-up of treatment in patients with intracranial hypotension syndrome. *Neuroradiology*. 2009 Jul;51(7):453-6.
27. Hyun SH, Lee KH, Lee SJ, et al. Potential value of radionuclide cisternography in diagnosis and management planning of spontaneous intracranial hypotension. *Clin Neurol Neurosurg*. 2008 Jul;110(7):657-61.
28. Morioka T, Aoki T, Tomoda Y, et al. Cerebrospinal fluid leakage in intracranial hypotension syndrome: usefulness of indirect findings in radionuclide cisternography for detection and treatment monitoring. *Clin Nucl Med*. 2008 Mar;33(3):181-5.
29. Thomas DL, Menda Y, Graham MM. Radionuclide cisternography in detecting cerebrospinal fluid leak in spontaneous intracranial hypotension: a series of four case reports. *Clin Nucl Med*. 2009 Jul;34(7):410-16.
30. Yoo HM, Kim SJ, Choi CG, et al. Detection of CSF leak in spinal CSF leak syndrome using MR myelography: correlation with radioisotope cisternography. *AJNR*. 2008 Apr;29(4):649-54.
31. Moriyama E, Ogawa T, Nishida A, Ishikawa S, Beck H. Quantitative analysis of radioisotope cisternography in the diagnosis of intracranial hypotension. *J Neurosurg*. 2004 Sep;101(3):421-6.
32. Novotny C, Pötzi C, Asenbaum S, Peloschek P, Suess E, Hoffmann M. SPECT/CT fusion imaging in radionuclide cisternography for localization of liquor leakage sites. *J Neuroimaging*. 2009 Jul;19(3):227-34.
33. Sakurai K, Nishio M, Sasaki S, et al. Post puncture CSF leakage: a potential pitfall of radionuclide cisternography. *Neurology*. 2010 Nov 9;75(19):1730-4.
34. Albayram S, Kilic F, Ozer H, Baghaki S, Kocer N, Isak C. Gadolinium-enhanced MR cisternography to evaluate dural leaks in intracranial hypotension syndrome. *AJNR Am J Neuroradiol*. 2008 Jan;29(1):116-21.
35. Dillon WP. Intrathecal gadolinium: its time has come. *AJNR Am J Neuroradiol*. 2008 Jan;29:1-4.
36. Luetmer PH, Mokri B. Dynamic CT myelography: a technique for localizing high-flow spinal cerebrospinal fluid leaks. *AJNR Am J Neuroradiol*. 2003 Sep;24(8):1711-14.
37. Fujimaki H, Saito N, Tosaka M, Tanaka Y, Horiguchi K, Sasaki T. Cerebrospinal fluid leak demonstrated by three-dimensional computed tomographic myelography in patients with spontaneous intracranial hypotension. *Surg Neurol*. 2002 Sep-Oct;58(3-4):280-4; discussion 284-5.
38. Vanopdenbosch LJ, Dedeken P, Casselman JW, Vlaminck S. MRI with intrathecal gadolinium to detect a CSF leak: a prospective open-label cohort study. *J Neurol Neurosurg Psychiatry*. 2011;82:456-8.
39. Tomoda Y, Korogi Y, Aoki T, et al. Detection of cerebrospinal fluid leakage: Initial experience with three-dimensional fast spin-echo magnetic resonance myelography. *Acta Radiol*. 2008 Mar;49(2):197-203.
40. Wang YF, Lirng JF, Fuh JL, Hseu SS, Wang SJ. Heavily T2-weighted MR myelography vs. CT myelography in spontaneous intracranial hypotension. *Neurology*. 2009 Dec 1;73(22):1892-8.
41. Hoxworth JM, Patel AC, Bosch EP, Nelson KD. Localization of a rapid CSF leak with digital subtraction myelography. *AJNR Am J Neuroradiol*. 2009 Mar;30(3):516-19.
42. Leep Hunderfund AN, Mokri B. Orthostatic headache without CSF leak. *Neurology*. 2008 Dec 2;71(23):1902-6.
43. Turnbull DK, Shepherd DB. Post-dural puncture headache: pathogenesis, prevention and treatment. *Br J Anaesth*. 2003;91(5):718-29.

44. Ohwaki K, Yano E, Ishii T, Takanashi S, Nakagomi T. Symptom predictors of cerebrospinal fluid leaks. *Can J Neurol Sci.* 2008 Sep;35(4):452-7.
45. Hannerz J, Dahlgren G, Irestedt L, Meyerson B, Ericson K. Treatment of idiopathic intracranial hypotension: cervicothoracic and lumbar blood patch and peroral steroid treatment. *Headache.* 2006 Mar;46(3):508-11.
46. Gentile S, Giudice RL, Martino PD, Rainero I, Pinessi L. Headache attributed to spontaneous low CSF pressure: report of three cases responsive to corticosteroids. *Eur J Neurol.* 2004 Dec;11(12):849-51.
47. Pascual LF, Santos S, Escalza I, Iñiguez C, Morales-Asín F. Spontaneous intracranial hypotension: quick clinical and magnetic resonance imaging response to corticosteroids, a case report. *Headache.* 2002 May;42(5):359-61.
48. Fichtner J, Fung C, Z'Graggen W, et al. Lack of increase in intracranial pressure after epidural blood patch in spinal cerebrospinal fluid leak. *Neurocrit Care.* 2012 Jun;16(3):444-9.
49. Kroin SJ, Nagalla SKS, Buvanendran A, McCarthy RJ, Tuman KJ, Ivankovich AD. The mechanisms of intracranial pressure modulation by epidural blood and other injectates in a postdural puncture rat model. *Anesth Analg.* 2002;95:423-9.
50. Boezaart AP. Effects of cerebral spinal fluid loss and epidural blood patch on cerebral blood flow in swine. *Reg Anesth Pain Med.* 2001;26:401-6.
51. Diaz JH, Weed JT. Correlation of adverse neurological outcomes with increasing volumes and delayed administration of autologous epidural blood patches for postdural puncture headaches. *Pain Pract.* 2005 Sep;5(3):216-22.
52. Warwick WI, Neal JM. Beyond spinal headache: prophylaxis and treatment of low-pressure headache syndromes. *Reg Anesth Pain Med.* 2007;32:455-61.
53. Malone RE, Love JN. Spontaneous intracranial hypotension: case report and relevant review of the literature. *J Emerg Med.* 2007;4:371-4.
54. Ferrante E, Arpino I, Citterio A. Is it a rational choice to treat with lumbar epidural blood patch headache caused by spontaneous cervical CSF leak? *Cephalalgia.* 2006;26:1245-6.
55. Hannerz J, Dalgren G, Irestedt L, Meyerson B, Ericson K. Treatment of idiopathic intracranial hypotension: cervicothoracic and lumbar patch and peroral steroid treatment. *Headache.* 2006;46:508-11.
56. Beards SC, Jackson A, Griffiths AG, Horsman EL. Magnetic resonance imaging of extradural blood patches: appearances from 30 min to 18 hr. *Br J Anaesth.* 1993;71:182-8.
57. Schievink WI. Spontaneous spinal cerebrospinal fluid leaks. *Cephalalgia.* 2008;28:1347-56.
58. Cook MA, Watkins-Pitchford JM. Epidural blood patch: a rapid coagulation response. *Anesth Analg.* 1990;70(5):567-8.
59. Mangam AJ, Horan TC, Pearson ML, Silver LC, Jarvis WR. The hospital infection control practices advisory committee. Guideline for prevention of surgical site infection, 1999. *Infect Control Hosp Epidemiol.* 1999;20(4):47-78.
60. Ferrante E. Epidural blood patch in Trendelenburg position pre-medicated with acetazolamide to treat spontaneous intracranial hypotension. *Eur J Neurol.* 2010;17:715-19.
61. Ferrante E. Coma resulting from spontaneous intracranial hypotension treated with the epidural blood patch in the Trendelenburg position pre-medicated with acetazolamide. *Clin Neurol Neurosurg.* 2009;111:699-702.
62. Mokri B. Intracranial hypertension after treatment of spontaneous cerebrospinal fluid leaks. *Mayo Clin Proc.* 2002 Nov;77(11):1241-6.
63. Cestari DM, Rizzo III JF. Intracranial hypertension following epidural blood patch. *Neurology.* 2003 Nov (1 of 2);61:1303.
64. Sperry RJ, Gartrell A, Johnson JO. Epidural blood patch can cause acute neurologic deterioration. *Anesthesiology.* 1995;82:303-5.
65. Philipps J, Busse O. From low to high: Late-onset intracranial hypertension after treatment of spontaneous intracranial hypotension. *J Neurol.* 2007 Jul;254(7):956-7.
66. Schievink WI, Maya MM, Moser FM. Treatment of spontaneous intracranial hypotension with percutaneous placement of a fibrin sealant. *J Neurosurg.* 2004;100:1098-100.
67. Walega D, McComb E, Rosenow J. Bilateral cervicothoracic transforaminal blood patches for persistent headache from spontaneous intracranial hypotension. *Clin J Pain.* 2011;27:357-64.
68. Banks S, Paech M, Gurrin L. An audit of epidural blood patch after accidental dural puncture with a Tuohy needle in obstetric patients. *Int J Obstet Anesth.* 2001;10:172-6.
69. Tsui H, Wu S, Kuo H, Chen C. Rebound intracranial hypertension after treatment of spontaneous intracranial hypotension. *Eur J Neurol.* 2006;13:780-2.
70. Gill JB, Heavner JE. Visual impairment following epidural fluid injections and epiduroscopy: a review. *Pain Med.* 2005;6:367-74.
71. Sencakova D, Mokri B, McClelland RL. The efficacy of epidural blood patch in spontaneous CSF leaks. *Neurology.* 2001 Nov 27;57(10):1921-3.
72. Ferrante E, Rubino GF, Passarani S, Arpino I. Spontaneous intracranial hypotension. *J Neurosurg.* 2010 Aug;113(2):397-8.
73. Berroir S, Loisel B, Ducros A, et al. Early epidural blood patch in spontaneous intracranial hypotension. *Neurology.* 2004 Nov 23;63(10):1950-1.
74. Su CS, Lan MY, Chang YY, Lin WC, Liu KT. Clinical features, neuroimaging and treatment of spontaneous intracranial hypotension and magnetic resonance imaging evidence of blind epidural blood patch. *Eur Neurol.* 2009;61(5):301-7.
75. Rozec B, Guillon B, Desal H, Blanloeil Y. Value of epidural blood-patches for the treatment of spontaneous intracranial hypotension. *Ann Fr Anesth Reanim.* 2004 Dec; 23(12):1144-8.
76. Horikoshi T, Watanabe A, Uchida M, Kinouchi H. Effectiveness of an epidural blood patch for patients with intracranial hypotension syndrome and persistent spinal epidural fluid collection after treatment. *J Neurosurg.* 2010 Nov;113(5):940-6.
77. Mehta B, Tarshis J. Repeated large-volume epidural blood patches for the treatment of spontaneous intracranial hypotension. *Can J Anaesth.* 2009 Aug;56(8):609-13.
78. Franzini A, Messina G, Nazzi V, et al. Spontaneous intracranial hypotension syndrome: a novel speculative physiopathological hypothesis and a novel patch method in a series of 28 consecutive patients. *J Neurosurg.* 2010 Feb;112(2):300-6.
79. Groen RJ, Hoogland PV. Spontaneous intracranial hypotension. *J Neurosurg.* 2010 Sep;113(3):685-8.
80. Inamasu J, Nakatsukasa M. Blood patch for spontaneous intracranial hypotension caused by cerebrospinal fluid leak at C1-2. *Clin Neurol Neurosurg.* 2007 Oct;109(8):716-19.
81. Cousins MJ, Brazier D, Cook R. Intracranial hypotension caused by cervical cerebrospinal fluid leak: treatment with epidural blood patch. *Anesth Analg.* 2004 Jun;98(6):1794-7.
82. Rai A, Rosen C, Carpenter J, Miele V. Epidural blood patch at C2: diagnosis and treatment of spontaneous intracranial hypotension. *AJNR.* 2005 Nov-Dec;26(10):2663-6.
83. Cho Ki, Moon HS, Jeon HJ, Park K, Kong DS. Spontaneous intracranial hypotension: efficacy of radiologic targeting vs. blind blood patch. *Neurology.* 2011;76:1139-44.
84. Gladstone JP, Nelson K, Patel N, Dodick DW. Spontaneous CSF leak treated with percutaneous CT-guided fibrin glue. *Neurology.* 2005 May 24;64(10):1818-19.
85. Garcia-Aguado R, Gil F, Barcia JA, et al. Prophylactic percutaneous sealing of lumbar postdural puncture hole with fibrin glue to prevent cerebrospinal fluid leakage in swine. *Anesth Analg.* 2000;90:894-8.
86. Mokri B. Expert commentary: role of surgery for the management of CSF leaks. *Cephalalgia.* 2008;28:1357-60.
87. Cohen-Gadol AA, Mokri B, Piepgras DG, Meyer FB, Atkinson JL. Surgical anatomy of dural defects in spontaneous spinal cerebrospinal fluid leaks. *J Neurosurg.* 2006 Apr;58(4 Suppl 2):ONS-238-45; discussion ONS-245.
88. Schievink WI. A novel technique for treatment of intractable spontaneous intracranial hypotension: lumbar dural reduction surgery. *Headache.* 2009 Jul;49(7):1047-51. Appendix

Appendix I: ICHD-II Diagnostic Criteria for SIH

- A. Diffuse &/or dull headache that worsens within 15 min after sitting or standing, with at least one of the following and fulfilling criterion D:
 - 1. Neck stiffness
 - 2. Tinnitus
 - 3. Hypacusia
 - 4. Photophobia
 - 5. Nausea
- B. At least one of:
 - 1. Evidence of low CSF pressure on MRI (e.g. pachymeningeal enhancement)
 - 2. Evidence of CSF leakage on conventional myelography, CT myelography or cisternography
 - 3. CSF opening pressure < 60 mm H₂O
- C. No history of dural puncture or other cause of CSF fistula
- D. Headache resolves within 72 h after epidural blood patching

Appendix II: Criteria proposed by Schievink in 2008

- A. Demonstration of a spinal CSF leak, or
- B. Cranial MRI changes of intracranial hypotension, and the presence of at least one of:
 - 1. Low opening pressure (≤ 60 mm H₂O)
 - 2. Spinal meningeal diverticulum
 - 3. Improvement of symptoms after epidural blood patching

Or if criteria A or B not met:

- C. Presence of at least 2 of the following if typical orthostatic headaches are present:
 - 1. Low opening pressure (≤ 60 mm H₂O)
 - 2. Spinal meningeal diverticulum
 - 3. Improvement of symptoms after epidural blood patching

(Schievink WI. *Cephalalgia*. 2008; 28: 1347-1356)