

# The wire is really easy to see (WIRES): sonographic visualization of the guidewire by novices

James H. Moak, MD, RDMS\*; John S. Rajkumar, MD<sup>†</sup>; William A. Woods, MD\*

## ABSTRACT

**Objective:** To determine whether novices can distinguish between properly and improperly placed guidewires in a vascular access model after only minimal training.

**Methods:** This was a prospective study involving trainees with no previous training in sonographic guidewire visualization. A vascular access model was created with guidewires positioned inside or adjacent to simulated veins. Subjects were taught to scan each wire to determine its location. Afterward, participants scanned a test model of five vein-wire pairs and recorded their answers as “inside,” “outside,” or “unsure.” The test characteristics of sonographic guidewire localization were determined using actual wire location as the criterion standard.

**Results:** Forty trainees (21 emergency medicine residents, 19 medical students) participated, and each examined five simulated veins. There were 156 true positives (intravascular wire correctly identified), 38 true negatives (extravascular wire correctly identified), 2 false negatives, 2 false positives, and 2 cases in which the participant marked “not sure,” which were reclassified as false negatives. Test characteristics were sensitivity 97.5% (95% CI 93.3–99.2) and specificity 95.0% (95% CI 81.8–99.1). The overall accuracy was 97.0%.

**Conclusions:** Sonographic guidewire visualization, a step recommended for ensuring proper vessel cannulation during central venous access, can be accomplished by novices with a high degree of accuracy.

## RÉSUMÉ

**Objectif:** L'étude visait à déterminer si des débutants pouvaient faire la distinction entre des fils-guides bien placés et des fils-guides mal placés dans un modèle d'accès vasculaire, après une formation minimale seulement.

**Méthodes:** Il s'agit d'une étude prospective à laquelle ont participé des stagiaires sans formation préalable dans la visualisation de fils-guides à l'échographie. Un modèle

d'accès vasculaire a été créé, avec des fils-guides placés à l'intérieur ou à l'extérieur des veines factices. Les sujets ont d'abord appris à échographier chaque fil-guide pour déterminer son emplacement, puis ont échographié un modèle comptant cinq ensembles veine-fil-guide, et indiqué leurs réponses comme suit: « À l'intérieur », « À l'extérieur », ou « Incertain ». Les caractéristiques du test sur la localisation des fils-guides à l'échographie ont été déterminées à partir de l'emplacement réel des fils-guides, critère constitué en norme.

**Résultats:** Quarante stagiaires (21 résidents en médecine d'urgence, 19 étudiants en médecine) ont participé à l'étude, et chacun a examiné cinq veines factices. Il y a eu 156 vraies réponses positives (fil-guide intravasculaire: bonne réponse), 38 vraies réponses négatives (fil-guide extravasculaire: bonne réponse), 2 fausses réponses négatives, 2 fausses réponses positives, et 2 réponses notées « Incertain » et traitées comme fausses réponses négatives. Le test avait pour caractéristiques une sensibilité de 97.5% (IC à 95%: 93.3–99.2) et une spécificité de 95.0% (IC à 95%: 81.8–99.1). Le taux global de précision a atteint 97.0%.

**Conclusions:** La visualisation du fil-guide à l'échographie, étape recommandée pour s'assurer de la bonne position de la canule à l'intérieur du vaisseau pendant l'accès veineux central, peut se réaliser avec une grande précision par des débutants.

**Keywords:** arterial puncture, complications, guidewire, ultrasonography, vascular access

The use of real-time ultrasound guidance during internal jugular (IJ) vein cannulation results in fewer procedural complications than with a landmark approach.<sup>1-3</sup> Nonetheless, inadvertent carotid artery cannulation can still occur even when ultrasonography is employed.<sup>4,5</sup> The incidence of this complication is

From the \*Department of Emergency Medicine, University of Virginia, Charlottesville, VA, and the †Department of Emergency Medicine, North Shore University Hospital, Manhasset, NY.

Presented as an abstract at the annual meeting of the Society for Academic Emergency Medicine, Boston, MA, June 2011.

**Correspondence to:** James H. Moak, MD, RDMS, University of Virginia Health System, PO Box 800699, Charlottesville, VA 22908-0699; james.moak@virginia.edu.

This article has been peer reviewed.

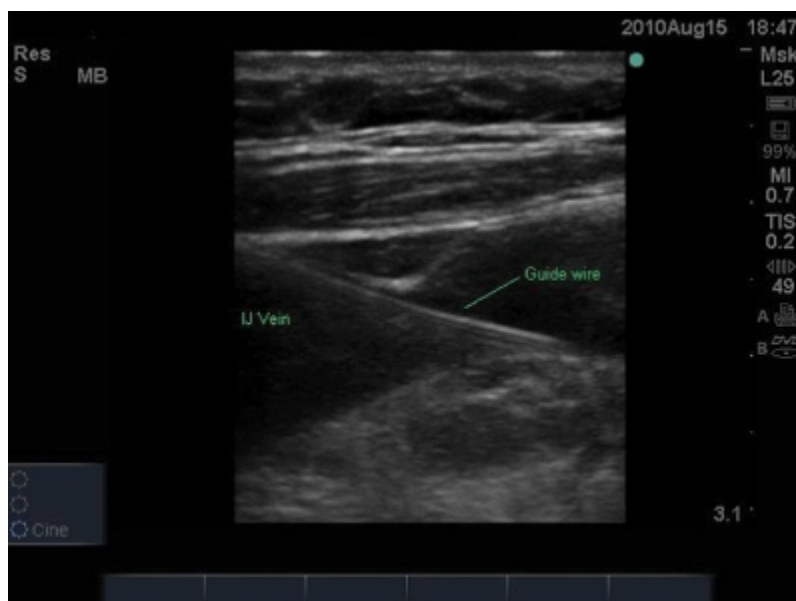thought to be low but is likely underreported.<sup>6</sup> Complications that may occur as a result of iatrogenic carotid artery cannulation include airway compromise from expanding hematomas or pseudoaneurysms, hemothorax, carotid-jugular fistula, stroke, and death.<sup>5-8</sup> One proposed method for avoiding carotid artery cannulation is to visualize the guidewire sonographically (Figure 1) prior to dilation and placement of the catheter.<sup>9-11</sup> Previous studies have demonstrated that the guidewire is easier to visualize than the needle and that physicians with fellowship training in ultrasonography can determine guidewire positioning with 100% accuracy.<sup>9,10</sup> A retrospective review of central line insertions by a single experienced operator using this technique revealed no inadvertent arterial cannulations.<sup>11</sup> The reliability of this technique, however, has not yet been demonstrated among practitioners with less extensive training. In this study, we hypothesized that with minimal training, medical students and residents would be able to determine guidewire location in an inanimate model with a high degree of accuracy.

## **MATERIALS AND METHODS**

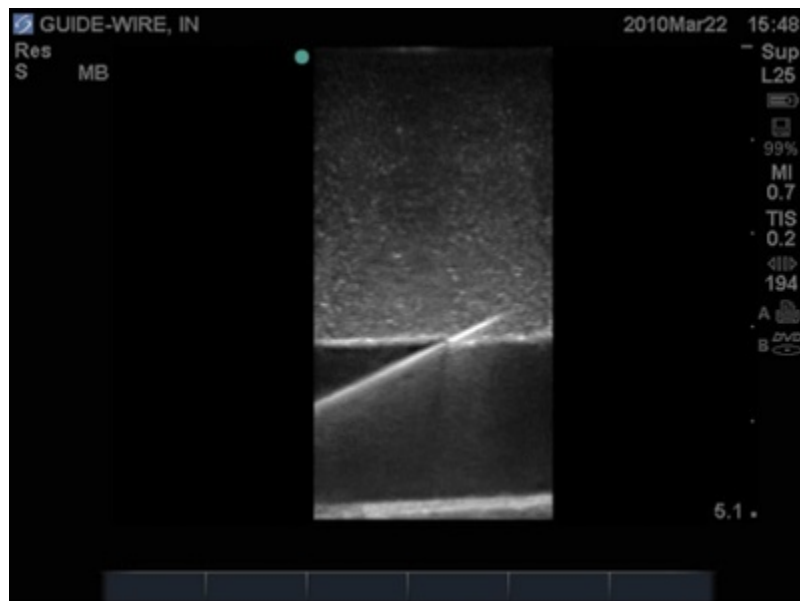
This was a prospective observational study involving a convenience sample of medical students and emergency medicine residents participating in didactic sessions on ultrasound-guided vascular access at the University of Virginia on March 24, 2010. Attendees at a resident conference held by the Department of

Emergency Medicine or at a didactic session hosted by the medical school emergency medicine interest group (EMIG) were eligible for participation. Participation was required for residents attending the conference and optional for students attending the EMIG meeting. At the latter meeting, students were free to visit any of three stations on ultrasonography, one of which involved vascular access. All students visiting the vascular access station participated in data collection. As this study coincided with routine didactics and was limited to the number of participants at each session, we did not perform a sample size calculation prior to initiation of the study. The study was approved by the Institutional Review Board with waiver of consent.

Participants were given a 5-minute demonstration on guidewire visualization followed by hands-on training with an inanimate vascular access model. The model was constructed using water-filled latex (Penrose) drains to simulate veins inside an opaque, congealed gelatin-psyllium mixture, as previously described.<sup>12</sup> Each simulated vein was 3 cm below the surface of the model and had an accompanying guidewire positioned either correctly within the vessel or incorrectly outside it. Participants were taught to visualize each wire in both longitudinal (Figure 2) and transverse (Figure 3) scanning planes. After watching the instructor demonstrate the appearance of correctly and incorrectly positioned wires, trainees were allowed to practice on the vascular access model. Each trainee scanned one simulated vein with an improperly placed wire and between one and four veins with properly placed wires. Trainees were advised to



**Figure 1.** Guidewire visualized sonographically within the internal jugular (IJ) vein in a longitudinal imaging plane.

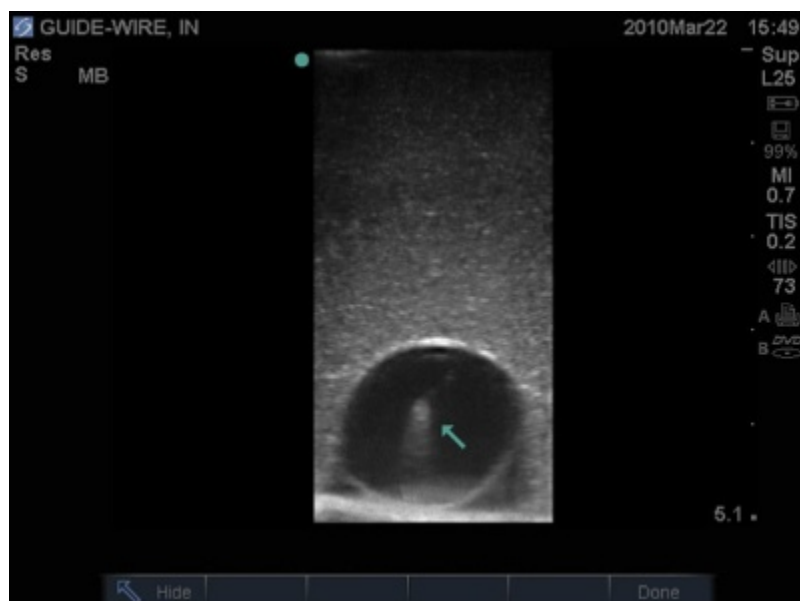

**Figure 2.** The guidewire shown in a longitudinal plane in a vascular access model.

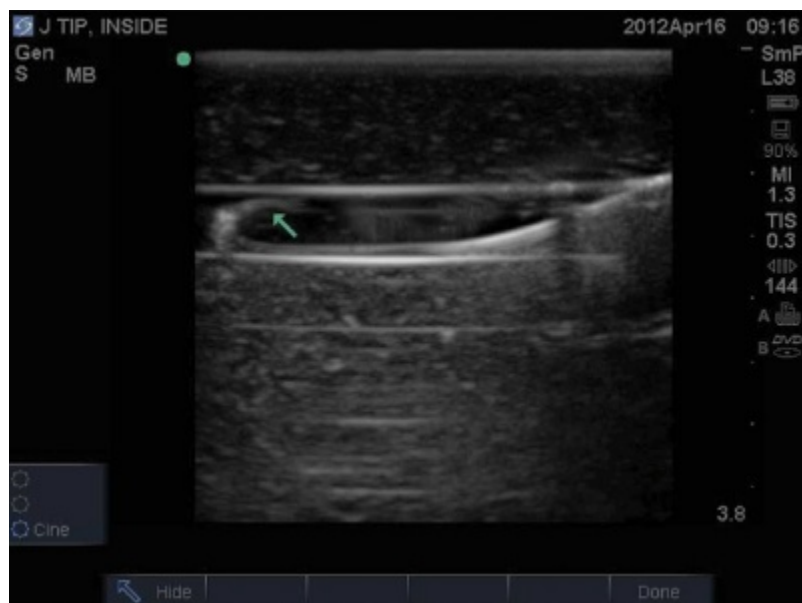visualize the entire length of the wire transversely and longitudinally but were not specifically taught to recognize its terminal J shape within the vessel lumen (Figure 4) as a criterion for correct placement.

After training, each participant moved to a testing station where another vascular access model was located. The testing model contained five guidewires labeled A through E, each positioned either inside or adjacent to a corresponding vein. Participants were not told how many of the wires, if any, were properly positioned. Neither the training model nor the testing model contained a simulated artery. Participants used a

Sonosite M-Turbo (Bothell, WA) with a 6 to 13 MHz 25 mm linear array transducer to determine the location of each guidewire relative to the vein. Participants recorded their responses as “inside,” “outside,” or “unsure” on a data collection sheet. No instructors or other participants were allowed near the testing station while the examinee scanned the testing model and completed the data sheet. Subjects were asked not to discuss the examination until all participants had undergone testing. The test characteristics were determined using known wire position as the criterion standard.



**Figure 3.** The guidewire (arrow) shown in a transverse imaging plane in a simulated vascular access model.



**Figure 4.** Longitudinal view of the guidewire in a vascular access model with a J tip (arrow) observed within the vessel.

## RESULTS

The participants in the study were 19 medical students (11 first year, 3 third year, and 5 fourth year) and 21 residents (6 first year, 8 second year, and 7 third year). Table 1 illustrates the main results of the study. In 200 wire visualizations, there were 156 true positives (intravascular wire correctly identified), 38 true negatives (extravascular wire correctly identified), 2 false negatives (wire mistakenly labeled as outside), and 2 false positives (wire mistakenly labeled as inside). Additionally, in two instances, participants labeled an intravascular wire as “not sure.” For statistical purposes, these two instances were classified as false negatives. The overall sensitivity was 97.5% (95% CI 93.3–99.2), specificity was 95.0% (95% CI 81.8–99.1), and accuracy was 97.0%. All six errors were committed by four participants and none by second- or third-year residents (Table 2).

**Table 1. Test performance of sonographic guidewire visualization by novices**

Wire location by ultrasonography	Actual wire location	
	Inside vein	Outside vein
Inside	156	2
Outside	2	38
Not sure	2*	0

\*When the two “not sure” observations are classified as false negatives (the wire is mistakenly labeled as outside the vessel), the test characteristics are sensitivity 97.5% (95% CI 93.3–99.2), specificity 95.5% (95% CI 81.8–99.1), positive predictive value 98.7% (95% CI 95.0–99.8), and negative predictive value 90.5% (95% CI 76.5–96.9).

## DISCUSSION

Our findings using a simulated vascular access model suggest that operators with minimal prior training can confirm or refute intravascular guidewire positioning using ultrasonography with high accuracy. Although uncommon, inadvertent carotid artery cannulation can cause bleeding, airway compromise, stroke, or death.<sup>5–8</sup> An ideal technique for avoiding this iatrogenic error would be reliable, easy to learn, and inexpensive and cause little procedural disruption. One suggested technique for confirming proper vessel entry involves attaching plastic intravenous tubing to the needle after vessel penetration and observing the flow and pulsation of blood within the tubing with positional changes.<sup>13</sup> This technique requires holding the needle steady while the needle tip resides within the vessel lumen, is time consuming, involves extra equipment, and may not be reliable in hypotensive patients. Another method of ensuring proper vessel cannulation is to proceed with wire placement and perform blood gas analysis on the initial aspirate prior to passing a dilator over the wire. This approach results in procedural delay and added expense and may yield indeterminate results in hypoxic patients. Sonographic guidewire visualization appears reliable and easy to learn, involves no added expense or equipment, and, in our experience, can be performed within seconds.

We are aware of three previous studies examining sonographic guidewire visualization. One study involving 35 emergency department (ED) patients with

**Table 2. Errors committed during sonographic guidewire visualization**

Participant number	Level of training	Examination wire (A–E)	Actual wire location	Observed wire location
15	MS4	D	Inside	Not sure
28	MS1	E	Inside	Outside
30	MS1	C	Outside	Inside
30	MS1	D	Inside	Not sure
38	R1	C	Outside	Inside
38	R1	D	Inside	Outside

MS1 = first-year medical student; MS4 = fourth-year medical student; R1 = first-year resident.

successfully placed catheters reported that physicians can visualize the wire in the vessel lumen more easily than the needle.<sup>9</sup> Another study of 20 ED patients, none of whom had misplaced catheters, reported that expert sonographers had 100% sensitivity for identifying proper vessel cannulation.<sup>10</sup> A third investigation retrospectively examined 53 central lines (arterial puncture and cannulation rate zero) placed by a single operator in the critical care unit using a protocol that involved guidewire visualization.<sup>11</sup>

Our study differs from previous investigations in that we studied less experienced operators, some with no previous exposure to ultrasonography, and included cases with misplaced wires. Our findings suggest that sonographic guidewire visualization is both accurate and simple to learn. No study to date has been adequately powered to demonstrate a reduction in iatrogenic carotid artery cannulation. Nonetheless, we maintain that wire visualization has the potential to improve safety.<sup>9–11</sup> Anecdotally, one of the participants in this study has since reported avoidance of carotid artery cannulation due to recognition of an improperly placed wire.

The results of this study must be interpreted in light of several limitations. Most importantly, we used an inanimate vascular access model, which does not entirely replicate actual living soft tissue or vascular structures. Guidewire identification may be more difficult to accomplish at the bedside during central vein cannulation. Additionally, we chose not to include an artery in our vascular access model as we were not confident that we could replicate the pulsatility of the carotid artery. Instead, all misplaced wires coursed through soft tissue, which would not likely occur under actual procedural circumstances. We did not instruct participants to look for indicators that the vessel in question was truly a vein (e.g., compressibility, thin walls, absence of biphasic pulsatility). We maintain

that any physician-in-training performing ultrasound-guided central venous catheterization must, as a prerequisite, be able to distinguish between artery and vein. Previous investigators have shown that medical students with limited training in ultrasonography can correctly identify the IJ vein 98% of the time.<sup>14</sup> Finally, we did not emphasize identification of the J tip within the lumen of the vein as a definitive sign of proper vessel cannulation. This finding, illustrated in Figure 4, may provide the operator with more confidence that the guidewire does not exit through the posterior wall of the vein and enter into the artery. The utility of J-tip visualization deserves further study. Incorporation of this technique into our training process may have yielded different results.

## CONCLUSION

Sonographic guidewire visualization, a recommended step for ensuring proper vessel cannulation during central venous access, can be accomplished by novices with a high degree of accuracy on an inanimate model. Larger studies are needed to demonstrate whether this technique reduces inadvertent arterial cannulation.

**Competing interests:** None declared.

## REFERENCES

1. Karakitsos D, Labropoulos N, De Groot E, et al. Real-time ultrasound-guided catheterisation of the internal jugular vein: a prospective comparison with the landmark technique in critical care patients. *Crit Care* 2006;10:R162, doi: [10.1186/cc5101](https://doi.org/10.1186/cc5101).
2. Leung J, Duffy M, Finckh A. Real-time ultrasonographically-guided internal jugular vein catheterization in the emergency department increases success rates and reduces complications: a randomized, prospective study. *Ann Emerg Med* 2006; 48:540-7, doi: [10.1016/j.annemergmed.2006.01.011](https://doi.org/10.1016/j.annemergmed.2006.01.011).
3. Milling TJ Jr, Rose J, Briggs WM, et al. Randomized, controlled clinical trial of point-of-care limited ultrasonography

- assistance of central venous cannulation: the Third Sonography Outcomes Assessment Program (SOAP-3) Trial. *Crit Care Med* 2005;33:1764-9, doi:[10.1097/01.CCM.0000171533.92856.E5](https://doi.org/10.1097/01.CCM.0000171533.92856.E5).
4. Stone MB, Hern HG. Inadvertent carotid artery cannulation during ultrasound guided central venous catheterization. *Ann Emerg Med* 2007;49:720, doi:[10.1016/j.annemergmed.2006.11.030](https://doi.org/10.1016/j.annemergmed.2006.11.030).
  5. Domino KB, Bowdle TA, Posner KL, et al. Injuries and liability related to central vascular catheters: a closed claims analysis. *Anesthesiology* 2004;100:1411-8, doi:[10.1097/00000542-200406000-00013](https://doi.org/10.1097/00000542-200406000-00013).
  6. Guilbert MC, Elkouri S, Bracco D, et al. Arterial trauma during central venous catheter insertion: Case series, review and proposed algorithm. *J Vasc Surg* 2008;48:918-25; discussion 925, doi:[10.1016/j.jvs.2008.04.046](https://doi.org/10.1016/j.jvs.2008.04.046).
  7. Singhal M, Gupta V, Singh P, et al. Iatrogenic life-threatening pseudoaneurysms of extracranial internal carotid artery after fine-needle aspiration of cervical lymph nodes: report of two cases in children. *Cardiovasc Intervent Radiol* 2009;32:1260-3, doi:[10.1007/s00270-009-9506-x](https://doi.org/10.1007/s00270-009-9506-x).
  8. Siu DY, Wong GK, Ho SS, et al. Iatrogenic carotid-jugular fistula. *Hong Kong Med J* 2009;15:313-4.
  9. Moak JH, Lyons MS, Wright SW, et al. Needle and guidewire visualization in ultrasound-guided internal jugular vein cannulation. *Am J Emerg Med* 2011;29:432-6, doi:[10.1016/j.ajem.2010.01.004](https://doi.org/10.1016/j.ajem.2010.01.004).
  10. Stone MB, Nagdev A, Murphy MC, et al. Ultrasound detection of guidewire position during central venous catheterization. *Am J Emerg Med* 2010;28:82-4, doi:[10.1016/j.ajem.2008.09.019](https://doi.org/10.1016/j.ajem.2008.09.019).
  11. Gillman LM, Blaivas M, Lord J, et al. Ultrasound confirmation of guidewire position may eliminate accidental arterial dilatation during central venous cannulation. *Scand J Trauma Resusc Emerg Med* 2010;18:39, doi:[10.1186/1757-7241-18-39](https://doi.org/10.1186/1757-7241-18-39).
  12. Kendall JL, Faragher JP. Ultrasound-guided central venous access: a homemade phantom for simulation. *CJEM* 2007;9:371-3.
  13. Arndt GA, Felton T, Finucane B, et al. Confirmation of internal jugular vein cannulation: the Finucane technique. *Can J Anaesth* 1993;40:1220-1, doi:[10.1007/BF03009616](https://doi.org/10.1007/BF03009616).
  14. Afonso N, Amponsah D, Yang J, et al. Adding new tools to the black bag—introduction of ultrasound into the physical diagnosis course. *J Gen Intern Med* 2010;25:1248-52, doi:[10.1007/s11606-010-1451-5](https://doi.org/10.1007/s11606-010-1451-5).