

DIAGNOSTIC CHALLENGE

**Acute ischemic upper limb in a young man:
an emergency presentation**

Luke Jones, BSc (Hons), MB BS;* Angela Birnie, BSc (Hons), MB BS;* Utham Shanker, FRCS†

Case history

A 25-year-old male computer programmer presented to the emergency department because he had been unable to fully extend his right elbow for 10 days. Several days before this his family doctor diagnosed elbow tendinitis and prescribed a non-steroidal anti-inflammatory drug. Twenty-four hours before admission the patient developed sudden onset of pain and cramping in the right hand, associated with cold skin. There was no precipitating trauma or overuse of the right upper limb. The patient's past medical history was unremarkable. In particular, there was no history of peripheral vascular disease, arrhythmia or rheumatological disorder. He was, however, a smoker.

Physical examination of the right upper limb revealed an edematous right hand with cold skin to the level of the elbow joint. Capillary refill was significantly prolonged (16 s) and brachial, radial and ulnar pulses were not palpable. Blood pressure in the other arm and cardiac rhythm were normal. Chest x-ray (Fig. 1) provided a clue to the etiology of this patient's acute ischemic limb.

The most likely diagnosis is:

- a) peripheral vascular disease;
- b) paradoxical embolism due to a patent foramen ovale;
- c) a hypercoaguable state with axillary vein thrombosis; or
- d) cervical rib with brachial artery thrombosis.

For the Answer to this Challenge, see page 370.

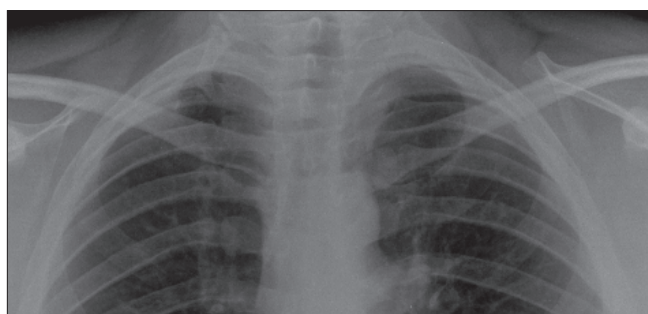


Fig. 1. Results of chest x-ray of right cervical rib.

*Accident and Emergency Department, Senior House Officer, Eastbourne District General Hospital, Eastbourne, East Sussex, United Kingdom

†Consultant in Accident and Emergency Medicine, Eastbourne District General Hospital, Eastbourne, East Sussex, United Kingdom

Received: Oct. 25, 2005; accepted: July 31, 2006

This article has been peer reviewed.

Can J Emerg Med 2006;8(5):345