



# Myocardial infarction and narrowed peripheral arterial vessels secondary to generalised arterial calcification syndrome in a two-month-old girl

## Brief Report

**Cite this article:** Toprak MHH, Ozturk E, Hatemi AC, Gezdirici A, and Tanidir İC (2024). Myocardial infarction and narrowed peripheral arterial vessels secondary to generalised arterial calcification syndrome in a two-month-old girl. *Cardiology in the Young*, page 1 of 3. doi: [10.1017/S1047951124025253](https://doi.org/10.1017/S1047951124025253)

Received: 25 October 2023

Revised: 4 April 2024




Accepted: 1 May 2024

### Keywords:

generalised arterial calcinosis of infancy; dilated cardiomyopathy; catheter angiography

### Corresponding author:

Muhammet Hamza Halil Toprak; Email: [muhammedhamzatoprak@hotmail.com](mailto:muhammedhamzatoprak@hotmail.com)

Muhammet Hamza Halil Toprak<sup>1</sup> , Erkut Ozturk<sup>1</sup> , Ali Can Hatemi<sup>2</sup>, Alper Gezdirici<sup>3</sup> and İbrahim Cansaran Tanidir<sup>1</sup> 

<sup>1</sup>Department of Pediatric Cardiology, Saglik Bilimleri University, Basaksehir Cam ve Sakura City Hospital, Istanbul, Turkey; <sup>2</sup>Department of Pediatric Cardiovascular Surgery, Saglik Bilimleri University, Basaksehir Cam ve Sakura City Hospital, Istanbul, Turkey and <sup>3</sup>Department of Genetics, Saglik Bilimleri University, Basaksehir Cam ve Sakura City Hospital, Istanbul, Turkey

## Abstract

Generalised arterial calcification of infancy, an autosomal recessive disorder characterised by abnormal calcification of medium and large-sized arteries, represents a rare cause of dilated cardiomyopathy. We present the case of a two-month-old girl diagnosed posthumously with dilated cardiomyopathy. Studies suggest that early initiation of treatment can improve prognosis in generalised arterial calcification of infancy, so clinicians should be alert to the condition, especially in patients displaying generalised narrowing of medium and large-sized arteries.

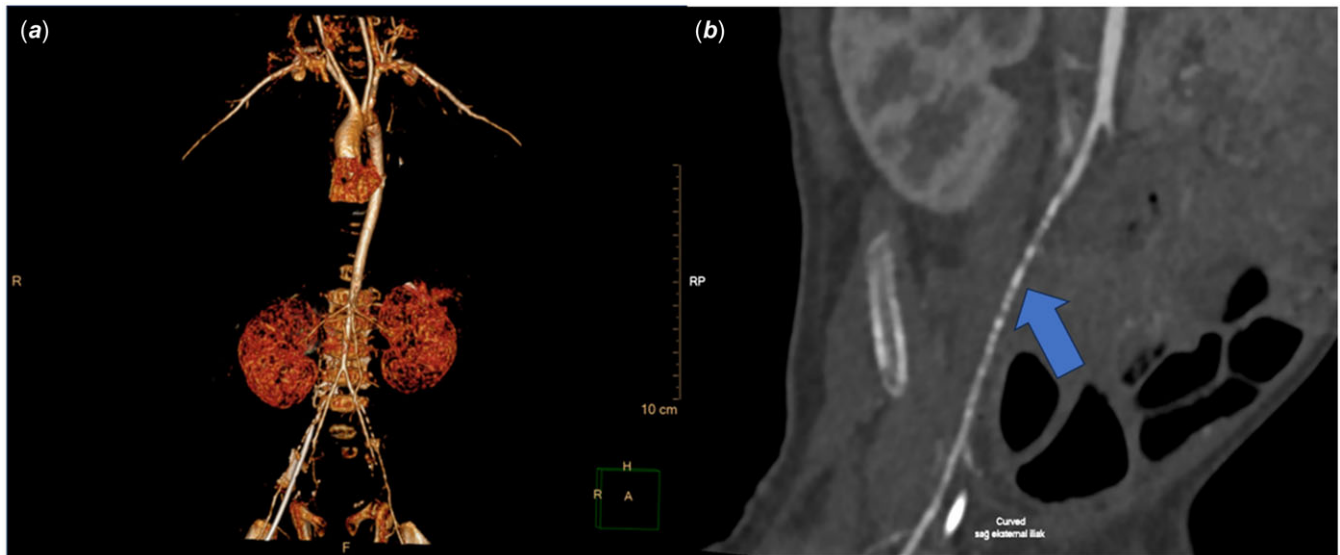
## Introduction

Dilated cardiomyopathy, a condition characterised by the enlargement of the left heart chambers and a decrease in left ventricular systolic function, can manifest from birth<sup>1</sup> While common causes such as idiopathic factors, coronary artery anomalies, and arrhythmias are well-documented contributors to this condition, rarer genetic and metabolic diseases can also lead to its development. In this case, we present a patient diagnosed with dilated cardiomyopathy as a consequence of coronary artery involvement stemming from generalised arterial calcification of infancy.

## Case report

A two-month-old girl was brought to the emergency room with a complaint of cyanosis observed at home. She was born at full term with a birth weight of 3,000 g and had been asymptomatic until reaching two months of age. Initial examination revealed signs of tachycardia, tachypnoea, and a general deterioration of her condition. Blood gas analysis indicated the presence of significant metabolic acidosis. A chest X-ray showed cardiomegaly, prompting further investigation with echocardiography. The echocardiogram confirmed dilation of the left heart chambers and severe mitral valve insufficiency accompanied by a significant decrease in left ventricular systolic function, with a shortening fraction of 22%. Notably, no findings indicated aortic coarctation, aortopulmonary collateral arteries, or fistula, which are typical causes of dilated cardiomyopathy (Video 1). She was admitted to the cardiac ICU, and inotropic treatment was initiated. On the second day of hospitalisation, coronary angiography was performed to rule out potential coronary artery anomalies.

Femoral artery pulses were non-palpable, and despite attempts to puncture the femoral arteries under ultrasound guidance, the wire could not be advanced through either artery. Consequently, the procedure was carried out via the larger left axillary artery. The angiography revealed multiple stenoses in both the right and left coronary arteries (Video 2). Contrast-enhanced angiography was performed to evaluate other arterial structures, revealing contour irregularities in the distal segments of both subclavian arteries, the mid-distal sections of the superior mesenteric artery, and the inferior mesenteric artery. Simultaneously, it was noted that the descending aorta exhibited gradual narrowing as it approached the iliac bifurcation. Diffuse contour irregularities and high-grade stenosis were detected in both iliac arteries just beyond the bifurcation point, extending to the distal end (Fig. 1). Given the extensive vascular involvement, the paediatric rheumatology department was consulted to evaluate the potential presence of vasculitis. Although vasculitis was initially not considered due to the patient's young age, intravenous immunoglobulin and pulse steroid therapy were suggested. Treatment consisting of 30 mg methylprednisolone for three days and 2 g/kg intravenous immunoglobulin was initiated,



**Figure 1.** Computed tomography images of the patient. (a) 3D computed tomography shows gradual narrowing of the descending aorta. Bilateral iliac and renal arteries are hypoplastic due to the stenosis. (b) Sagittal plane of computed tomography shows calcium deposits and narrowing in the right external iliac artery.

followed by treatment with 2 mg/kg/day of methylprednisolone. Genetic and metabolic tests were conducted, and inotrope and diuretic treatments were maintained in the ICU.

A follow-up angiography was performed during the third week of hospitalisation, this time through the right axillary artery. The angiography confirmed the presence of persistent diffuse stenosis in the coronary arteries as well as in the iliac, renal, and mesenteric arteries (Video 3). Subsequent echocardiography revealed a significant regression in left heart chamber diameters and improved systolic function (shortening fraction: 41%). The patient's clinical condition improved, and she was subsequently discharged for outpatient follow-up.

Approximately two months after discharge, the patient presented to the emergency room with cardiac arrest. Extracorporeal membrane oxygenation support was initiated due to treatment-resistant heart failure. Unfortunately, despite these efforts, extracorporeal membrane oxygenation support was terminated on the third day due to persistent lack of improvement in cardiac function. Subsequent necropsy revealed vascular sections containing calcified atheroma plaques in the right coronary and right internal mammary arteries. Genetic analysis identified a mutation in the adenosine triphosphate-binding cassette (subfamily C member 6 (ABCC6) gene.

## Discussion

Generalised arterial calcification of infancy, an autosomal recessive disorder, is characterised by abnormal calcification of medium and large-sized arteries,<sup>2</sup> leading to significant myointimal proliferation and arterial stenosis. Its prognosis is poor, with approximately 85% of affected infants succumbing within the first six months of life, often due to cardiovascular complications and heart failure. Diagnosis poses challenges due to the variability of clinical presentation and the rarity of the disease.<sup>2</sup> During the antenatal period, ultrasonography may reveal arterial calcification, foetal distress, and nonimmune hydrops as well as pleural and pericardial effusion. In infancy, patients frequently exhibit non-specific symptoms, including lethargy, vomiting, irritability, and shock, with peripheral pulses often being

weak or absent.<sup>2,3</sup> Our patient presented with poor general condition, malnutrition, and fatigue upon admission.

Diagnostic imaging techniques, such as echocardiography, angiography, and tomography, play crucial roles in confirming the diagnosis.<sup>4</sup> Mutations in the ectonucleotide pyrophosphatase phosphodiesterase 1 gene, located on chromosome 6, are detected in 75% of patients (generalised arterial calcification of infancy 1).<sup>5</sup> Defects in the ectonucleotide pyrophosphatase phosphodiesterase 1 gene lead to a reduction in the level of inorganic pyrophosphate, which serves as a potent inhibitor of hydroxyapatite crystal deposition in vessel walls. The decrease in inorganic pyrophosphate levels results in the interruption of the normally eosinophilic internal elastic lamina by basophilic granules and calcium salts. In advanced stages, the internal elastic lamina is completely destroyed, and wide calcium bands become evident. Subsequent calcium deposition progresses to the media layer, leading to severe stenosis in the vascular lumen.<sup>6</sup> In some patients (generalised arterial calcification of infancy 2), mutations in the adenosine triphosphate binding cassette transporter C6 (ABCC6) gene are detected. ABCC6, a protein-coding gene, belongs to the superfamily of adenosine triphosphate binding cassette transporters. These proteins facilitate the transport of various molecules across extra- and intracellular membranes. Mutations in the ABCC6 gene are known to cause pseudoxanthoma elasticum.<sup>5</sup> Our patient tested positive for an ABCC6 gene mutation.

Bisphosphonates, synthetic analogues of inorganic pyrophosphate, have demonstrated a significant increase in survival rates. Studies have shown that treatment with bisphosphonates for four months to two years results in substantial regression of arterial and periarticular calcifications as confirmed by control tomography and ultrasonography. Moreover, recurrence of calcifications is unlikely unless treatment is discontinued.<sup>7</sup> In the case of a child diagnosed with generalised arterial calcification of infancy undergoing heart transplantation, follow-up after a two-year bisphosphonate treatment revealed no involvement of coronary arteries.<sup>8</sup> However, despite a preliminary diagnosis of generalised arterial calcification of infancy, our patient was unable to receive bisphosphonate treatment due to uncertainty regarding the diagnosis.

Burosumab is an Food and Drug Administration-approved anti-fibroblast growth factor 23 monoclonal antibody for the treatment of X-linked hypophosphataemia and tumour-induced osteomalacia. Although it is believed to be potentially beneficial in the treatment of generalised arterial calcification of infancy, it may increase ectopic calcification by reducing pyrophosphate levels, so its use in generalised arterial calcification of infancy treatment is controversial.<sup>9</sup> In a patient initially diagnosed with X-linked hypophosphataemia, started on burosumab treatment and later found to have ectonucleotide pyrophosphatase phosphodiesterase 1-dependent rickets, no new calcifications developed over several months.<sup>10</sup>

## Conclusion

Generalised arterial calcification of infancy represents a rare aetiology for dilated cardiomyopathy in infants. It should be considered in cases in which more common causative diseases remain undetected and evidence exists of generalised arterial involvement. While early diagnosis and treatment typically yield better outcomes, achieving this can be challenging in practice.

**Supplementary material.** The supplementary material for this article can be found at <https://doi.org/10.1017/S1047951124025253>

## References

- Ziegler SG, Gahl WA, Ferreira CR, et al. Generalized arterial calcification of infancy. In: GeneReviews® [Internet]. University of Washington, Seattle (WA), Seattle, 1993.
- Bolster F, Ali Z, Southall P, Fowler D. Generalized arterial calcification of infancy—findings at post-mortem computed tomography and autopsy. *Forensic Sci Int* 2015; 254: e7–12. DOI: [10.1016/j.forsciint.2015.06.017](https://doi.org/10.1016/j.forsciint.2015.06.017). Epub.
- Chong CR, Hutchins GM. Idiopathic infantile arterial calcification: the spectrum of clinical presentations. *Pediatr Dev Pathol* 2008; 11: 405–415. DOI: [10.2350/07-06-0297.1](https://doi.org/10.2350/07-06-0297.1). Epub.
- Pao DG, DeAngelis GA, Lovell MA, McIlhenny J, Hagspiel KD. Idiopathic arterial calcification of infancy: sonographic and magnetic resonance findings with pathologic correlation. *Pediatr Radiol* 1998; 28: 256–259. DOI: [10.1007/s002470050344](https://doi.org/10.1007/s002470050344).
- Rutsch F, Ruf N, Vaingankar S, et al. Mutations in ENPP1 are associated with ‘idiopathic’ infantile arterial calcification. *Nat Genet* 2003; 34: 379–381. DOI: [10.1038/ng1221](https://doi.org/10.1038/ng1221).
- Federici D, Torii S, Ciuffreda M, et al. Coronary pathology of inherited generalized arterial calcification of infancy: a case report. *Cardiovasc Pathol* 2018; 36: 15–19. DOI: [10.1016/j.carpath.2018.05.001](https://doi.org/10.1016/j.carpath.2018.05.001). Epub.
- van der Sluis IM, Boot AM, Vernooij M, Meradji M, Kroon AA. Idiopathic infantile arterial calcification: clinical presentation, therapy and long-term follow-up. *Eur J Pediatr* 2006; 165: 590–593.
- Giovannoni I, Callea F, Travaglini L, et al. Heart transplant and 2-year follow up in a child with generalized arterial calcification of infancy. *Eur J Pediatr* 2014; 173: 1735–1740. DOI: [10.1007/s00431-014-2447-7](https://doi.org/10.1007/s00431-014-2447-7). Epub.
- Ziegler SG, Gahl WA, Ferreira CR, et al. Generalized arterial calcification of infancy. In: GeneReviews® [Internet]. University of Washington, Seattle (WA), Seattle, 1993.
- Boyce AM, Gafni RI, Ferreira CR. Generalized arterial calcification of infancy: new insights, controversies and approach to management. *Curr Osteoporos Rep* 2020; 18: 232–241. DOI: [10.1007/s11914-020-00577-4](https://doi.org/10.1007/s11914-020-00577-4).