

Neuroimaging Highlight

Editor: David Pelz

Hyperperfusion Secondary to Middle Cerebral Artery Stenting

Submitted by: Zhen-Ni Guo, Ge Yang, Hong-Liang Zhang, Shou-Chun Wang, Yi Yang

Can J Neurol Sci. 2012; 39: 383-384

A 55-year-old man presented with recurrent transient episodes of left-sided hemiparesis for one month. Symptoms lasted three to five minutes per time before subsiding to normal. He was referred to our hospital after five episodic attacks. Upon admission, his blood pressure was 110/65 mmHg. T1 and T2 weighted imaging of brain magnetic resonance imaging (MRI) showed no abnormality. Magnetic resonance angiography (MRA) findings were indicative of a severe stenosis in the right middle cerebral artery (MCA). A >70% stenosis in the M1 segment of the right MCA was corroborated by digital subtraction angiography (DSA) (Figure A). The mean cerebral blood flow (CBF) in the cortical territory of the stenotic MCA was evidently lower than that in the corresponding contralateral cortex (31.5 versus 47.1 ml/(100g·min)), as revealed by xenon-enhanced computed tomogram (Xe-CT). An intracranial stent (Apollo, Microport Medical Company, Shanghai, China) was placed in the target artery and DSA showed complete revascularization (Figure B). Nine hours after the operation, the patient developed a persistent headache, nausea and intermittent vomiting. His blood pressure was 185/110 mmHg. Hyperperfusion in the cortical territory of the recanalized artery was noted by emergent Xe-CT examination (60.7 ml/(100g·min) in the right cortex versus 45.9 ml/(100g·min) in the left, Figure C and D). Intravenous infusion of Labetalol under continuous blood pressure monitoring was immediately started to control the blood pressure. His blood pressure was then stabilized at about 120/75 mmHg and the symptoms were resolved.

With the extensive use of stenting, the detrimental effects of hyperperfusion after carotid artery stenting have attracted wide attention.^{1,2} Intracranial stenosis is more prevalent in Asia, but limited data in the literature suggest that cerebral hyperperfusion syndrome (CHS) may also arise from MCA stenting.³⁻⁶ The pathological etiology of CHS is poorly understood and few reliable measures are available to make an early diagnosis. Although further studies are still needed, Xe-CT appears promising in the early diagnosis and treatment of CHS.

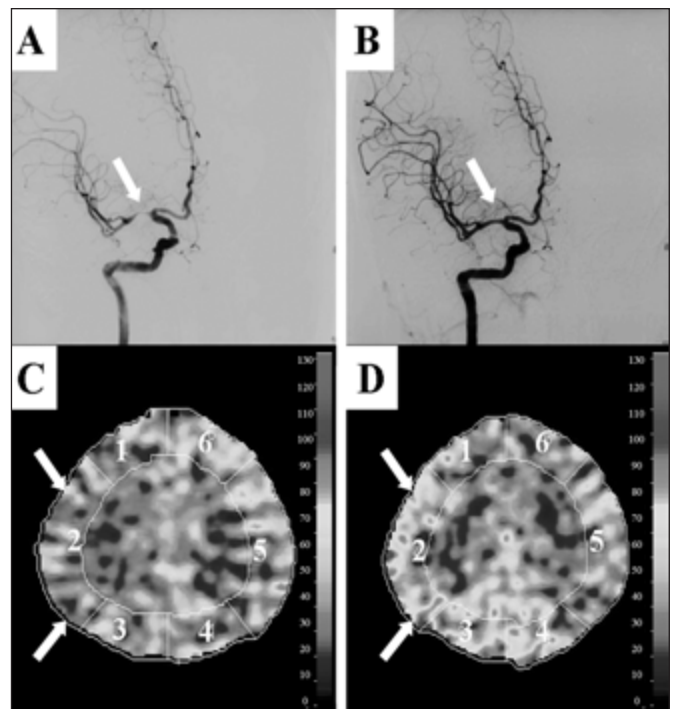


Figure: The manifestations of DSA and Xe-CT. A. Before stenting, DSA showed a severe stenosis (>70%) in the M1 segment of the right MCA. B. After stenting, DSA showed complete revascularization in the right MCA. C. Before stenting, CBF in the territorial cortex of the stenosed MCA as revealed by Xe-CT was significantly lower than that in the contralateral corresponding region. D. After stenting, Xe-CT revealed that CBF in the territory of the lesional MCA was markedly increased (an 87% increase of CBF in the right cortex as compared with that before stenting).

From the Department of Neurology (ZNG, HLZ, SCW, YY), the First Norman Bethune Hospital of Jilin University; Department of Geriatrics Medicine (GY), the Affiliated Hospital to Changchun University of Chinese Medicine, Chang Chun, China.

RECEIVED SEPTEMBER 12, 2011. FINAL REVISIONS SUBMITTED NOVEMBER 1, 2011.

Correspondence to: Yi Yang, Department of Neurology, the First Norman Bethune Hospital of Jilin University, Xinmin Street 71#, 130021, Changchun, P. R. China. Email: doctor_yangyi@hotmail.com

AUTHORS' CONTRIBUTIONS

Study concept and design: Yi Yang. Acquisition of data: Zhen-Ni Guo, Ge Yang, Hong-Liang Zhang, Shou-Chun Wang. Drafting of the manuscript: Zhen-Ni Guo and Yi Yang.

REFERENCES

1. Moulakakis KG, Mylonas SN, Sfyroeras GS, Andrikopoulos V. Hyperperfusion syndrome after carotid revascularization. *J Vasc Surg.* 2009 Apr;49(4):1060-8.
2. van Mook WN, Rennenberg RJ, Schurink GW, et al. Cerebral hyperperfusion syndrome. *Lancet Neurol.* 2005 Dec;4(12):877-88.
3. Brus-Ramer M, Starke RM, Komotar RJ, Meyers PM. Radiographic evidence of cerebral hyperperfusion and reversal following angioplasty and stenting of intracranial carotid and middle cerebral artery stenosis: case report and review of the literature. *J Neuroimaging.* 2010 Jul; 20(3):280-3.
4. Suri MF, Johnston SC. Epidemiology of intracranial stenosis. *J Neuroimaging.* 2009 Oct; 19 Suppl 1:11S-6S.
5. Rezende MT, Spelle L, Mounayer C, Piotin M, Abud DG, Moret J. Hyperperfusion syndrome after stenting for intracranial vertebral stenosis. *Stroke.* 2006 Jan;37(1):e12-4.
6. Meyers PM, Phatouros CC, Higashida RT. Hyperperfusion syndrome after intracranial angioplasty and stent placement. *Stroke.* 2006 Sep;37(9):2210-1.