

# Management of Optic Chiasmatic/Hypothalamic Astrocytomas in Children

Paul Steinbok, Stephen Hentschel, Per Almqvist, D. Douglas Cochrane, Kenneth Poskitt

**ABSTRACT: Objective:** The management of optic chiasmatic gliomas is controversial, partly related to failure to separate out those tumors involving the optic chiasm only (chiasmatic tumors) from those also involving the hypothalamus (chiasmatic/hypothalamic tumors). The purpose of this study was: (i) to analyze the outcomes of chiasmatic and chiasmatic/hypothalamic tumors separately; and (ii) to determine the appropriateness of recommending radical surgical resection for the chiasmatic/hypothalamic tumors. **Methods:** A retrospective chart review of all newly diagnosed tumors involving the optic chiasm from 1982-1996 at British Columbia's Children's Hospital was performed. **Results:** There were 32 patients less than 16 years of age, 14 with chiasmatic and 18 with chiasmatic/hypothalamic astrocytomas, with an average duration of follow-up of 5.8 years and 6.3 years, respectively. Ten of the patients with chiasmatic tumors and none with chiasmatic/hypothalamic tumors had neurofibromatosis I. Thirteen of the 14 chiasmatic tumors were managed with observation only, and none had progression requiring active intervention. For the chiasmatic/hypothalamic tumors, eight patients had subtotal resections (>95% resection), six had partial resections (50-95%), three had limited resections (<50%), and one had no surgery. There were fewer complications associated with the limited resections, especially with respect to hypothalamic dysfunction. There was no correlation between the extent of resection (subtotal, partial, or limited) and the time to tumor progression (average 18 months). **Conclusions:** In conclusion, chiasmatic and chiasmatic/hypothalamic tumors are different entities, which should be separated out for the purposes of any study. For the chiasmatic/hypothalamic tumors, there was more morbidity and no prolongation of time to progression when radical resections were compared to more limited resections. Therefore, if surgery is performed, it may be appropriate to do a surgical procedure that strives only to provide a tissue diagnosis and to decompress the optic apparatus and/or ventricular system.

**RÉSUMÉ: Prise en charge de l'astrocytome du chiasma optique/de l'hypothalamus chez l'enfant. Objectif:** La prise en charge des gliomes du chiasma optique est controversée, en partie parce qu'on ne fait pas de distinction entre les tumeurs impliquant seulement le chiasma optique (tumeurs chiasmaticques) et celles qui impliquent également l'hypothalamus (tumeurs chiasmaticques/hypothalamiques). Les objectifs de cette étude étaient: (i) d'analyser séparément l'issue des tumeurs chiasmaticques et chiasmaticques/hypothalamiques; et (ii) de déterminer la pertinence de recommander la résection chirurgicale radicale des tumeurs chiasmaticques/hypothalamiques. **Méthodes:** Nous avons procédé à une revue rétrospective des dossiers de patients porteurs de tumeurs nouvellement diagnostiquées impliquant le chiasma optique entre 1982 et 1996 au Children's Hospital de la Colombie Britannique. **Résultats:** L'étude porte sur 32 patients de moins de 16 ans, 14 présentant un astrocytome chiasmaticque et 18 un astrocytome chiasmaticque/hypothalamique. La durée moyenne du suivi était de 5,8 ans et 6,3 ans respectivement. Dix des patients porteurs de tumeurs chiasmaticques étaient atteints de neurofibromatose de type I alors qu'aucun des patients porteurs de tumeurs chiasmaticques/hypothalamiques n'en étaient atteints. La conduite pour 13 des 14 tumeurs chiasmaticques a été l'observation seulement et aucune n'a nécessité une intervention à cause de la progression de la tumeur. Quant aux patients atteints de tumeurs chiasmaticques/hypothalamiques, huit ont subi une résection subtotale (résection de plus de 95%), six ont subi une résection partielle (de 50 à 95%), trois ont subi une résection limitée (de moins de 50%) et un n'a pas été opéré. Il y a eu moins de complications associées aux résections limitées, surtout quant à la dysfonction hypothalamique. Il n'existait pas de corrélation entre l'étendue de la résection (subtotale, partielle ou limitée) et le moment de la récurrence (en moyenne 18 mois). **Conclusions:** Les tumeurs chiasmaticques et chiasmaticques/hypothalamiques sont des entités différentes qui devraient être considérées séparément dans les études. Pour les tumeurs chiasmaticques/hypothalamiques, il y avait davantage de morbidité, sans prolongation du temps de rémission, quand on compare la résection radicale à la résection limitée. Si on a recours à la chirurgie, il peut être approprié de faire une intervention dont le but n'est que de fournir un diagnostic anatomopathologique et de décompresser l'appareil optique et/ou le système ventriculaire.

Can. J. Neurol. Sci. 2002; 29: 132-138

Optic pathway gliomas are almost always low-grade astrocytomas, either pilocytic or diffuse. Despite the uniformly benign histology, the rate of growth with or without therapeutic intervention is unpredictable.<sup>1</sup> As a result, the management of optic pathway gliomas is controversial. Some authors have stated that these neoplasms behave like hamartomas and thus treatment should be conservative,<sup>2</sup> while most others have found the tumor behavior to be more sinister.<sup>3-5</sup>

Therapeutic efforts have been directed towards preservation of vision and maintenance of long-term survival. Surgical resection of these tumors, which are intrinsic to the optic

pathway, was historically thought to be unsafe and the standard treatments involved observation or high dose cranial radiation, the latter usually following biopsy.<sup>4,9</sup> Beneficial effects of radiotherapy in controlling tumor growth and preventing

From the Division of Pediatric Neurosurgery (PS, SH, PA, DDC), Department of Surgery, and Division of Neuroradiology (KP), Department of Radiology, University of British Columbia and British Columbia's Children's Hospital, Vancouver, BC, Canada

RECEIVED AUGUST 3, 2001. ACCEPTED IN FINAL FORM NOVEMBER 21, 2001.  
Reprint requests to: Paul Steinbok, Division of Neurosurgery, British Columbia's Children's Hospital, 4480 Oak Street, #A325, Vancouver, BC, V6H 3V4

progression of optic pathway gliomas have been reported.<sup>6,7,10</sup> However, it has become recognized that cranial radiation, particularly when used in infants and children, is associated with major complications, including cognitive impairment,<sup>6,11</sup> vasculopathy,<sup>8,12-15</sup> endocrinopathy,<sup>6,16</sup> and secondary malignancies.<sup>17</sup> Systemic chemotherapy, using a variety of drug combinations, has been reported to cause stabilization or decrease in the size of some optic pathway gliomas.<sup>18-20</sup>

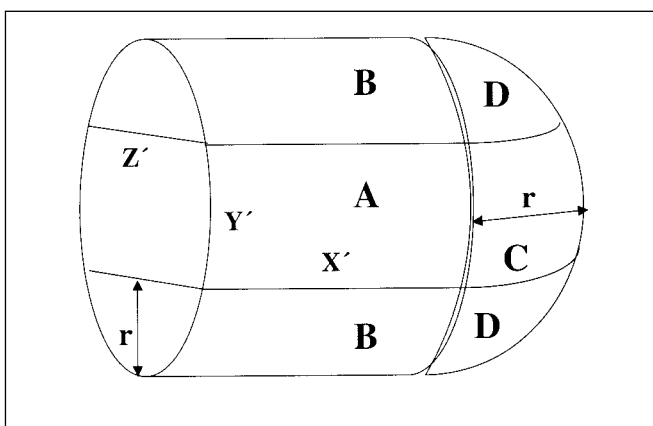
Although often lumped together, optic pathway gliomas may be separated anatomically into three distinct groups: optic nerve lesions, optic chiasmatic lesions, and optic chiasmatic/hypothalamic lesions. Part of the controversy over the natural history may reflect a failure to examine each of these three tumor types separately.

One of the major controversial issues is the role of resection in the management of these tumors, particularly the chiasmatic/hypothalamic tumors, which tend to be large. With current techniques, radical resection of chiasmatic/hypothalamic tumors with preservation of visual function has been shown to be technically feasible, and some authors have advocated such an approach as the initial treatment modality for these tumors.<sup>17,21-23</sup> However, the relationship between the extent of resection, the control of tumor growth, and the morbidity of the resection has not been clearly defined. For many years the pediatric neurosurgeons at British Columbia's Children's Hospital (BCCH) adopted an aggressive surgical approach to the chiasmatic/hypothalamic tumors but became concerned because of what was perceived to be significant morbidity related to the surgery.

This study reviews separately chiasmatic and chiasmatic/hypothalamic tumors to analyze outcomes in these two groups of patients. The major purpose of this study was to determine, based on the experience at BCCH in the post CT scan era, if it is appropriate to recommend radical surgical resection of optic/hypothalamic tumors. This issue was addressed by assessing the incidence and severity of complications associated with aggressive surgical management of children with chiasmatic/hypothalamic gliomas and by analyzing the relationship between the extent of tumor resection and long-term tumor control. In addition, as a secondary issue, the study examined the impact of radiotherapy and chemotherapy with a combination of vincristine and actinomycin D in this group of patients.

## MATERIALS AND METHODS

The medical records of all patients newly diagnosed with an optic pathway glioma at BCCH from 1982 to 1996 were reviewed retrospectively. The hospital and clinic charts, operative reports, and radiological studies (CT and MR scans) of these children were reviewed to determine the clinical, pathological, and radiological features, the surgical and oncological management, as well as the morbidity and mortality. Patients with isolated prechiasmatic (optic nerve) tumors were excluded from the study. The CT and MRI scans of the study patients were reviewed by a single pediatric neuroradiologist (KP) to determine tumor volume (pre- and postoperatively), location and spread and the presence of other nonoptic pathway CNS tumors and hydrocephalus. The histopathology of the



**Figure 1:** Mathematical model for calculation of tumor volume from radiographs. The X, Y, and Z values for each tumor were measured from MRI or CT radiographs. The volume is calculated as the sum of one rectangular prism A, two cylinders B and C with the radius r, and a sphere D also with the radius r. Tumor volume(V) =  $\pi r^2 x' + 4/3 \pi r^3 + 2rx' y' + \pi r^2 y'$ .  $x = 2r + x'$ ,  $y = 2r + y'$ ,  $z = 2r$ .  $r = z/2$ ,  $y' = y - 2r$ ,  $x' = x - 2r$ ,  $z' = z$ .  $A = x' y' z'$ ,  $B = \pi r^2 x'$ ,  $C = \pi r^2 y'$ ,  $D = 4/3 \pi r^3$ .  $V = A + B + C + D$ .

tumors was reviewed by a pediatric neuropathologist, specifically to determine if tumors that had been classified as "low grade astrocytomas" by a prior neuropathologist were pilocytic or fibrillary astrocytomas.

To quantify tumor volume measurements of the asymmetrically shaped optic pathway tumors, the size of each tumor was measured in three planes on the radiographic films. The tumor volumes (pre- and postoperatively) were then calculated using an equation derived from the standard equations for volume of a cube, a sphere, and a rod, as illustrated in Figure 1. The total volume of the tumor included the volume of the solid and cystic components of the tumor. The extent of resection was calculated as a percentage of the postoperative and pre-operative tumor volumes. Based on this calculation, the patients were then categorized as having a "complete" (no visible tumor on postoperative imaging), "subtotal" (96-99%), "partial" (50-95%), or "limited" (<50%) resection.

No statistical analysis was performed as the numbers are too small and the significance would be difficult to interpret.

## RESULTS

### Demographics

There were 32 patients with optic pathway tumors involving the chiasm. Based on the anatomic site of origin and extension of the tumor, the patients were subdivided into two groups, namely those with chiasmatic tumors (n=14) and those with chiasmatic/hypothalamic tumors (n=18). The 14 patients with chiasmatic tumors had a lesion confined within the chiasm, and distinctly separate from the hypothalamus. All had radiographic evidence of tumor spread within the optic pathways. Ten of 14 patients in this group had pre- as well as postchiasmatic extension of tumor and eight had bilateral involvement. Patients with chiasmatic tumors presented at an average age of 5.9 years

**Table 1:** Clinical features on initial presentation for chiasmatic tumors

Feature	# Patients
Total number of patients	14
Reduced visual acuity	9
Symptomatic neoplasm elsewhere	4
Hydrocephalus	3
Visual field defect	2
Elevated intracranial pressure	2
Developmental delay	2
Precocious puberty	2
Neurofibromatosis (NF 1)	10

**Table 2:** Clinical features on initial presentation for chiasmatic/hypothalamic tumors

Feature	# Patients
Total number of patients	18
Reduced visual acuity	11
Elevated intracranial pressure	8
Failure to thrive	7
Hydrocephalus	7
Visual field defect	5
Precocious puberty	1
Hemiparesis	1
Diabetes insipidus	1
Neurofibromatosis	0

(2-15 years), and there was a male predominance, with 10 male and four female patients (2.5:1 ratio). Ten of the 14 patients with chiasmatic tumors (71%) were diagnosed clinically with neurofibromatosis type 1 (NF1) either at the initial assessment or later during follow-up.

Eighteen patients had chiasmatic/hypothalamic tumors occupying the suprasellar space, most with significant mass-effect. Five of 18 patients had subfrontal/interhemispheric extension, while one patient had tumor extension into the left Sylvian fissure. Five of 18 tumors had one or several

intratumoral cystic components, while the others were solid. Patients with chiasmatic/hypothalamic tumors presented at a mean age of 3.9 years (range 0.5-15.4 years) and half of the patients were less than two years old. Two patients were outliers, presenting at 14 and 15 years of age respectively. In this chiasmatic/hypothalamic group, nine were male and nine were female and no patient had NF.

### Clinical presentation

For the chiasmatic tumors, the typical presenting symptom was decreased visual acuity (9/14) (Table 1). Two patients showed global developmental delay and 2/14 patients presented with precocious puberty. Four patients presented with symptoms caused by a second, nonoptic chiasmatic brain tumor (4/14). These four patients were all diagnosed with NF1, and two of them showed signs of increased intracranial pressure secondary to a septum pellucidum glioma causing obstructive hydrocephalus. One had a unilateral partial third nerve palsy from a brainstem glioma, and the fourth patient had a visual field defect from a subependymal temporal lobe glioma.

In the chiasmatic/hypothalamic group of 18 patients, the most common presenting symptoms were reduced visual acuity (11), elevated intracranial pressure (8) and diencephalic syndrome (7) (Table 2). These tumors were commonly seen extending into the third ventricle, obstructing the foramen of Monro and causing hydrocephalus (seven patients).

### Pathology review

One of 14 patients with a chiasmatic tumor and 17 of the 18 patients with chiasmatic/hypothalamic tumors had a tissue diagnosis, and all were "low-grade astrocytomas" on original review. The neuropathologist at that time did not differentiate between pilocytic and diffuse types of low-grade astrocytomas. On repeat pathology review for this report, 15 patients with chiasmatic/hypothalamic tumors were found to have a pilocytic astrocytoma. The pathology was unavailable for rereview in the other two patients with chiasmatic/hypothalamic tumors and the one patient with a chiasmatic tumor.

### Management and tumor outcome

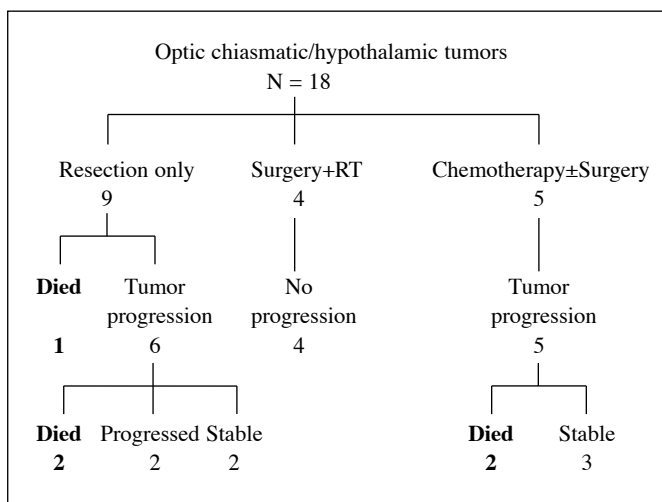
#### a) Chiasmatic tumors

All but one of the 14 patients in the chiasmatic tumor group were managed by surveillance with respect to lesions within the optic pathways (Table 3). The one patient subjected to surgery, had a biopsy and decompression of a cystic chiasmatic tumor

**Table 3:** Initial management of chiasmatic/hypothalamic gliomas

Group	Observation	Surgery only	Surgery* + radiation	Surgery* + chemo	Chemo only	Total
<b>Chiasmatic</b>	13	0	1	0	0	14
avg age (years)	5.7 (1.9-14.8)		8.4			
tumor vol (avg cc)	2.8 (1-9)		3			
<b>Chiasmatic/hypothalamic</b>	0	9	4	4	1	18
avg age (years)		2.7 (0.5-8.1)	9.2 (1.6-8.1)	1.8 (1.6-15.1)	2.1	
tumor vol (avg cc)		62.2 (14-141)	23 (13-28)	46.3 (7-81)	27	

\*Surgery refers to any patient who had a tissue diagnosis, regardless of extent of resection.



**Figure 2:** Overview of outcome and treatment of patients with chiasmatic/hypothalamic gliomas.

extending into the medial aspect of the right temporal lobe, followed by high dose cranial irradiation. Six of 14 patients with chiasmatic tumors had second non-optic gliomas of the CNS. Two patients had septum pellucidum lesions which were surgically resected for decompression of the foramen of Monro, two had brain stem gliomas, one of which was partially resected, and one patient had a subependymal temporo-parietal tumor which was irradiated. One child had a thalamic lesion treated with chemotherapy.

The one patient with surgery and radiotherapy was stable over 9.1 years of follow-up. None of the other 13 patients had progression requiring further treatment over an average follow-up of 5.8 years.

### **b) Chiasmatic/hypothalamic tumors**

Seventeen of the 18 patients with chiasmatic/hypothalamic tumors had surgical intervention as the initial management (Table 3). Nine patients had a resection of the suprasellar mass lesion without adjuvant therapy, four patients had a resection or biopsy followed by radiation therapy, and four patients had a resection or biopsy followed by postoperative adjuvant chemotherapy. One child was managed initially with chemotherapy alone without biopsy, and the reason for not having a surgical procedure could not be determined in this retrospective review. The patients undergoing chemotherapy received variable courses of vincristine and actinomycin D, and those receiving radiotherapy received focal, but not conformal, radiation at a dose of 5000cGy fractionated over five weeks. An overview of the outcomes of the patients with chiasmatic/hypothalamic tumors is provided in Figure 2.

In the nine patients with chiasmatic/hypothalamic tumors, who underwent surgery without further adjuvant therapy as the initial treatment, the average resection accomplished was 86% (range 21-99%), for an average postoperative residual of 4.2 cc (range 0.2-13cc). One patient died early postoperatively, and tumor progression occurred in six of the remaining eight patients, with an average time to progression of 18 months, and

with four patients progressing within one year. Of the six patients with tumor progression, three were treated with chemotherapy alone, two with surgery alone and one with surgery plus chemotherapy. Two of these six patients treated for progressive disease stabilized. Two developed further progression that was treated with radiotherapy, and both were stable at last follow-up. Two of the six patients treated for tumor progression died, one in the immediate postoperative period and another due to complications of chemotherapy.

Four patients with chiasmatic/hypothalamic tumors had resection or biopsy followed by postoperative radiotherapy as the initial treatment. None had tumor progression over an average follow-up of 7.1 (range 3.5-12.9) years.

Five patients with chiasmatic/hypothalamic tumors received chemotherapy with actinomycin and vincristine as part of the initial management. In four patients this was preceded by tumor resection, and in one patient no tissue diagnosis was obtained prior to starting chemotherapy. All five patients developed progressive disease at an average of 18 months after the initial treatment, with one tumor progressing within one year. At the time of progression four patients were treated with further courses of actinomycin and vincristine, and the fifth patient had tumor resection followed by adjuvant chemotherapy (actinomycin, vincristine, carboplatin). Of these five patients who had chemotherapy as part of their initial management, two patients died at 2.5 and 7.8 years respectively after diagnosis with progressive disease. The other three patients were stable at an average of 8.4 (6.4-11.2) years after diagnosis.

### **Management morbidity**

Two patients with chiasmatic tumors developed mild worsening of visual acuity that did not prompt further action, while one developed panhypopituitarism and another one developed hydrocephalus. One patient died following resection of a recurrent pontine glioma with a stable chiasmatic tumor. The one patient who had surgery for the optic chiasmatic tumor developed hypothalamic obesity and hydrocephalus during the course of follow-up.

The management morbidity at the time of last follow-up for the patients with chiasmatic/hypothalamic tumors is listed in Table 4. One patient died in the immediate postoperative period after the initial resection of tumor, and was not included in the analysis of progression/recurrence or follow-up. The duration of follow-up for the other 17 patients was a median of 6.3 (range 0.7-14.4) years.

Endocrinological dysfunction occurring as a result of surgical resection is discussed in the following section.

### **Extent of resection of chiasmatic/hypothalamic tumors**

In 15 of the 17 patients with chiasmatic/hypothalamic tumors who had surgery initially, the surgical goal was to resect as much tumor as possible, while in the other two patients the goal was simply to obtain a tissue diagnosis. Excluding the two patients with a biopsy only, the average resection achieved, based on postoperative imaging, was 89.8 % (Table 5). No complete resections were achieved as indicated by the postoperative imaging, although it was felt by the surgeon to have been achieved in three patients at the time of surgery. Eight patients had subtotal resections (>95% resection), six had partial resections (50-95%), and another three had limited resections

**Table 4:** Management morbidity at the time of last follow-up in patients with chiasmatic/hypothalamic tumors, according to different initial treatment modalities (excluding findings present on initial presentation).

Morbidity	Resection Only N=9	Surgery* + Radiation N=4	Surgery* + Chemo N=4	Chemo Only N=1
Seizures	3	1	0	0
Hemiparesis	1	1	1	0
Worse visual acuity	7	0	3	1
Panhypopituitarism	4	2	2	0
Hypothalamic dysfunction	2	2	2	0
Diabetes insipidus	4	0	0	0
Hydrocephalus	4	3	1	0
Infarction	4	0	0	0
Death	3	0	2	0

\*Surgery refers to any patient who had a tissue diagnosis, regardless of extent of resection.

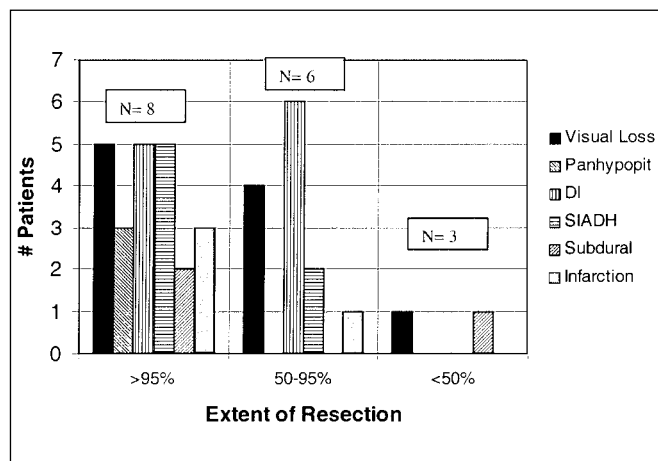
**Table 5:** Extent of resection and relationship to progression for patients with chiasmatic/hypothalamic tumors.

Extent of resection	>95%	50-95%	<50%
Age at diagnosis (years)	1.8	2.6	10.0
– avg (range)	(0.5-5.3)	(0.9-6.2)	(2.1-15.1)
Time to progression (years)	1.4	1.7	0.9
– avg (range)	(0.3-1.5)	(0.8-2.5)	
Duration of follow-up (years)	5.9	6.6	6.7
– avg (range)	(0.7-12.9)	(2.0-14.4)	(3.5-11.2)
Patients with progression	5	5	1
Total patients	8	6*	3

\*Note that one patient died in the early postoperative period and has been excluded from assessment of progression.

(<50%) with average residuals of 0.9cc, 6.8cc, and 20.1cc, respectively. There were fewer peri-operative complications associated with the limited resections (Figure 3). There was a higher incidence of panhypopituitarism in the subtotal resection group, compared to patients with lesser degrees of resection.

Considerable morbidity occurred with respect to salt and water balance in the peri-operative period. Five of eight patients with subtotal resection and all six patients with partial resection developed diabetes insipidus (DI), while no patient with limited resection or biopsy only did so. The syndrome of inappropriate antidiuretic hormone secretion (SIADH) developed in seven patients overall. One patient who underwent a partial resection died in the early postoperative period with complications related to salt and water balance. A further three patients with subtotal resections and one with a partial resection died in follow-up. There did not appear to be any correlation between the extent of resection (subtotal, partial, or limited) and the time to progression (Table 5).



**Figure 3:** Relationship of extent of resection and peri-operative morbidity, where N= the number of patients in each category of resection. Patients who underwent limited resections had fewer complications than the other two groups, especially with respect to endocrine and hypothalamic dysfunction. Subdural = subdural hematomas which were asymptomatic.

**DISCUSSION**

In this study, optic chiasmatic tumors were separated based on anatomical location into two groups, namely those involving only the optic chiasm ± the optic nerves ± the optic tracts (optic chiasmatic tumors) and those involving the optic chiasm and hypothalamus (optic chiasmatic/hypothalamic tumors). Some of the chiasmatic tumors were diagnosed initially with CT scans, and in these cases one might argue that involvement of the hypothalamus might have been difficult to rule out with surety. However, all of these patients went on to have MRIs either shortly after diagnosis or in follow up, and the MRI scans confirmed that the tumors involved the chiasm but not the hypothalamus. The two types of tumors were different with respect to their epidemiology, clinical presentation, size and

behavior. Chiasmatic tumors were small (avg. volume 2.8cc). They were also often associated with NF1 and with other associated intracranial gliomas and had a male predominance. These tumors presented primarily with visual loss. Increased intracranial pressure was unusual and, when present, tended to be related to an intracranial tumor other than the optic chiasmatic tumor. In four cases the tumor was an incidental finding in the investigation for another intracranial tumor associated with NF1. These tumors could be diagnosed on the basis of the MRI findings of tumor involving the optic tracts and/or optic nerves anteriorly. Thus biopsy was not done except in one child, who had an unusual cystic tumor. These optic chiasmatic tumors tended to behave in a hamartomatous manner, in that almost all remained stable without any specific treatment directed at the tumor.

Optic chiasmatic/hypothalamic tumors were large tumors at presentation (avg. volume 48cc) and had no sex predilection. In this series, unlike the optic chiasmatic tumors, they were not associated with NF1, although this association has been reported occasionally in other series.<sup>22,24</sup> The tumors presented with visual loss and intracranial hypertension, were often associated with a diencephalic syndrome and tended to grow progressively, unlike the more hamartomatous-behaving optic chiasmatic tumors. This study confirms prior reports that radical resection of optic/hypothalamic astrocytomas is achievable.<sup>17,22,23,25</sup> Of the 18 patients reviewed in this series, the extent of resection as demonstrated on postoperative scans was >95% in eight and between 50% and 95% in six. Others have also reported significant complications after surgical resection of optic gliomas but the morbidity in this series seems to be somewhat higher than reported by others.<sup>25</sup> This may, in part, be related to the radical resections that were performed in many of the patients, since these extensive resections were associated with the most morbidity, including panhypopituitarism, visual loss, and cerebral infarction. Perioperative disturbance of salt and water balance, specifically DI and SIADH, was frequent after radical surgery of chiasmatic/hypothalamic tumors, whereas no patient had such a problem after a limited (<50%) resection. The management of these patients, who may develop considerable electrolyte abnormalities, required the additional support of endocrinology and an intensive care unit knowledgeable of such problems. Despite that support, some patients fluctuated markedly between DI and SIADH patterns, making management extremely difficult. One patient in this series died, likely as a result of cerebral edema with fluctuating sodium levels that could not be controlled. Six patients went on to develop permanent DI. The difficult management of perioperative derangements of salt and water balance in this population deserves more consideration than has been given in the past.<sup>26</sup>

In this small study, there did not appear to be any difference in the probability of tumor progression or time to progression among the surgical groups undergoing variable degrees of resection. There was a high progression rate for those tumors treated by surgical resection alone, with all but two out of the eight surviving patients requiring chemotherapy and/or radiotherapy at some time after a radical resection to obtain tumor control. In contrast to the findings in this study, others have suggested that radical resection is associated with better tumor control. In a study of midline supratentorial low-grade

astrocytomas, Hoffman<sup>23</sup> found that patients who had a 50% or greater resection had a progression rate of 24% while those having less of a resection had a progression rate of 42.9%. The relationship between the extent of resection and progression rate was less clear for chiasmatic/hypothalamic gliomas. In a study by Wisoff et al,<sup>22</sup> 11 patients underwent "radical resection" (60-95%) of an optic chiasmatic/hypothalamic tumor with minimal morbidity; two patients died while six required no further therapy to obtain tumor control over an average follow-up of 27 months, a relatively short follow-up period.<sup>22</sup>

In this study, there was significant morbidity of radical resection of optic/hypothalamic astrocytomas. Since the value of such radical surgery in improving tumor control in the long-term is unproven, one has to question, as has Sutton et al,<sup>24</sup> whether one should adopt a more conservative surgical strategy from the perspective of tumor control, in this group of patients. One might still consider surgical resection to decompress the optic apparatus in patients who have progressive visual loss, in the hope that this might improve vision. However, based on the results of this series, one has to be concerned that resection has a significant chance of worsening vision. One might also consider surgical debulking of large tumors extending superiorly to the level of the foramen of Monro with associated hydrocephalus, in the hope of avoiding bilateral ventricular shunts or a unilateral shunt plus fenestration of the septum pellucidum. Again, one must be cognizant of the significant potential morbidity of the major resection that would be required for successful avoidance of a shunt.

With respect to nonsurgical treatment modalities, in the present study, radiotherapy seemed to be effective as an adjuvant treatment following partial resection or biopsy alone. There was no tumor progression over an average follow-up of 7.1 years for those treated with radiotherapy as part of the initial management. Three other patients received cranial irradiation for progressive tumors following partial resection + chemotherapy + re-resection. Following radiotherapy, no further tumor progression was seen in two of the three patients with an average post-radiotherapy follow-up of 5.2 years. The third patient died eight years after radiotherapy with progressive local disease and shunt dysfunction. These findings are in keeping with other reports, indicating a 10 year progression-free survival following radiotherapy of 75-90%.<sup>4,8,21</sup> Two of four patients undergoing initial adjuvant radiotherapy did develop panhypopituitarism, most likely as a result of the radiation. None of the patients receiving radiation were found to develop a secondary neoplasm or vasculopathy during follow-up, although these are known to occur.<sup>8,12-15</sup> The relative lack of complications from radiotherapy in this series may reflect the relatively short follow-up. Newer techniques of radiotherapy, such as conformal radiotherapy, radiosurgery,<sup>27</sup> fractionated stereotactic radiotherapy,<sup>28</sup> and proton beam therapy may limit the adverse effects of radiotherapy in this population. Nonetheless, there is considerable concern, which we share, about proceeding with radiotherapy to the immature and developing brain and we prefer to delay radiotherapy of any type for as long as possible.

The major nonsurgical option that might avoid or, at least, delay the need for radiotherapy is chemotherapy. In this series, the chemotherapy used was vincristine and actinomycin D, and all patients who received this chemotherapy as part of the initial

management, either after surgery or as the sole initial therapy developed progressive disease. Compared with resection alone, chemotherapy with vincristine and actinomycin D did not delay the average time to progression. However, only one patient progressed within the first year after chemotherapy, while four of six progressive tumors after resection only occurred within one year. These findings are consistent with other prior studies, which showed only a temporary control with this chemotherapy regimen.<sup>18,20,29</sup> Other newer chemotherapeutic regimens, such as vincristine and carboplatin or 6 thioguanine, procarbazine, dibromodulcitol, CCNU and vincristine appear to be more efficacious.<sup>18,30,31</sup>

## CONCLUSIONS

Optic chiasmatic and optic chiasmatic/hypothalamic tumors in children appear to be different epidemiologically in their clinical presentation and in their behavior. Any studies on these tumors should, therefore, separate these two groups of patients. With respect to the optic chiasmatic/hypothalamic tumors, this study suggests that, whereas radical resection can be achieved, such resections may be associated with more morbidity and no definite prolongation of time to progression compared to limited resections. We have therefore moved to a surgical procedure that provides a tissue diagnosis, if the diagnosis is unclear on the basis of neuroimaging, and decompresses the optic apparatus and/or ventricular system, with no attempt being made to do a more radical resection. In this small series, radiotherapy appeared to be effective in preventing subsequent progression. It is recognized that there are potential long-term complications, especially in young children, and we feel that radiotherapy should be delayed for as long as possible. Whereas chemotherapy with vincristine and actinomycin D was not effective in preventing tumor progression in this series of patients, it did delay radiotherapy in younger children. We are hopeful that newer chemotherapy regimens may turn out to be more effective, and our current practice is to use chemotherapy as our first line of treatment for these optic/hypothalamic tumors, reserving surgical debulking and/or radiotherapy for those in whom chemotherapy has failed.

## ACKNOWLEDGEMENT

We thank Dr. Glenda Hendson for her review of the pathology in these cases.

## REFERENCES

1. Oxenhandler D, Sayers M. The dilemma of childhood optic gliomas. *J Neurosurg* 1978;48:34-41.
2. Hoyt W, Baghdassarian S. Optic glioma of childhood. Natural history and rationale for conservative management. *Br J Ophthalmol* 1969;53:796-798.
3. Rush J, Younge B, Campbell R, MacCarty C. Optic glioma: long-term follow-up of 85 histopathologically verified cases. *Ophthalmology* 1982;89:1213-1219.
4. Flickinger J, Torres C, Deutsch M. Management of low-grade gliomas of the optic nerve and chiasm. *Cancer* 1988;61:635-642.
5. Tenny R, Jr. Laws ER, Younge B, Rush J. The neurosurgical management of optic glioma. *J Neurosurg* 1982;57:452-458.
6. Pierce S, Barnes P, Loeffler J. Definitive radiation therapy in the management of symptomatic patients with optic glioma. *Cancer* 1990;65:45-52.

7. Horwich A, Bloom H. Optic gliomas: radiation therapy and prognosis. *Int J Radiat Oncol Biol Phys* 1985;11:1067-1079.
8. Kovalic J, Grigsby P, Shepard M, et al. Radiation therapy for gliomas of the optic nerve and chiasm. *Int J Radiat Oncol Biol Phys* 1990;18:927-932.
9. Rodriguez L, Edwards M, Levin V. Management of hypothalamic gliomas in children: an analysis of 33 cases. *Neurosurgery* 1990;26:242-247.
10. Montgomery A, Griffin T, Parker R, Gerdes A. Optic nerve glioma: the role of radiation therapy. *Cancer* 1977;40:2079-2080.
11. Danoff B, Kramer S, Thompson N. The radiotherapeutic management of optic nerve gliomas in children. *Int J Radiat Oncol Biol Phys* 1980;6:45-50.
12. Servo A, Puranen M. Moyamoya syndrome as a complication of radiation therapy. *J Neurosurg* 1978;48:1026-1029.
13. Okuno T, Prenskey A, Grado M. The moyamoya syndrome associated with irradiation of an optic glioma in children. Report of two cases and review of the literature. *Pediatr Neurol* 1985;1:311-316.
14. Beyer R, Paden P, Sobel D, Flynn F. Moyamoya pattern of vascular occlusion after radiotherapy for glioma of the optic chiasm. *Neurology* 1986;36:1173-1178.
15. Kestle J, Hoffman H, Mock A. Moyamoya phenomenon after radiation for optic glioma. *J Neurosurg* 1993;79:32-35.
16. Rappaport R, Brauner R. Growth and endocrine disorders secondary to cranial irradiation. *Pediatr Res* 1989;25:561-567.
17. Hoffman H, Humphreys R, Drake J, et al. Optic pathway/hypothalamic gliomas: a dilemma in management. *Pediatr Neurosurg* 1993;19:186-195.
18. Aquino V, Fort D, Kamen B. Carboplatin for the treatment of children with newly diagnosed optic chiasm gliomas: a phase II study. *J Neurooncol* 1999;41:255-259.
19. Petronio J, Edwards M, Prados M, et al. Management of chiasmal and hypothalamic gliomas of infancy and childhood with chemotherapy. *J Neurosurg* 1991;74:701-708.
20. Rosenstock J, Packer R, Bilaniuk L, et al. Chiasmatic optic glioma treated with chemotherapy. A preliminary report. *J Neurosurg* 1985;63:862-866.
21. Jenkin D, Angyalfi S, Becker L, et al. Optic glioma in children: surveillance, resection, or irradiation? *Int J Radiat Oncol Biol Phys* 1993;25:215-225.
22. Wisoff J, Abbott R, Epstein F. Surgical management of exophytic chiasmatic-hypothalamic tumors of childhood. *J Neurosurg* 1990;73:661-667.
23. Hoffman H, Soloniuk D, Humphreys R, et al. Management and outcome of low-grade astrocytomas of the midline in children: a retrospective review. *Neurosurgery* 1993;33:964-971.
24. Sutton L, Molloy P, Sernyak H. Long-term outcome of hypothalamic/chiasmatic astrocytomas in children treated with conservative surgery. *J Neurosurg* 1995;83:583-589.
25. Medlock MD, Scott RM. Optic chiasm astrocytomas of childhood. 2. Surgical management. *Pediatr Neurosurg* 1997;27:121-128.
26. Daaboul J, Steinbok P. Abnormalities of water metabolism after surgery for optic/chiasmatic astrocytomas in children. *Pediatr Neurosurg* 1998;28:181-185.
27. Lim Y, Leem W. Two cases of gamma knife radiosurgery for low-grade optic chiasm glioma. *Stereotact Funct Neurosurg* 1996;66:174-183.
28. Debus J, Kocagoncu K, Hoss A, et al. Fractionated stereotactic radiotherapy (FSR) for optic glioma. *Int J Radiat Oncol Biol Phys* 1999;44:243-248.
29. Packer R, Sutton L, Bilaniuk L, et al. Treatment of chiasmatic/hypothalamic gliomas of childhood with chemotherapy: an update. *Ann Neurol* 1988;23:79-85.
30. Allen J. Initial management of children with hypothalamic and thalamic tumors and the modifying role of neurofibromatosis-1. *Pediatr Neurosurg* 2000;32:154-162.
31. Silva M, Goldman S, Keating G, et al. Optic pathway hypothalamic gliomas in children under three years of age: the role of chemotherapy. *Pediatr Neurosurg* 2000;33:151-158.