

## Argatroban therapy in patients with hepatic and renal impairment

doi: 10.1017/S0265021507002839

### EDITOR:

Following surgical procedures in the ICU, patients have a high risk for thromboembolic events and hence adequate anticoagulation is necessary. In most patients this can be successfully achieved with heparin. However, up to 3–5% of patients develop heparin-induced thrombocytopenia type II (HIT II). HIT II is characterized by an increased risk of thrombosis and requires a different anticoagulant treatment. Approximately 40–50% of HIT II patients will develop thrombosis when heparin is discontinued. Additionally, many patients require ongoing anticoagulation due to underlying diseases. Alternative agents that have been used in this setting include warfarin, low-molecular-weight heparin, danaparoid and lepirudin. However, there are disadvantages associated with these agents. For example, both low-molecular-weight heparin, and to a lesser extent, danaparoid cross-react with HIT antibodies. More importantly, most agents show unfavourable pharmacokinetic properties. Therefore, new anticoagulant drugs with a more suitable pharmacokinetic profile are necessary. Argatroban is a synthetic direct thrombin inhibitor that binds to the active site of thrombin and thereby inhibits thrombin-catalysed or -induced reactions including fibrin formation, activation of coagulation factors V, VIII and XIII, activation of protein C and platelet aggregation [1]. In this report, we describe argatroban therapy in two critically ill patients on the ICU and discuss current argatroban dose directives.

Case 1 was a 44-yr-old female patient transferred to our hospital for further treatment after accidental ligation of the right hepatic artery and right central bile duct during a laparoscopic cholecystectomy. The patient presented with a highly impaired blood circulation of the right liver lobe and a partially necrotic central bile duct. Following a right hemihepatectomy and biliary drainage, the patient developed a partial leakage of the biliary anastomosis. This was drained by continuous abdominal lavage. Subsequently, she became septic, developed

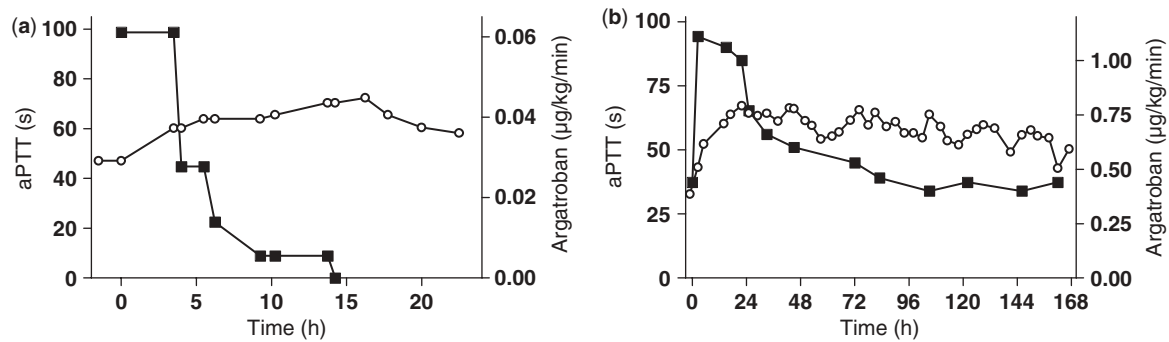
acute renal failure and was put on continuous veno-venous haemofiltration (CVVH). HIT II diagnostics were initiated after a deep venous thrombosis and HIT II was confirmed by antibodies to platelet factor 4. Subsequently, anticoagulation was changed to argatroban. At this point, liver dysfunction was apparent (aspartate aminotransferase  $215 \text{ UL}^{-1}$ , alanine aminotransferase  $89 \text{ UL}^{-1}$ ,  $\gamma$ -glutamyltransferase  $657 \text{ UL}^{-1}$ , alkaline phosphatase  $1151 \text{ UL}^{-1}$  and bilirubin  $23.1 \text{ mg dL}^{-1}$ ; normal range in our laboratory is  $<32$ ,  $<31$ ,  $<39$ ,  $<104$  and  $<1.5$ , respectively). Argatroban therapy was initiated as recommended by the manufacturer starting with  $0.6 \mu\text{g kg}^{-1} \text{ min}^{-1}$ . Coagulation was controlled after 2 h, showing an activated partial thromboplastin time (aPTT) of 91 s. Argatroban therapy was discontinued. Since aPTT did not return to targeted values within the following 4 h, the patient received four units of fresh frozen plasma (FFP). aPTT decreased within the following 18 h. Argatroban infusion was restarted the next day at  $0.06 \mu\text{g kg}^{-1} \text{ min}^{-1}$  (Fig. 1a). Initially, coagulation parameter remained within the therapeutic range (aPTT 50–70 s). Five hours after the start of argatroban infusion, however, aPTT increased again. Subsequently, argatroban infusion was reduced repeatedly. Despite this, aPTT increased further, and the infusion was stopped after 14.25 h (Fig. 1a). Coagulation returned to therapeutic values within 8 h.

Case 2 was a 70-yr-old male patient with myasthenia gravis treated with cortisone for several years who presented with spine fractures and received a kyphoplasty from segments T7 to L4. The patient developed severe right heart failure on postoperative day 1 followed by acute renal failure and pneumonia. The patient then showed multiple infarctions of the extremities and a platelet drop. Although laboratory tests for HIT II initially gave negative results, anticoagulation was changed to argatroban again aiming at an aPTT of 50–60 s. After the first 24 h, argatroban dose was reduced to half and continued for 7 days (Fig. 1b). Throughout the therapy no complications were observed and blood supply to the extremities resolved. Subsequently, the general condition of the patient improved. Following return of spontaneous diuresis, CVVH was terminated after 135 h of argatroban therapy.

Appropriate management of anticoagulation in ICU patients is of paramount importance. The direct

Correspondence to: Philipp-Alexander Brand, Department of Anaesthesiology and Intensive Care Medicine, University Hospital Schleswig-Holstein, Campus Kiel, Schwanebergweg 21, D-24105 Kiel, Germany. E-mail: pabrand@anaesthesie.uni-kiel.de; Tel: +49 431 597 2991; Fax: +49 431 597 3002

Accepted for publication 14 September 2007 EJA 4638  
First published online 22 October 2007



**Figure 1.**

(a) Argatroban started with one-tenth of the recommended dose for hepatic dysfunction in our first patient. A further reduction was necessary to avoid high aPTT levels. (b) The dose needed in our patient without hepatic dysfunction was half the recommended dose within the first 24 h and was reduced to one-fourth thereafter. Continuous veno-venous haemofiltration was terminated after 135 h. ■ Argatroban ( $\mu\text{g kg}^{-1} \text{min}^{-1}$ ); ○ aPTT (s).

thrombin inhibitor argatroban is a small, synthetic molecule that binds reversibly and specifically to the catalytic domain of thrombin and has been shown to be a reliable alternative in patients with HIT II [1]. Argatroban is bound 54% to serum proteins and is metabolized by microsomal cytochrome P450 enzymes in the liver to four metabolites with a five-fold weaker anticoagulant effect and excreted in the bile but not via the kidneys. Due to hepatic metabolism, it is recommended by the manufacturer to reduce argatroban to  $0.5 \mu\text{g kg}^{-1} \text{min}^{-1}$  in patients with hepatic dysfunction. In our first patient with hepatic dysfunction, however, argatroban had to be reduced to less than one-tenth of this dose in order to avoid excessive anticoagulation. More importantly, the argatroban dose was decreased repeatedly during the first 8 h of treatment.

Terminal elimination half-life of argatroban for healthy subjects ranges between 39 and 51 min, normally resulting in steady-state aPTT levels within 3 h. It has been reported that the half-life of argatroban used in patients with hepatic dysfunction is increased approximately two- to threefold. Total time on argatroban in that study, however, was only 4 h [2]. Given the increased half-life during hepatic dysfunction and the short application time in the aforementioned study, we suggest that argatroban probably did not reach a steady state. It has also been reported previously that argatroban accumulates in patients with a normal hepatic function. aPTT values remained increased after discontinuation of argatroban for 130 h in one patient [3]. This emphasizes the need for studies that exceed an application of 4 h [2,4]. Possible explanations for the observed low argatroban requirement in our case could be the severe liver dysfunction or an intraperitoneal reabsorption of argatroban containing bile fluid, or both. Furthermore,

the difference between fast and slow drug metabolizing subjects depending on hepatic enzyme activity may be responsible for the observed pharmacodynamic effects. Regardless of the underlying reason, we suggest that the usually recommended argatroban dose should be reduced significantly in patients with hepatic dysfunction if applied over a longer period of time.

In our second case, the argatroban dose was reduced to  $0.5 \mu\text{g kg}^{-1} \text{min}^{-1}$  in a critically ill patient with renal failure. Argatroban anticoagulation was not influenced by CVVH because coagulation and the required argatroban dose did not vary either during CVVH or after return of spontaneous diuresis. Others have also reported on argatroban therapy during continuous veno-venous haemodialysis (CVVHD) with a decreased argatroban dose ( $0.26 \mu\text{g kg}^{-1} \text{min}^{-1}$ ) that was finally discontinued in order to achieve target aPTT values [5]. We therefore suggest that neither CVVH nor CVVHD extract relevant amounts of argatroban.

Although argatroban can be safely used in patients undergoing CVVH/CVVHD without hepatic dysfunction, the recommended dose of  $2 \mu\text{g kg}^{-1} \text{min}^{-1}$  should be reduced in critically ill patients. The study suggesting  $2 \mu\text{g kg}^{-1} \text{min}^{-1}$  was performed during haemodialysis in patients with endstage renal disease and argatroban was terminated after 4 h [4]. The results of this study therefore may not pertain to ICU patients undergoing long-term CVVH. Comparable to our case, an excessive aPTT increase ( $>100$  s) was observed in three patients following argatroban administration with  $2 \mu\text{g kg}^{-1} \text{min}^{-1}$  on a cardiothoracic ICU [6]. The argatroban dose therefore probably should be routinely reduced if administered for longer than 24 h because argatroban clearance may be prolonged in critically ill patients.

Currently, there is no specific antidote for argatroban. In order to re-establish normal coagulation, FFP administration is recommended. In our first patient four units were sufficient to correct coagulation. Others have reported FFP not to be effective during argatroban therapy [5]. In that case, however, only 600 mL FFP were given per day and the volume applied thus was possibly insufficient for a bleeding patient. In contrast, a recent case report supports our observation that FFP can effectively compensate for argatroban overdose [7], whereas recombinant activated factor VII was not successful in this respect.

The choice of the anticoagulant on the ICU is still a challenge. For argatroban, we suggest to start routinely with reduced doses compared to the package insert, followed by an adjustment according to aPTT levels. Performed in such a manner, argatroban seems to be a safe drug for anticoagulation in patients with HIT II in the ICU.

P.-A. Brand, J. Scholz, N. Weiler, B. Bein  
Department of Anaesthesiology and Intensive  
Care Medicine  
University Hospital Schleswig-Holstein  
Campus Kiel, Kiel, Germany

J.-H. Egberts  
Department of General and Thoracic Surgery  
University Hospital Schleswig-Holstein  
Campus Kiel, Kiel, Germany

## References

1. LaMonte MP, Brown PM, Hursting MJ. Alternative parenteral anticoagulation with argatroban, a direct thrombin inhibitor. *Expert Rev Cardiovasc Ther* 2005; 3: 31–41.
2. Swan SK, Hursting MJ. The pharmacokinetics and pharmacodynamics of argatroban: effects of age, gender, and hepatic or renal dysfunction. *Pharmacotherapy* 2000; 20: 318–329.
3. Kubiak DW, Szumita PM, Fanikos JR. Extensive prolongation of aPTT with argatroban in an elderly patient with improving renal function, normal hepatic enzymes, and metastatic lung cancer. *Ann Pharmacother* 2005; 39: 1119–1123.
4. Murray PT, Reddy BV, Grossman EJ *et al.* A prospective comparison of three argatroban treatment regimens during hemodialysis in endstage renal disease. *Kidney Int* 2004; 66: 2446–2453.
5. Dager WE, White RH. Argatroban for heparin-induced thrombocytopenia in hepato-renal failure and CVVHD. *Ann Pharmacother* 2003; 37: 1232–1236.
6. Reichert MG, MacGregor DA, Kincaid EH, Dolinski SY. Excessive argatroban anticoagulation for heparin-induced thrombocytopenia. *Ann Pharmacother* 2003; 37: 652–654.
7. Yee AJ, Kuter DJ. Successful recovery after an overdose of argatroban. *Ann Pharmacother* 2006; 40: 336–339.

## An unusual fatal reaction to a test dose of aprotinin before elective thoracoabdominal aortic aneurysm repair

doi: 10.1017/S0265021507002797

### EDITOR:

Aprotinin (Trasylol; Bayer Corporation, Pittsburgh, PA, USA) is a serine proteinase inhibitor which inhibits the contact phase activation of haemostasis, preventing fibrinolysis and reducing thrombin generation [1]. Aprotinin has been shown to reduce blood loss and transfusion requirements in cardiac surgery [2]. As a protein derived from bovine lung, aprotinin possesses antigenic properties in human beings. Aprotinin is well known to produce hypersensitivity reactions of the anaphylactic type. The risk of anaphylaxis with primary exposure to

aprotinin is quite rare, but is approximately 2.8% upon re-exposure [2]. Timing of the re-exposure is also important. The majority of re-exposure reactions occurs within the first 3 months [2]. We report an atypical presentation of re-exposure to aprotinin several years after index exposure resulting in rapid, profound biventricular failure with progression to disseminated intravascular coagulation (DIC).

A 65-yr-old male presented for elective repair of a chronic Crawford type III thoracic aortic aneurysm. In 1998, the patient underwent surgical repair of a type A aortic dissection during which aprotinin was used. According to our records, this was the only time when this patient had been exposed to aprotinin. General anaesthesia was induced with fentanyl and midazolam. Neuromuscular blockade was achieved with pancuronium. The trachea was intubated

Correspondence to: Daniel Weil, Resident, Department of Anesthesiology and Critical Care, Hospital University of Pennsylvania, 3400 Spruce Street, Philadelphia, PA 19104, USA. E-mail: weild@uphs.upenn.edu; Tel: +1 215 662 7016; Fax: +1 215 662 7451

Accepted for publication 14 September 2007 EJA 4391  
First published online 9 November 2007