

# Cortical Location of Benign Paroxysmal Rhythms in the Electroencephalogram

Richard S. McLachlan, Neda Lubus

**ABSTRACT: Background:** Six/second spike waves, 14 and 6/second positive spikes and small sharp spikes are apiculate paroxysmal rhythms in the electroencephalogram, thought to be of no diagnostic importance. The cortical origin of these discharges is documented in this report. **Methods:** These waveforms were assessed in recordings from the surface of the cerebral cortex using implanted subdural electrodes in 61 patients monitored for possible epilepsy surgery. **Results:** Eight patients had 6/second spike wave, four had 14 and 6/second positive spikes and 3 had small sharp spikes. The 6/second spike waves were localised to the posterior cingulate gyrus, a more restricted region than would be predicted from scalp recordings and the 14 and 6/second spikes to the posterior mesial temporal cortex. Small sharp spikes were more widely distributed but also predominated in the posterior mesial temporal area. None of the discharges were congruent with the focus of seizure origin and no interaction with other interictal spikes was found. **Conclusion:** These benign paroxysmal rhythms can appear incidentally in the electrocorticograms of patients with focal epilepsy and should not be confused with focal pathological spike activity or considered to be of any value in localizing the seizure focus.

**RÉSUMÉ: Localisation corticale des rythmes paroxystiques bénins à l'électrocorticogramme. Introduction:** Les pointe-ondes à 6 cycles/seconde, les pointes positives à 14 et 6 cycles/seconde et les pointes brèves sont des rythmes paroxystiques apiculés auxquels on n'attribue pas d'importance diagnostique à l'électroencéphalogramme. L'origine corticale de ces décharges est documentée dans cet article. **Méthodes:** Ces ondes ont été évaluées lors d'enregistrements faits à la surface du cortex cérébral au moyen d'électrodes sous-durales implantées chez 61 patients sous observation en vue d'une chirurgie de l'épilepsie. **Résultats:** Huit patients avaient des pointe-ondes à 6 cycles/seconde, 4 avaient des pointes positives à 14 et 6 cycles/seconde et 3 avaient des pointes brèves. Les pointe-ondes à 6 cycles/seconde ont été localisées à la circonvolution postérieure du corps calleux, une région plus restreinte que celle prédite à partir des enregistrements de surface, et les pointes à 14 et 6 cycles/seconde au cortex temporal mésial postérieur. Aucune des décharges n'était congruente avec le foyer d'origine de la crise et aucune interaction avec d'autres pointes interictales n'a été observée. **Conclusion:** Ces rythmes paroxystiques bénins peuvent apparaître accessoirement à l'électrocorticogramme de patients présentant une épilepsie focale et ne devraient pas être confondus avec une activité de pointes pathologiques focales ou considérés comme un élément de localisation valable d'un foyer épileptique.

Can. J. Neurol. Sci. 2002; 29: 154-158

Six per second spike wave (6/s SW), 14 and 6/second positive spikes (14+6/s PS) and small sharp spikes (SSS) are electrographic curiosities which, when found in an otherwise normal electroencephalogram (EEG), are thought to be of doubtful clinical significance.<sup>1,2</sup> Such benign paroxysmal rhythms (BPRs) appear in a minority of subjects but are not rare. A challenge for particularly the novice electroencephalographer is to distinguish BPRs from their pathological counterparts which they resemble, namely focal spikes and generalised spike waves. Although BPRs have been well-described in the scalp recorded EEG, such is not the case for intracerebral recordings. We document the occurrence of 6/s SW, 14+6/s PS and SSS in intracranial recordings, directly from the surface of the cerebral cortex, using subdural electrodes.

## METHODS

Selected patients, admitted to an eight-bed epilepsy unit for investigation regarding possible surgery for intractable epilepsy, were implanted with subdural electrodes for telemetry recording. Intracranial recording was done, when seizure onset could not be lateralised or localised, using standard, scalp recorded EEG telemetry. We used our own locally designed tubular subdural

From the Department of Clinical Neurological Sciences, London Health Sciences Centre, London, ON Canada.

RECEIVED SEPTEMBER 27, 2001. ACCEPTED IN FINAL FORM JANUARY 7, 2002.

Reprint requests to: Richard S. McLachlan, Shaikh Khalifa Medical Center, P. O. Box 51900, Abu Dhabi, United Arab Emirates

electrodes, which consist of seven stainless steel concentric rings, 10-20mm apart, imbedded in silastic tubing.<sup>3</sup> These are inserted through burr holes to cover the cortical areas of interest (Figure 1). Monopolar referential recordings were made from the subdural electrodes, using a subgaleal reference. Simultaneous scalp EEG was not obtained. During subdural recording from 61 patients, note was made prospectively of any activity which had a morphology, frequency and duration, consistent with 6/s SW, 14+6/s PS or SSS.

## RESULTS

Benign paroxysmal rhythms appeared in the cortical recordings from 13 patients. Seven males and six females ranged in age from 15 to 47 years. In eight patients, discharges with the characteristics of 6/s SW were recorded. Figure 2 shows examples from six of these patients. The 14+6/s PS discharges appeared in four patients (Figure 3), including two who also had 6/s SW. Definite SSS could only be found in three patients (Figure 4). All of these waveforms were recorded exclusively during drowsiness or light sleep, except in two patients when 6/s SW was found in wakefulness. The Table shows the site of seizure origin and the pathology found at surgery in these patients.

Both the 6/s SW and 14+6/s PS appeared frequently in any one patient, mainly or exclusively in sleep and tended to appear in only two or three adjacent electrodes. The 6/s SW were well localised to electrodes recording from the posterior cingulate gyrus on either side while the 14+6/s PS appeared to arise from the posterior mesial temporal region (Figure 5). The SSS were less frequent and more widely distributed but also appeared to predominate in the posterior mesial temporal area where they exhibited a more complex polyphasic morphology. Similar discharges to these three waveforms were not found elsewhere in other cortical areas. In none of the patients were benign paroxysmal rhythms congruent with the seizure focus nor was there any interaction with other recorded pathological interictal spike activity. They appeared in the hemisphere opposite that containing the seizure focus in four

of the eight patients with 6/s SW, three of the four with 14+6/s PS and all three with SSS. BPRs were unilateral in all instances with the exception of one patient who had bilaterally synchronous 6/s SW in the posterior cingulate region, maximum on the left side. The right:left distribution for 6/s SW was 5:3, for 14+6/s PS 3:1 and for SSS 2:1.

## DISCUSSION

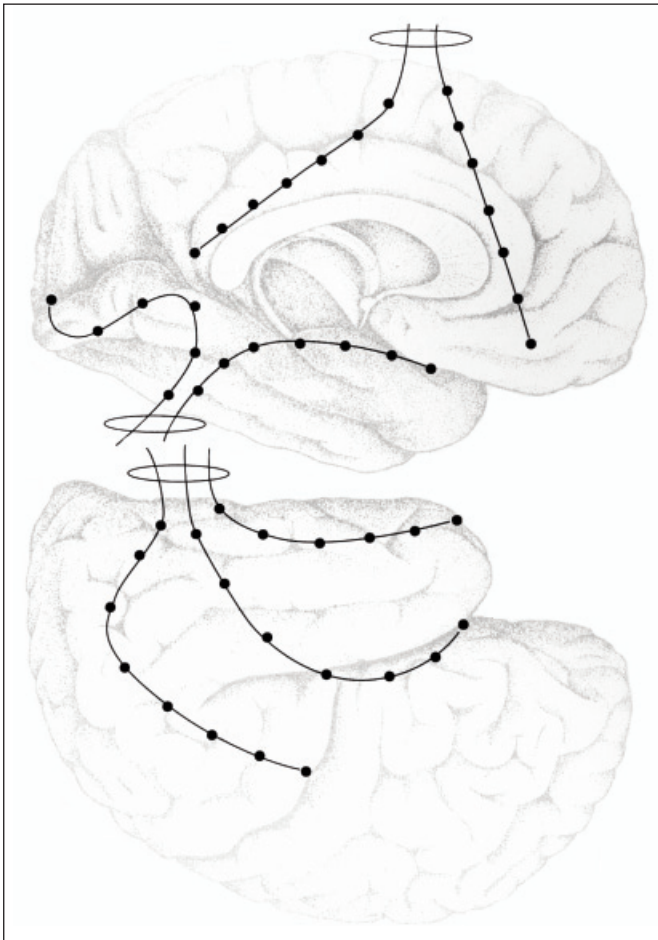
Six/second spike wave is typically low voltage, generalized, bilaterally symmetric, occurring in brief bursts of less than a second duration during drowsiness or wakefulness.<sup>2</sup> It can be expressed maximally in the anterior or posterior head.<sup>4</sup> Fourteen and six/second positive spikes are characterized by their implied polarity and frequency, predominance in the posterior head and unilateral or bilateral occurrence mainly in drowsiness and light sleep.<sup>1</sup> Small sharp spikes are generally, but not always, low voltage less than 50 microvolts, short duration less than 50 milliseconds, diphasic with unilateral or bilateral widespread fields maximum in the posterior temporal region during drowsiness and light sleep.<sup>1</sup> This is the first report of the characteristics of 6/s SW and 14+6/s PS recorded directly from the cortex. Small sharp spikes have previously been described in two patients with implanted depth electrodes in the temporal lobes.<sup>5</sup> Similar to our observations, these spikes were considered to be incidental findings that were widely distributed in the cortex appearing to predominate in the deep posterior temporal area.

The occurrence of 6/s SW in 13% of these epilepsy patients is higher than the 0.4-3% reported previously in routine EEG recordings.<sup>2,6</sup> However, the association of this waveform with epilepsy when it appears with other paroxysmal features,<sup>2</sup> may explain the high prevalence. The 6% of patients with 14+6/s PS is consistent with what has been found in routine EEGs<sup>6-8</sup> while the 5% with SSS is lower than expected, possibly reflecting the difficulty identifying this low voltage waveform in subdural recordings. The appearance of both 6/s SW and 14+6/s PS seen in two patients has been reported before.<sup>8</sup>

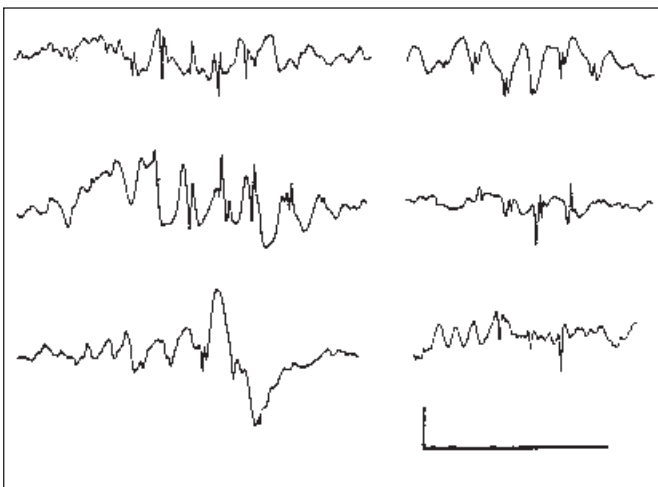
**Table:** Patients with benign paroxysmal rhythms

Age	Sex	6/s SW	14+6/sPS	SSS	State	Seizure origin	Lesion
17	F	+			sleep	suppl. motor	dysplasia
17	M	+			awake	frontal	dysplasia
18	M	+			sleep	rolandic	none
21	M	+			sleep	mesial temporal	mts*
31	M	+			awake	temporal	dysplasia
36	F	+			sleep	rolandic	benign tumor
15	M	+	+		sleep	occipital	infarct
18	F	+	+		sleep	frontal	none
16	M		+		sleep	mesial temporal	mts*
43	M		+		sleep	frontal	none
19	F			+	sleep	orbital frontal	cavernoma
24	F			+	sleep	mesial temporal	mts*
47	F			+	sleep	mesial temporal	mts*

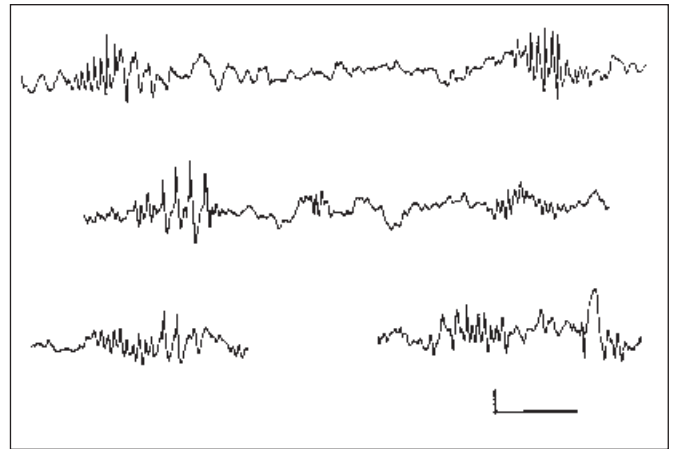
mts\* = mesial temporal sclerosis



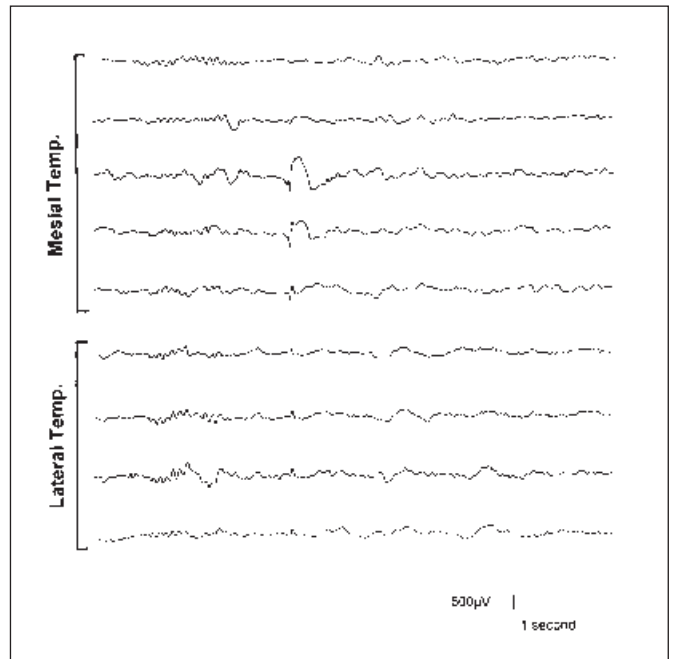
**Figure 1:** Example of typical subdural electrode placement from which incidental spikes were recorded.



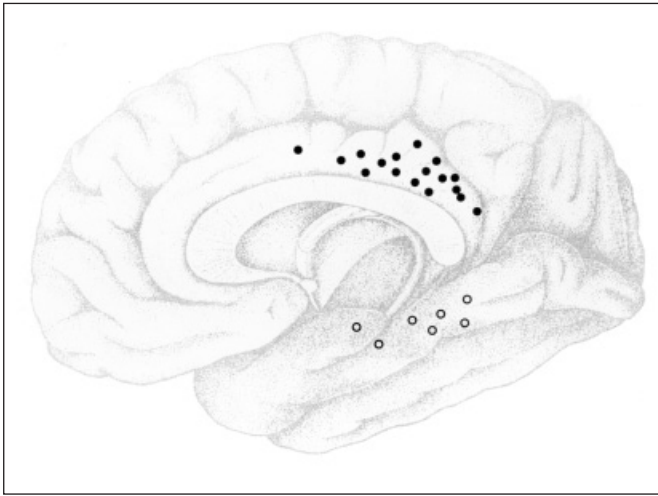
**Figure 2:** Direct cortical recording of 6/second spike wave from the posterior cingulate cortex in six patients. Bar is one second. Sensitivity is 50 $\mu$ V/mm.



**Figure 3:** Direct cortical recording of 14 and 6/second positive spikes from the posterior mesial temporal cortex in four patients. Note the spikes are negative in contrast to what is recorded on the scalp. Bar is 1 second. Sensitivity is 30 $\mu$ V/mm.



**Figure 4:** Monophasic small sharp spike over the lateral convexity of the temporal lobe is higher voltage, polyphasic and mainly positive in the mesial posterior temporal region. The electrodes are 10mm apart starting anteriorly from top to bottom for both mesial and lateral temporal areas.



**Figure 5:** Location of subdural electrodes recording 6/second spike waves (closed circles) and 14 and 6/second positive spikes (open circles).

Direct recording from the surface of the cortex circumvents the electrical impedance of the skull, skin and dura, inherent in scalp recorded EEG. Thus the amplitude of BPRs and other waveforms is approximately 10 times that recorded in the EEG. The exception is the SSS, which remains low in voltage over the brain convexity (but not in the mesial temporal region) making it difficult to identify. Although low in voltage, its wide electrical field allows it to be more evident when recorded from scalp electrodes. Another difference between scalp and subdural recording of BPRs is the polarity. All three waveforms tend to be opposite in polarity when recorded from the surface of the cortex compared to the scalp. This is particularly noticeable with 14+6/s PS, which are largely negative in subdural recordings (Figure 3). The difference in polarity may be explained by the area of maximum expression of these spikes in the mesial cortex of the brain and the electrophysiology of spike discharges that are associated with a dipole field from the superficial to the deep cortical layers. Thus scalp EEG recordings of BPRs generated from the mesial surface are expressing the “back end” of the dipole, which will be opposite in polarity to what is recorded on the mesial cortical surface. There is ample evidence of paroxysmal electroencephalographic and neuronal discharge from the mesial temporal structures of normal animals<sup>9,10</sup> but the exact physiology of BPRs in humans remains unknown. Interestingly, in light of the location of 6/s SW in this study, the other cortical region in normal rats from which spontaneous paroxysmal activity has been demonstrated is the posterior cingulate cortex.<sup>11</sup>

It would have been of interest to know if there was simultaneous expression of BPRs in the scalp EEG or indeed if perioperative scalp recorded EEGs had revealed similar spike activity in these patients. Although this information was not available all BPRs were easily identified on the cortical surface on the basis of their morphology. In addition, for SSS and 14+6/s PS, their observed location in the posterior temporal region is

consistent with their scalp distribution in the posterior head as recorded by EEG.<sup>1</sup> However the localised nature of the 6/s SW to the posterior cingulate gyrus is surprising considering the widespread distribution of this waveform in scalp recordings raising the possibility that this is a different focal paroxysmal event with a similar morphology.

It remains unclear whether BPRs are more likely to occur in cortex rendered hyperexcitable by epilepsy or in association with other conditions. Further, there is no empirical evidence that the presence of BPRs influences the outcome of epilepsy surgery; however, no studies have specifically addressed this issue including this one. Thomas and Klass<sup>2</sup> found that the occurrence of 6/s SW in an otherwise normal recording was associated with seizures in 36% of subjects compared to 24% in those without 6/s SW. Similarly, Hughes and Gruener<sup>12</sup> found that SSS predicted seizures in 48% compared to 15% without such a finding. Further, the incidence of SSS in the EEGs of Japanese epilepsy patients was 8.6% compared to 2.5% of those without epilepsy.<sup>13</sup> There continue to be reports, particularly in the psychiatric literature, of the predictive value of BPRs for mood disorders or so called neuro-vegetative symptoms, such as dizziness, nausea and palpitations.<sup>14-16</sup> However, most electroencephalographers consider that in general these are incidental findings which, unlike other types of focal spikes and generalized spike waves, do not predict the occurrence of epilepsy or any other disorder.<sup>1,17-20</sup> The low prevalence and other features of BPRs in this study support this latter contention.

#### REFERENCES

1. Reiher J, Klass DW. Two common EEG patterns of doubtful clinical significance. *Med Clin North America* 1968; 52: 933-940.
2. Thomas JE, Klass DW. Six-per-second spike-and-wave pattern in the electroencephalogram: a reappraisal of its clinical significance. *Neurology* 1968; 18: 587-593.
3. Dubeau F, McLachlan RS. Invasive electrographic recording techniques in temporal lobe epilepsy. *Can J Neurol Sci* 2000; 27: S29-S34.
4. Hughes JR. Two forms of the 6/sec spike and wave complex. *Electroencephalogr Clin Neurophysiol* 1980; 48: 535-550.
5. Westmoreland BF, Reiher J, Klass DW. Recording small sharp spikes with depth electroencephalography. *Epilepsia* 1979; 20: 599-606.
6. Radhakrishnan K, Santoshkumar B, Venugopal A. Prevalence of benign epileptiform variants observed in an EEG laboratory from South India. *Clin Neurophysiol* 1999; 110: 280-285.
7. Drury I. 14-and-6 Hz positive bursts in childhood encephalopathies. *Electroencephalogr Clin Neurophysiol* 1989; 72: 479-485.
8. Silverman D. Phantom spike-waves and the fourteen and six per second positive spike pattern: a consideration of their relationship. *Electroencephalogr Clin Neurophysiol* 1967; 23: 207-213.
9. Buzsaki G, Leung LS, Vanderwolf CH. Cellular bases of hippocampal EEG in the behaving rat. *Brain Res Rev* 1983; 6: 139-171.
10. Bragin A, Jando G, Nadasdy Z, van Landeghem M, Buzsaki G. Dentate EEG spikes and associated interneuronal population bursts in the hippocampal hilar region of the rat. *J Neurophysiol* 1995; 73: 1691-1705.
11. Leung L-WS, Borst JGG. Electrical activity in the cingulate cortex of the rat. 1. Generating mechanisms and relations to behavior. *Brain Res* 1987; 407: 68-80.
12. Hughes JR, Gruener G. Small sharp spikes revisited: further data on this controversial pattern. *Clin Electroencephalogr* 1984; 15: 208-213.
13. Saito F, Fukushima Y, Kubota S. Small sharp spikes: possible

- relationship to epilepsy. *Clin Electroencephalogr* 1987; 18:114-119.
14. Hughes JR. A review of the usefulness of the standard of EEG in psychiatry. *Clin Electroencephalogr* 1996; 27: 35-39.
  15. Boutros N, Fristad M, Abdollohian A. The fourteen and six positive spikes and attention-deficit hyperactivity disorder. *Biol Psychiatry* 1998; 44: 298-301.
  16. Inui K, Motomura E, Okushima R, et al. Electroencephalographic findings in patients with DSM-IV mood disorder, schizophrenia, and other psychotic disorders. *Biol Psychiatry* 1998; 43: 69-75.
  17. White JC, Langston JW, Pedley TA. Benign epileptiform transients of sleep. Clarification of the small sharp controversy. *Neurology* 1977; 27: 1061-1068.
  18. Reiher J, Carmant L. Clinical correlates and electroencephalographic characteristics of two additional patterns related to 14 and 6 per second positive spikes. *Can J Neurol Sci* 1991; 18: 488-491.
  19. Beun AM, van Emde Boas W, Dekker E. Sharp transients in the sleep EEG of healthy adults: a possible pitfall in the diagnostic assessment of seizure disorders. *Electroencephalogr Clin Neurophysiol* 1998; 106: 44-51.
  20. Jabbari B, Russo MB, Russo ML. Electroencephalogram of asymptomatic adult subjects. *Clin Neurophysiol* 2000; 111: 102-105.