

## Short Communication

**Cite this article:** Nordholm A, Kurtzhals JAL, Karami AM, Kania PW, Buchmann K (2020). Nasal localization of a *Pseudoterranova decipiens* larva in a Danish patient with suspected allergic rhinitis. *Journal of Helminthology* **94**, e187, 1–5. <https://doi.org/10.1017/S0022149X20000681>

Received: 22 June 2020

Revised: 28 July 2020

Accepted: 30 July 2020

**Key words:**

Zoonosis; cod worm; seal worm; *Pseudoterranova decipiens*; allergic reaction

**Author for correspondence:**

K. Buchmann,

E-mail: [kub@sund.ku.dk](mailto:kub@sund.ku.dk)

# Nasal localization of a *Pseudoterranova decipiens* larva in a Danish patient with suspected allergic rhinitis

A. Nordholm<sup>1</sup>, J.A.L. Kurtzhals<sup>2,3</sup>, A.M. Karami<sup>4</sup>, P.W. Kania<sup>4</sup> and K. Buchmann<sup>4</sup> 

<sup>1</sup>Department of Infectious Diseases, Copenhagen University Hospital (Rigshospitalet), Copenhagen, Denmark;

<sup>2</sup>Department of Clinical Microbiology, Copenhagen University Hospital (Rigshospitalet), Centre for Medical Parasitology, Copenhagen, Denmark; <sup>3</sup>Department of Immunology and Microbiology, University of Copenhagen, Copenhagen, Denmark and <sup>4</sup>Department of Veterinary and Animal Sciences, Faculty of Health and Medical Sciences, University of Copenhagen, Copenhagen, Denmark

**Abstract**

*Pseudoterranoviasis* is a zoonotic disease caused by nematode larvae of species within the genus *Pseudoterranova* (seal worm, cod worm). Most infections are gastrointestinal, oesophageal or pharyngeal, but here we report a nasal infection. A 33-year-old patient suffering from rhinitis for 1.5 years recovered a worm larva from the nose. Diagnosis was performed by morphological and molecular characterization, showing the causative agent to be a third-stage larva of *Pseudoterranova decipiens* (*sensu stricto*). Various infection routes are discussed.

**Introduction**

Nematode larvae of the genera *Anisakis*, *Pseudoterranova* and *Contracaecum* within the family Anisakidae have the potential to infect humans and cause a zoonotic disease termed anisakidosis. The life cycle for the three nematode types in the marine environment comprises the adult worms in marine mammals or fish-eating birds, third-stage infective larvae in first intermediate/transport hosts (invertebrates) and second transport hosts (various fish species). When the final host ingests the fish carrying infective larvae, the worm develops to the adult stage (McClelland, 2002). Humans may obtain infection following ingestion of inadequately processed fish meat (dishes based on raw fish are sushi, sashimi, ceviche, cold smoked fish and lightly marinated fish products) containing infective larvae (Gardiner, 1990; Ishikura, 2003). Most anisakidosis cases are caused by species within the genus *Anisakis* (Ishikura, 2003), some are caused by *Pseudoterranova* (Margolis, 1977) and a few are due to *Contracaecum* (Schaum & Müller, 1967; Shamsi & Butcher, 2011; Nagasawa, 2012; Strøm *et al.*, 2015). Whereas *Anisakis* spp. use cetaceans (whales) as final host, *Contracaecum* spp. and *Pseudoterranova* spp. apply various species of pinnipeds (seals) as final hosts, carrying the adult worms in the stomach. The vernacular name ‘seal worm’ is used for *Pseudoterranova* spp. as it reflects the association with the final host. The third-stage infective larvae often occur in the flesh of Atlantic cod *Gadus morhua* (Heuch *et al.*, 2011), and, therefore, the term ‘cod worm’ is commonly used for this parasite (Hafsteinsson & Rizvi, 1987; McClelland, 2002), although several other fish species serve as hosts (McClelland & Martell, 2001; Karpiej *et al.*, 2013; Kuhn *et al.*, 2013; Timi *et al.*, 2014). *Pseudoterranova* spp. nematodes are natural elements in the marine environment and clearly associated with the occurrence of the final hosts (Marcogliese *et al.*, 1996; Olafsdottir & Hauksson, 1997, 1998; Hauksson, 2002). Recently, the seal populations in Danish waters have increased markedly, resulting in the appearance of *Pseudoterranova decipiens* in local fish products (Perdiguer-Alonso *et al.*, 2008; Buchmann & Kania, 2012; Mehrdana *et al.*, 2014). Anisakidosis cases have been considered rare in Denmark, with only one reported case ascribed to *Anisakis* sp. following ingestion of lightly salted herring (Andreassen & Jorring, 1970), but with the advent of more exotic dishes based on raw or semi-raw fish products and an increasing abundance of infected marine mammals, the risk of contracting anisakidosis is considered increasing. The present report describes a human case of *P. decipiens* infection in Denmark, with an unusual localization of the worm larva.

**Case report**

A 33-year-old man was referred to the out-patient clinic at the Department of Infectious Diseases in April 2020, due to expulsion of a worm from the nose. Four days earlier, he had woken up early due to nasal irritation. Nose blowing resulted in expulsion of an approximately 4 cm white worm with pointed ends, which he brought to the out-patient clinic in a jar. He had a history of rhinitis with nasal running and congestion. This had developed abruptly

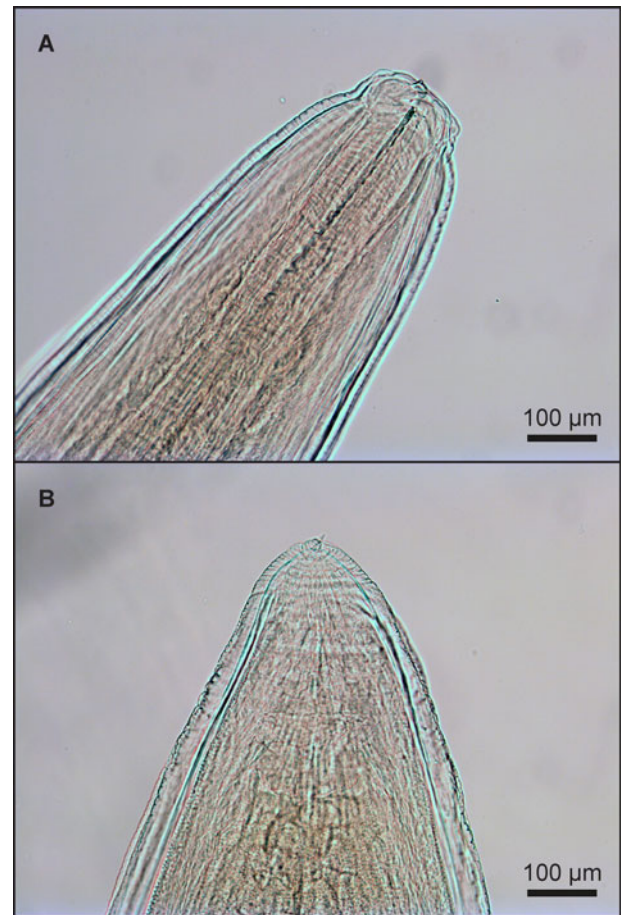
© The Author(s), 2020. Published by Cambridge University Press. This is an Open Access article, distributed under the terms of the Creative Commons Attribution licence (<http://creativecommons.org/licenses/by/4.0/>), which permits unrestricted re-use, distribution, and reproduction in any medium, provided the original work is properly cited.

1.5 years earlier and did not show any seasonality. Previous investigations of his rhinitis, including skin test and direct fibre-optic laryngoscopy, had not revealed any causative aetiology. He was treated intermittently with the corticosteroid mometasone furoate (Nasonex®) nasal spray. Besides the suspected allergic rhinitis, his medical history was unremarkable, and he received no additional regular medication. At presentation, the patient complained about runny nose and nasal congestion. He had no additional respiratory symptoms, no gastrointestinal symptoms and no dermatologic manifestations at the time of the consultation and at least two years previously. The patient reported occasional intake of raw or uncooked fish (sushi, sashimi, ceviche), but not within the last six months. Exposure also comprised swimming in Danish sea waters (Øresund and Kattegat, north of Zealand) every summer, last time in July 2019. His travel history was inconspicuous, and he had no close contact to animals. His physical examination was unremarkable. No blood samples were obtained, and no laboratory test results were available from the last seven years. The four-day-old worm larva was dry, with reddish discolouration of the tips. It was placed in isotonic saline and sent to the Department of Clinical Microbiology for further analysis. A tentative diagnosis was *Pseudoterranova* sp., and the worm was sent for confirmatory testing, as described below. The patient received no treatment. At follow-up after one and two months, the patient had persistent symptoms of rhinitis, but no additional symptoms or signs, and no additional worms had emerged.

## Materials and methods

### Diagnosis

The live nematode larva recovered by the patient was placed in physiological saline, whereafter it was fixed in ethanol (70%) and subsequently subjected to morphological and molecular diagnosis. The frontal and caudal parts of the larva were excised, cleared in lactic acid and mounted on microscope slides in Aquatex® mounting medium (Merck, Darmstadt, Germany) and studied under a light microscope (Leica, Germany), noting morphological characteristics of caudal and frontal ends (Valter et al., 1982). Partial molecular characterization was based on polymerase chain reaction (PCR) amplifying the gene locus internal transcribed spacer (ITS) region of ribosomal DNA (rDNA) (from 18S through ITS1, 5.8S, ITS2 to 28S) and the gene locus of the mitochondrial gene mtDNA *cox2*. DNA was isolated from sections of larvae using a QIAamp® DNA Mini Kit (250) (catalogue number 51306) and used for PCR in a Biometra T3 Thermocycler (Fisher Scientific, Roskilde, Denmark). The reaction mixtures consisted of DNA template (5 µl), one unit of BioTaq DNA polymerase (DNA-Technology, Aarhus, Denmark), 1 mM of each deoxynucleotide triphosphate (dNTP), 1.5 mM magnesium chloride and 1 µM of the two primers. The primers for amplifying the gene locus ITS region of rDNA were forward primer NC5 5'-GTA GGT GAA CCT GCG GAA GGA TCA TT-3' and reverse primer NC2 5'-TTA GTT TCT TTT CCT CCG CT-3' (Zhu et al., 2002, 2007), and for amplification of the mitochondrial gene mtDNA *cox2* we used primers 211F (TTTTCTAGTTATATAGATTGRTTT-YAT) and 210R (CACCA-CTCTTAAAATTATC) (Nadler & Hudspeth, 2000). PCR products were examined by electrophoresis in a 1.5% agarose gel with ethidium bromide and purified using the Illustra™ GFX™ PCR DNA Purification Kit (GE Healthcare, Brøndby, Denmark). Sequencing was conducted by Macrogen (Seoul, Korea) and



**Fig. 1.** Light microscopy of anterior (A) and caudal end (B) of *Pseudoterranova decipiens* larva recovered from the nose of a human patient.

analysed on the CLC Main Workbench v7.9.1 (Qiagen, Aarhus, Denmark) by BLAST® (Bethesda, Maryland, USA).

### Results

The worm larva recovered (fig. 1) had a total length of 41 mm and a maximum width of 1 mm. Morphological characteristics (larval sheath, boring tooth, nerve ring, excretory pore anteriorly to nerve ring, intestinal caecum, absence of ventricular appendage, tail spine (mucron) at the caudal end) were noted. Molecular diagnosis was based on PCR, with subsequent sequencing and alignment performed using the recovered ITS region sequences and sequences for the mitochondrial gene locus *cox2* with available sequences at GenBank. The ITS and *cox2* sequences from the *P. decipiens* isolate from the patient obtained GenBank accession numbers MT624318 and MT624317, respectively. The highest similarity was found for ITS (100%) with isolates of *P. decipiens* from the Baltic and the North Sea. Highest similarity (99.83%) for the *cox2* sequences were found with a *P. decipiens* isolate from Germany (River Elbe) (table 1).

### Discussion

Several species within the genus *Pseudoterranova* (*P. decipiens*, *P. krabbei*, *P. azarasi*, *P. bulbosa*, *P. cattani*) have been documented (Mattiucci & Nascetti, 2008; Timi et al., 2014), but the larva

**Table 1.** Comparison (similarity percentages) of sequences encoding rDNA (ITS) GenBank accession number MT624318 and mtDNA (*cox2*) GenBank accession number MT 624317 in *Pseudoterranova decipiens* (larva recovered from the nose of a Danish patient) with available GenBank sequences. Sequence lengths, excluding prime binding sites of *cox2* and ITS region, are 582 bp and 905 bp, respectively.

Parasite	Geographic origin	GenBank accession no.	Gene	% similarity
<i>Pseudoterranova decipiens</i>	Germany, Elbe	KU558723	<i>Cox2</i>	99.83
<i>Pseudoterranova decipiens</i>	Canada	HM147278	<i>Cox2</i>	99.61
<i>Pseudoterranova decipiens</i>	Unknown	AF179920	<i>Cox2</i>	99.31
<i>Pseudoterranova azarasi</i>	Brazil	KM853036	<i>Cox2</i>	98.24
<i>Pseudoterranova decipiens</i>	Denmark, Baltic Sea	KM273087	ITS region	100
<i>Pseudoterranova decipiens</i>	Germany, North Sea	JX138283	ITS region	100
<i>Pseudoterranova decipiens</i>	Poland	KU884886	ITS region	99.88
<i>Pseudoterranova decipiens</i>	Poland	KP645362	ITS region	99.88

isolated from a patient in the present study was diagnosed as *P. decipiens*, as judged from mitochondrial DNA *cox2* sequences. The species was originally described by Krabbe (1878) based on adult specimens from Icelandic seals (Buchmann, 2001). Human infections by third-stage larvae of *P. decipiens* are generally considered less severe than infections by species within the genus *Anisakis* eliciting anisakiasis associated with severe clinical signs due to intestinal or gastrointestinal penetration (Caramello *et al.*, 2003; Ishikura, 2003; Nascetti, 2011). *Pseudoterranova* spp. larvae also perform gastrointestinal invasion (Sawada *et al.*, 1983; Mercado *et al.*, 2001; Na *et al.*, 2013; Cavallero *et al.*, 2016), but they have mainly been reported from the stomach (Margolis, 1977; Pinel *et al.*, 1996; Koh *et al.*, 1999), oesophagus (Torres *et al.*, 2007) or throat (Little & Most, 1973; Chitwood, 1975; Juels *et al.*, 1975; Lichtenfels & Brancato, 1976; Skirnisson, 2006). Penetration into and through the host stomach wall (Little & MacPhail, 1972; Yu *et al.*, 2001) or even further (Amin *et al.*, 2000) are described, but several cases also show that the worm larva may leave the patient *per os* (Kliks, 1983; Arizono *et al.*, 2011; Dupouy-Camet *et al.*, 2014). A single nasal infection of a French female patient was reported by Brunet *et al.* (2017).

During the latest decades, the seal populations in Danish waters have increased considerably (Haarder *et al.*, 2014; Zuo *et al.*, 2018), and with the expanding final host occurrence the infection of cod with *P. decipiens* has increased markedly from a low level in the 1990s (Myjak *et al.*, 1994) to a higher level in recent years (Skov *et al.*, 2009; Buchmann & Kania, 2012; Mehrdana *et al.*, 2014) and, consequently, the risk of human infections with seal worm is likely to increase.

This is the first report of human pseudoterranoviasis in Denmark. The most likely source of the infection was raw or undercooked fish. From a localization in stomach, oesophagus, throat or mouth, the larvae could easily migrate to the nasal cavity. A less likely route – which, at present, is purely theoretical – is capture of newly hatched larvae (body length around 200 µm) in the nasopharynx during swimming/bathing in seawater. Such an infection route remains unconfirmed, but it is noteworthy that the very small larva hatching from the parasite egg is the third stage and, in principle, infective to the final host (Køie *et al.*, 1995; McClelland, 2002). The length growth of the parasite from 200 µm to 40 mm may take several months (McClelland, 2002). The seals in the Danish and adjacent marine waters carry adult *Pseudoterranova* nematodes (Lunneryd, 1991; Jensen & Idås, 1992; Jensen *et al.*, 1994; Aspholm *et al.*, 1995; Skrzypczak

*et al.*, 2014; Lunneryd *et al.*, 2015; Zuo *et al.*, 2018). In addition, the salinities in Danish waters – although decreasing from 33 to 7 ppt from the North Sea to the southern Baltic – allow *P. decipiens* egg development and hatching and subsequent survival of larvae for several weeks to months (Measures, 1996). Interestingly, none of these suggested exposure routes were immediately preceding the nasal expulsion of the worm larva. To the best of the patient's recall, the exposure had taken place at least six (raw fish consumption) and nine (swimming/bathing) months prior to the emergence of the worm. A prolonged survival time in a patient was previously reported by Brunet *et al.* (2017), but the present case suggests that it is possible for a *P. decipiens* third-stage larva to reside in a patient for more than half a year. The association with symptoms of allergic rhinitis is noteworthy and not reported previously. The symptoms had developed quite abruptly in this previously healthy man without prior history of allergy during childhood and youth. The symptom-provoking agent remains unknown, but it should be mentioned that the association between *Anisakis* infection and allergy is well documented (Daschner & Pascual, 2005; Arcos *et al.*, 2014; Carballeda-Sangiao *et al.*, 2014; Fæste *et al.*, 2014). Recent comparative proteomic studies have even shown that similar allergens are present in *P. decipiens* (Kochanowski *et al.*, 2019), with a potential to induce allergy in mice (Ludovisi *et al.*, 2017). Future cases should, therefore, apply serological (IgE and IgG) and specificity tests for further elucidation of the aetiology. The reported case frames the risk of human infections with anisakid nematode larvae and the need for preventive measures before consumption of wild captured marine fish products (EFSA, 2010). Sufficient heat treatment or prior freezing are measures recommended for inactivation of larvae in the products before consumption.

**Financial support.** This research received no specific grant from any funding agency, commercial or not-for-profit sectors.

**Conflicts of interest.** None.

**Ethical standards.** Consent for publishing the case was obtained from the patient.

## References

- Amin OM, Eidelman WS, Domke W, Bailey J and Pfeifer G (2000) An unusual case of anisakiasis in California, USA. *Comparative Parasitology* **67**, 71–75.
- Andreassen J and Jorring K (1970) Anisakiasis in Denmark. Infection with nematode larvae from marine fish. *Nordisk Medicin* **84**, 1492–1495 (in Danish).

- Arcos SC, Ciordia S, Roberston L, et al. (2014) Proteomic profiling and characterization of differential allergens in the nematodes *Anisakis simplex* sensu stricto and *A. pegreffii*. *Proteomics* **14**, 1547–1568.
- Arizono N, Miura T, Yamada M, Tegoshi T and Onishi K (2011) Human infection with *Pseudoterranova azarasi* roundworm. *Emerging Infectious Diseases* **17**, 555–556.
- Aspholm PE, Ugland KI, Jodestol KA and Berland B (1995) Seal worm (*Pseudoterranova decipiens*) infection in common seals (*Phoca vitulina*) and potential intermediate fish hosts from the outer Oslo Fjord. *International Journal for Parasitology* **25**, 367–373.
- Brunet J, Pesson B, Royant M, et al. (2017) Molecular diagnosis of *Pseudoterranova decipiens* s.s. in human in France. *BMC Infectious Diseases* **17**, 397–401.
- Buchmann K (2001) Profile: Harald Krabbe (1831–1917). *Systematic Parasitology* **49**, 233–234.
- Buchmann K and Kania P (2012) Emerging *Pseudoterranova decipiens* (Krabbe, 1878) problems in Baltic cod, *Gadus morhua* L., associated with grey seal colonization of spawning grounds. *Journal of Fish Diseases* **35**, 861–866.
- Caramello P, Vitali A, Canta F, Caldana A, Santi F, Caputo A, Lipani F and Balbiano R (2003) Intestinal localization of anisakiasis manifested as acute abdomen. *Clinical Microbiology and Infection* **9**, 734–737.
- Carballeda-Sangiao N, Olivares F, Rodriguez-Mahillo AI, Careche M, Tejada M, Moneo I and González-Muñoz M (2014) Identification of autoclave resistant *Anisakis simplex* allergens. *Journal of Food Protection* **4**, 605–609.
- Cavallero S, Scribano D and D'Amelio S (2016) First case of invasive pseudoterranoviasis in Italy. *Parasitology International* **65**, 488–490.
- Chitwood M (1975) *Phocanema*-type larval nematode coughed up by a boy in California. *The American Journal of Tropical Medicine and Hygiene* **24**, 710–711.
- Daschner A and Pascual CY (2005) *Anisakis simplex*: sensitization and clinical allergy. *Current Opinion in Allergy and Clinical Immunology* **5**, 281–285.
- Dupouy-Camet J, Gay M, Bourgau O, Nouchi A, Leger E and Dei-cas E (2014) Oesophageal localization: a rare complication of anisakidosis due to *Pseudoterranova*. *Presse Medicale* **43**, 81–92.
- EFSA (2010) EFSA Panel on Biological Hazards (BIOHAZ); scientific opinion on risk assessment of parasites, in fishery products. *EFSA Journal* **8**, 1543.
- Fæste CK, Jonscher KR, Dooper MMWB, Egge-Jacobsen W, Moen A, Daschner A, Egaas E and Christians U (2014) Characterisation of potential novel allergens in the fish parasite *Anisakis simplex*. *EuPA Open Proteomics* **4**, 140–155.
- Gardiner MA (1990) Survival of *Anisakis* in cold smoked salmon. *Canadian Institute of Food Science and Technology Journal* **23**, 143–144.
- Haarder S, Kania PW, Galatius A and Buchmann K (2014) Increased *Contracaecum osculatum* infection in Baltic cod (*Gadus morhua*) livers (1982–2012) associated with increasing grey seal (*Halichoerus grypus*) populations. *Journal of Wildlife Diseases* **50**, 537–543.
- Hafsteinsson H and Rizvi SSH (1987) A review of the sealworm problem: biology, implications and solutions. *Journal of Food Protection* **50**, 70–84.
- Hauksson E (2002) Decreases in sealworm (*Pseudoterranova* sp.) abundance in short-spined sea scorpion (*Myoxocephalus scorpius*) following declines in numbers of seals at Hvalseyjar, western Iceland. *Polar Biology* **25**, 531–537.
- Heuch PA, Jansen PA, Hansen H, Sterud E, MacKenzie K, Haugen P and Hemmingsen W (2011) Parasite faunas of farmed cod and adjacent wild cod populations in Norway: a comparison. *Aquaculture Environment Interactions* **2**, 1–13.
- Ishikura H (2003) Anisakiasis (2) Clinical pathology and epidemiology. pp. 451–473 in Otsuru M, Kamegai S, Hayashi S (Eds) *Progress of medical parasitology in Japan*. Vol 8. Tokyo, Japan.
- Jensen T and Idås K (1992) Infection with *Pseudoterranova decipiens* (Krabbe, 1878) larvae in cod (*Gadus morhua*) relative to proximity of seal colonies. *Sarsia* **76**, 227–230.
- Jensen T, Andersen K and Desclers S (1994) Seal worm (*Pseudoterranova decipiens*) infections in demersal fish from two areas in Norway. *Canadian Journal of Zoology* **72**, 598–608.
- Juels CW, Butler W, Bier JW and Jackson GJ (1975) Temporary human infection with a *Phocanema* sp. larva. *American Journal of Tropical Medicine and Hygiene* **24**, 942–944.
- Karpiej K, Dzido J, Rokicki J and Kijewska A (2013) Anisakid nematodes of Greenland halibut *Reinhardtius hippoglossoides* from the Barents Sea. *Journal of Parasitology* **99**, 650–654.
- Kliks MM (1983) Anisakiasis in the western United States: four new case reports from California. *The American Journal of Tropical Medicine and Hygiene* **32**, 526–532.
- Kochanowski M, Gonzales-Munoz M, Gomez-Morales MA, Gottstein B, Dabrowska J, Rozycki M, Cencek T, Muller N and Boubaker G (2019) Comparative analysis of excretory-secretory antigens of *Anisakis simplex*, *Pseudoterranova decipiens* and *Contracaecum osculatum* regarding their applicability for specific serodiagnosis of human anisakidosis based on IgG-ELISA. *Experimental Parasitology* **197**, 9–15.
- Koh MS, Huh S and Sohn WM (1999) A case of gastric pseudoterranoviasis in a 43-year-old man in Korea. *The Korean Journal of Parasitology* **37**, 47–49.
- Koie M, Berland B and Burt MDB (1995) Development to third stage larvae occurs in the eggs of *Anisakis simplex* and *Pseudoterranova decipiens* (Nematoda, Ascaridoidea Anisakidae). *Canadian Journal of Fisheries and Aquatic Sciences* **52**, 134–139.
- Krabbe H (1878) Ascarid worms from seals and toothed whales. *Kongelige Videnskabelige Selskabs Skrifter*. 43–51.
- Kuhn T, Benninghoff T, Karl H, Landry T and Klimpel S (2013) Sealworm *Pseudoterranova decipiens* s.s. infection of European smelt *Osmerus eperlanus* in German coastal waters: ecological implications. *Diseases of Aquatic Organisms* **102**, 217–224.
- Lichtenfels JR and Brancato FP (1976) Anisakid larva from the throat of an Alaskan Eskimo. *American Journal of Tropical Medicine and Hygiene* **25**, 691–693.
- Little MD and MacPhail JC (1972) Large nematode larva from the abdominal cavity of a man in Massachusetts. *The American Journal of Tropical Medicine and Hygiene* **21**, 948–950.
- Little MD and Most H (1973) Anisakid larva from the throat of a woman in New York. *The American Journal of Tropical Medicine and Hygiene* **22**, 609–612.
- Ludovisi A, Di Felice G, Carballeda-Sangiao N, et al. (2017) Allergenic activity of *Pseudoterranova decipiens* (Nematoda: Anisakidae) in BALB/c mice. *Parasites & Vectors* **10**, 290.
- Lunneryd SG (1991) Anisakid nematodes in the harbour seal *Phoca vitulina* from the Kattegat-Skagerrak and the Baltic. *Ophelia* **34**, 105–115.
- Lunneryd SG, Boström MK and Aspholm PE (2015) Sealworm (*Pseudoterranova decipiens*) infection in grey seals (*Halichoerus grypus*), cod (*Gadus morhua*) and shorthorn sculpin (*Myoxocephalus scorpius*) in the Baltic Sea. *Parasitology Research* **114**, 257–264.
- Marcogliese DJ, Boily F and Hammill MO (1996) Distribution and abundance of stomach nematodes (Anisakidae) among grey seals (*Halichoerus grypus*) harp seals (*Phoca groenlandica*) in the gulf of St. Lawrence. *Canadian Journal of Fisheries and Aquatic Sciences* **53**, 2829–2836.
- Margolis L (1977) Public health aspects of “codworm” infection: a review. *Journal of the Fisheries Research Board of Canada* **34**, 887–898.
- Mattiucci S and Nascetti G (2008) Advances and trends in the molecular systematics of anisakid nematodes, with implications for their evolutionary ecology and host-parasite co-evolutionary process. *Advances in Parasitology* **66**, 47–148.
- McClelland G (2002) The trouble with sealworms (*Pseudoterranova decipiens* species complex, Nematoda): a review. *Parasitology* **124**, 183–203.
- McClelland G and Martell DJ (2001) Surveys of larval sealworm (*Pseudoterranova decipiens*) infection in various fish species sampled from Nova Scotian waters between 1988 and 1996, with an assessment of examination procedures. *NAMMCO Scientific Publications* **3**, 57–76.
- Measures LN (1996) Effect of temperature and salinity on development and survival of eggs and free-living larvae of sealworm (*Pseudoterranova decipiens*). *Canadian Journal of Fisheries and Aquatic Sciences* **53**, 2804–2807.
- Mehrdana F, Bahlool QZ, Skov J, et al. (2014) Occurrence of zoonotic nematodes *Pseudoterranova decipiens*, *Contracaecum osculatum* and *Anisakis simplex* in cod (*Gadus morhua*) from the Baltic Sea. *Veterinary Parasitology* **205**, 581–587.

- Mercado R, Torres P, Muñoz V and Apt W** (2001) Human infection by *Pseudoterranova decipiens* (Nematoda, Anisakidae) in Chile: report of seven cases. *Memórias do Instituto Oswaldo Cruz* **96**, 653–655.
- Myjak P, Szostakowska B, Wojciechowski J, Pietkiewicz H and Rokicki J** (1994) Anisakid larvae in cod from the Southern Baltic Sea. *Archive of Fishery and Marine research* **42**, 149–161.
- Na HK, Seo M, Chai JY, Lee EK and Jeon SM** (2013) A case of anisakidosis caused by *Pseudoterranova decipiens* larva. *The Korean Journal of Parasitology* **51**, 115–117.
- Nadler SA and Hudspeth DS** (2000) Phylogeny of the Ascaridoidea (Nematoda: Ascaridida) based on three genes and morphology: hypotheses of structural and sequence evolution. *Journal of Parasitology* **86**, 380–393.
- Nagasawa K** (2012) The biology of *Contracaecum osculatum sensu lato* and *C. osculatum* A (Nematoda: Anisakidae) in Japanese waters: a review. *Biosphere Science* **51**, 61–69.
- Nascetti G** (2011) First molecular identification of the zoonotic parasite *Anisakis pegreffii* (Nematoda: Anisakidae) in a paraffin-embedded granuloma taken from a case of human intestinal anisakiasis in Italy. *BMC Infectious Diseases* **11**, 82.
- Olafsdottir D and Hauksson E** (1997) Anisakid (Nematoda) infestations in Icelandic grey seals (*Halichoerus grypus* Fabr. *Journal of Northwest Atlantic Fishery Science* **22**, 259–269.
- Olafsdottir D and Hauksson E** (1998) Anisakid nematodes in the common seal *Phoca vitulina* L. in Icelandic waters. *Sarsia* **83**, 309–316.
- Perdiguero-Alonso D, Montero F, Raga JA and Kostadinova A** (2008) Composition and structure of the parasite faunas of cod, *Gadus morhua* L. (Teleostei: Gadidae) in the North East Atlantic. *Parasites & Vectors* **1**(23), 1–18.
- Pinel C, Beaudevin M, Chermette R, Grillot R and Ambroise-Thomas P** (1996) Gastric anisakidosis due to *Pseudoterranova decipiens* larva. *Lancet* **347**, 1829.
- Sawada Y, Moriyama Y, Ebina T, Sasaki H, Yoshida Y, Tanabe K and Chiba R** (1983) Gastric terranovasis: report of 14 cases. *Gastroenterological Endoscopy* **25**, 713–717.
- Schaum E and Müller W** (1967) Heterocheilidiasis (case report). *Deutsche Medizinische Wochenschrift* **92**, 2230–2233.
- Shamsi S and Butcher AR** (2011) First report of human anisakidosis in Australia. *Medical Journal of Australia* **194**, 199–200.
- Skirnisson K** (2006) *Pseudoterranova decipiens* (Nematoda, Anisakidae) larvae reported from humans in Iceland after consumption of insufficiently cooked fish. *Icelandic Medical Journal* **92**, 21–25 (in Icelandic with English summary).
- Skov J, Kania PW, Olsen MM, Lauridsen JH and Buchmann K** (2009) Nematode infections of maricultured and wild fishes in Danish waters: a comparative study. *Aquaculture* **298**, 24–28.
- Skrzypczak M, Rokicki J, Pawliczka I, Najda K and Dzido J** (2014) Anisakids of seals found on the Southern coast of Baltic Sea. *Acta Parasitologica* **59**, 165–172.
- Strøm SB, Haarder S, Korbut R, Mejer H, Thamsborg SM, Kania PW and Buchmann K** (2015) Third-stage nematode larvae of *Contracaecum osculatum* from Baltic cod (*Gadus morhua*) elicit eosinophilic granulomatous reactions when penetrating the stomach mucosa of pigs. *Parasitology Research* **114**, 1217–1220.
- Timi JT, Paoletti M, Cimmaruta R, et al.** (2014) Molecular identification, morphological characterization and new insights into the ecology of larval *Pseudoterranova cattani* in fishes from the Argentine coast with its differentiation from the Antarctic species. *P. decipiens* sp. E (Nematoda: Anisakidae). *Veterinary Parasitology* **199**, 59–72.
- Torres P, Jercic MI, Weitz JC, Dobrew EK and Mercado RA** (2007) Human pseudoterranovosis, an emerging infection in Chile. *Journal of Parasitology* **93**, 440–443.
- Valter ED, Popova TI and Valovaya MA** (1982) Scanning electron microscope study of four species of anisakid larvae (Nematoda: Anisakidae). *Helminthologia* **19**, 195–209.
- Yu JR, Seo M, Kim YW, Oh MH and Sohn WM** (2001) A human case of gastric infection by *Pseudoterranova decipiens* larva. *The Korean Journal of Parasitology* **39**, 193–196.
- Zhu XQ, D'Amelio S, Palm HW, Paggi L, George-Nascimento M and Gasser RB** (2002) SSCP-based identification of members within the *Pseudoterranova decipiens* complex (Nematoda: Ascaridoidea: Anisakidae) using genetic markers in the internal transcribed spacers of ribosomal DNA. *Parasitology* **124**, 615–623.
- Zhu XQ, Podolska M, Liu JS, Yu HQ, Chen HH, Lin Z, Luo C, Song HQ and Lin RQ** (2007) Identification of anisakid nematodes with zoonotic potential from Europe and China by single-strand conformation polymorphism analysis of nuclear ribosomal DNA. *Parasitology Research* **101**, 1703–1707.
- Zuo S, Kania PW, Mehrdana F, Marana MH and Buchmann K** (2018) *Contracaecum osculatum* and other anisakid nematodes in grey seals and cod in the Baltic Sea: molecular and ecological links. *Journal of Helminthology* **92**, 81–89.