

## Rhabdomyoma of the Heart in Both of a Set of Twins

Nicola Scariano

Rhabdomyoma of the heart has been considered up to date an uncommon, congenital, cardiac lesion in man. Not more than one hundred cases are reported. Recently rhabdomyoma was found to be a common, cardiac lesion in the guinea pig, being detected in 10% of all animals sacrificed after experimental procedures. (1) Two cases of its occurrence in one of a set of twins have been published. The outcome, in both cases, of the apparently normal twin, is unknown. (2, 3) Not one case has been reported of its occurrence in both of a set of twins.

### Case Report

These male twins were the result of the fifth pregnancy of their 39 year old mother after 28 weeks of gestation. She had three full term healthy newborn females and one miscarriage. This pregnancy was complicated by mild hypertension and ankle edema. She received no medications prior to admission. Her blood group is A. The Rh factor is C D e hr. A detailed study of this family did not show any history of congenital heart disorder nor any consanguinous union.

At time of delivery two separate placentas and membranes were found. Anastomoses between the two placentas were not grossly demonstrated. The vases were not injected.

#### TWIN A

The first twin was delivered by forceps rotation. He weighed 4.10 Lb at birth and cried immediately after delivery. Shortly after birth a slight jaundice developed, the respiration became irregular and rapid and there was slight cyanosis about the eyes; for this reason he was kept in oxygen for one day. He did well for seven days. On his eighth day of life he became listless, abdominal breathing started with periods of apnea. The baby regurgitated formula and mucous, passed small amounts of bright red material per rectum, the pulse rate was 240/m, the liver was palpable 3 fingers below the costal margin. An EKG evidenced a paroxysmal tachy-

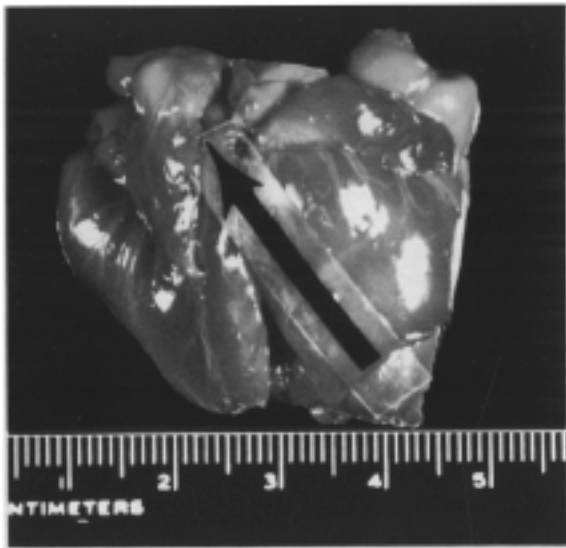

Fig. 1. Twin A - Heart. At the arrow is bulging one of the nodules

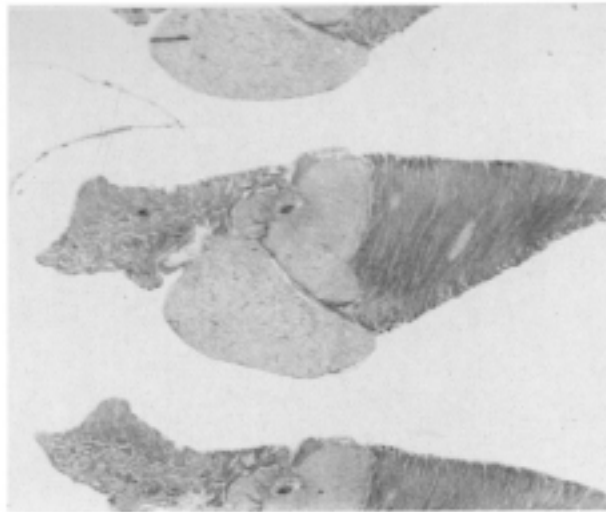


Fig. 2. Twin A - Heart. Complete section - H+E,  $\times 15$

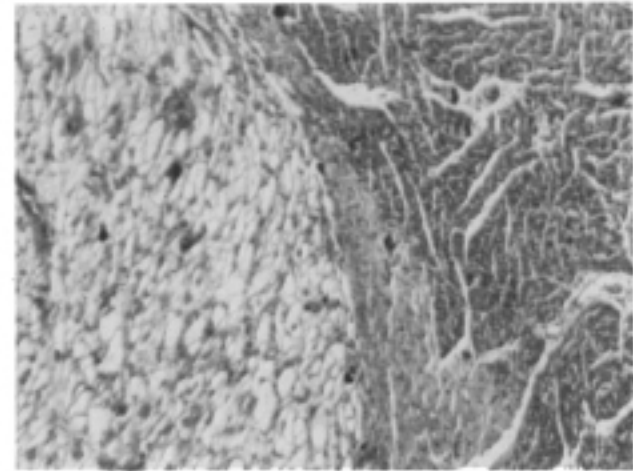


Fig. 3. Twin A - Heart. Microscopic section at the junction of normal and abnormal tissue; Spider cells - H+E,  $\times 125$

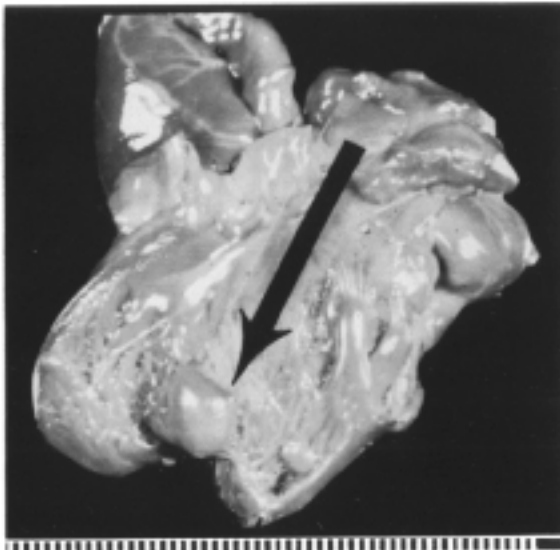

Fig. 4. Twin B - Heart. Nodule bulding into the left

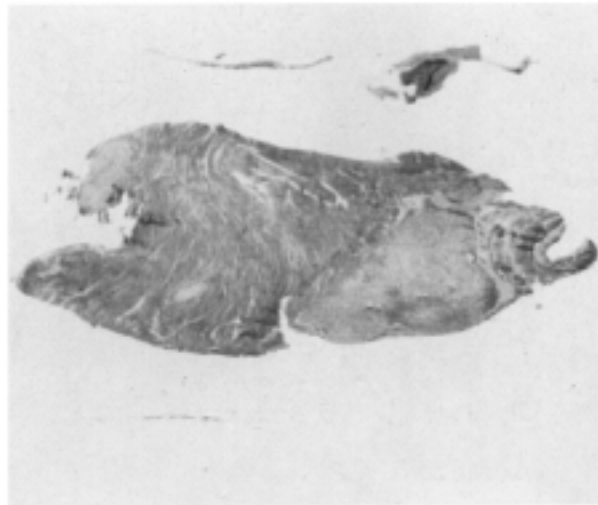

Fig. 5. Twin B - Heart. Complete section - H+E,  $\times 15$

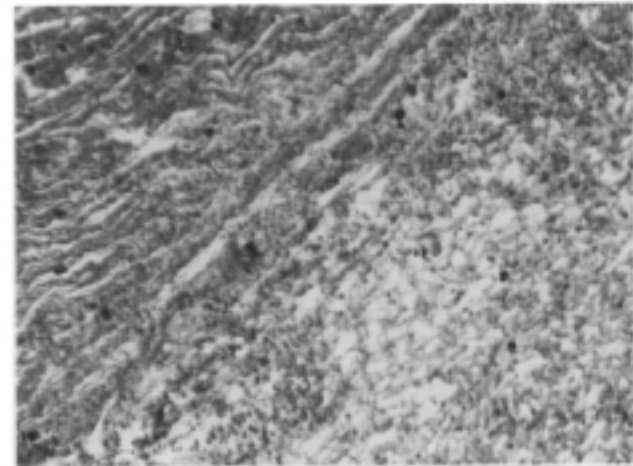
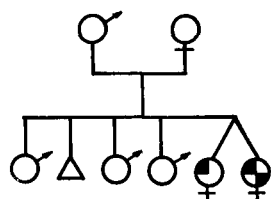


Fig. 6. Twin B - Heart. The same as fig. 3 - H+E,  $\times 125$

cardia due to heart block. There was no evidence of heart enlargement or displacement on x-ray. The baby was placed again in oxygen and digitalized, the pulse decreased to 120/m but he remained listless, passed large amount of bright red blood in bowel movements, became unresponsive and rigid and at his tenth day of life ceased to breathe and died. Laboratory data revealed Hb 15.8 Gm. - Hematocrit 47.3% - WBC 25000 - RBC 6000000 Direct Coombs Test negative - Bilirubin Total 17 MGM% - Bilirubin free 1.0 MGM%.



- Rhabdomyoma of the heart
- ◌ Patent ductus arteriosus
- △ Fetus of unknown sex

Genealogic tree of the family

Necropsy findings are limited to the heart. The heart occupied the usual position and layed free in the pericardial sac bathed in approximately 5 ml of clear-ricteric fluid. The heart weighed 19 gms and measured  $5 \times 3.5 \times 2.5$  cms. Bulging from the apical portion of the right and left ventricle, as well as the basilar lateral portion of the left ventricle, there were nodules which at the apex measured up to 6 mm in diameter. The nodules were firm, pale and apparently encapsulated. The cardiac muscle was firm in consistency and the wall of the right ventricle measured 4 mm in thickness and that of the left 7 mm. The cusps and leaflets of all valves were thin, smooth and translucent. The other organs were healthy. There was not hepato-splenomegaly nor tuberous sclerosis of the brain.

**Histology:** Microscopic examination of the hematoxylin and eosin stained sections through one of these nodules revealed that it consisted entirely of spider cells with centrally or peripherally placed nuclei, markedly vacuolated cytoplasm with thin fibers running radially from the nucleous in an irregular fashion toward the periphery of the cells. The celular margins were quite distinct. The nuclei were small, round or oval. Several microscopic areas in the myocardium contained small masses of similar cells. The junction of these nodules with the normal myocardium presents a sharp transition but there is not evidence of any capsule. No histological abnormalities were apparent in other organs except an extramedullary erythro-poiensis of liver and spleen.

## TWIN B

The second twin was delivered by podalic version and breech extraction. He weighed 6.6 Lb. He lived one hour. He was hydropic and did not breathe. The cord blood showed Bilirubin total 1.6 MGM% - Bilirubin free 0.5 MGM% Blood Group O - Rh factor D C e hr - Direct Coombs Test negative.

Necropsy showed marked tissue edema of the whole body. The peritoneal cavity contained approximately 400 ml of clear straw colored fluid. The heart weighed 12.5 Gms. There was a minimal amount of subepicardial fat. The epicardium was pale, smooth and translucent except for mottled areas of hemorrhage present over

the walls of both the right and left ventricles. A bulging nodule measuring 0.8 cm in diameter lay within the myocardium of the lateral aspect of the right ventricle. Two other similar nodules of similar size lay in the myocardium beneath the epicardium of the posterior wall of the left ventricle and these bulged into the ventricle itself. All of these nodules were fairly firm in consistency and yellow in color. The ductus arteriosus was widely patent. The valves were of normal size and contained no defects. The endocardium of all chambers of the heart was thin, smooth and transparent. The remaining organs were healthy.

Histology: Cross sections of the heart revealed areas of the types of tissue in the other twin with spider cells. Extramedullary erythropoiesis of liver and spleen, noted already in the other case, was present.

### Discussion

The diagnosis of rhabdomyoma of the heart in our case was not made *intra vitam*. It was not suspected in the case of twin A, despite the fact that he showed signs of congestive heart failure and EKG changes, because the heart was not enlarged on x ray. On autopsy both hearts were not found increased in size. It is evident that a normal size heart by x ray is not sufficient to rule out such a lesion. During the last year, few cases have been reported in the literature where the diagnosis of rhabdomyoma of the heart was made *intra vitam* by catheterization, angiocardigraphy and cine-cardiography, 4, 5 and for the first time, the lesion was removed successfully during cardiopulmonary by-pass. (5) In view of this very recent development of cardiac surgery, as far as the possibility of the excision of these nodules is concerned, the importance of an early diagnosis is evident.

Unfortunately, in our case, the hearts had been fixed in Zenker and attempts to apply the histochemical technics outlined by some authors (2, 6) were fruitless and we have been unable to bring any contribution to the knowledge of the histochemical structure of this lesion. Knowing the biochemical composition of the intracellular material of this abnormal cardiac tissue, which seems to be glycogen, and of the enzymes involved in its metabolism, would clarify the pathogenesis of this lesion. We will know if we are dealing with a congenital condition primarily morphological in nature or with an inborn error of metabolism in the strict sense where a chemical abnormality, genetically induced after birth, is detectable. While morphological cardiac defects, still of obscure etiology, seem to be discordant in twins either mono or dizygotic, (7, 8) glycogen storage disease of liver and kidney is well documented to be a congenital and familial disorder due to absence of glucose -6-phosphatase transmitted as a simple autosomal recessive. (9) Glycogen storage disease, of the heart, another different form of glycogen storage disease characterized also by deposition of glycogen in the heart, probably transmitted as a rare recessive, seems due to a similar mechanism.

Despite the fact that our like-sex twins had separated blood supplies and were different in size, Twin B being hydropic, we assume they were monozygotic having the same blood group, the same color of eyes and hair, and very much alike plantar prints pattern. Of the two only twin A showed evidence of a widely patent ductus arteriosus which is in accordance with the previously noticed discordance as far as morphological cardiac defects in twins is concerned. On the other hand, both had multiple rhabdomyomas of the same organ. Was this lesion genetically determined of the same type of inborn errors of metabolism or must it be regarded as the result of some insult early in gestation, as it seems probable? The importance of maternal diseases and accidents has been demonstrated in the pathogenesis of developmental defects (10). It is possible that the mild form of untreated preclampsia which affected the patient was the cause of this anomaly or perhaps the same factors responsible for the preeclamptic syndrome were the causative agent of the cardiac lesion.

This hypothesis is to be confirmed by further investigation. This study can be facilitated by the fact that this lesion, as stated in the beginning (1), is found with relative frequency in the guinea pig which appears to be a suitable animal for combined study of genetic and environmental factors.

### References

1. ROONEY J. R.: Rhabdomyomatosis in the heart of the guinea pig. *Cornell Vet*, 31: 388, July 1961.
2. MORALES J. B.: Congenital rhabdomyoma, Tuberosus sclerosis and splenic histiocytosis. *Arch. Path. Chicago*, 71: 485, May 1961.
3. FORBER S.: Rhabdomyoma in one of newborn twins. *Clin. Path. Con. The children's medical Center Boston J. of Ped.*, 55: 240, August 1959.
4. BUCHS S.: Verlauf eines Klinisch diagnostizierten Rhabdomyoms des Herzens beim jungen Mädchen. *Cardiologia*, 37: 50, 1960.
5. TOBER R. E.: Diagnosis and surgical treatment of intracardiac myxoma and rhabdomyoma. *J. Thor. Car. Surg.* 40: 337, September 1960.
6. BEAIRD J.: Congenital Rhabdomyoma of the heart. Case Report with Histochemical Study of Tumor Polysaccharides. *Cancer*, 8: 916, 1955.
7. UCHIDA I. A.: Discordant heart anomalies in twins. *Am J. Hum. Gen.*, 9: 1933, 1957.
8. GEDDA L.: Le cardiopatie congenite dei gemelli. *Acta Tertii Europaei de cordis scientia Conventus.* Roma, 1960.
9. HSIA D. Y.: *Inborn Errors of Metabolism*. Chicago The Year Book Pub. Inc., 137, 1959.
10. INGALLS T. H.: Cause and Prevention of Developmental Defects. *J. Am. Med. Assn.*, 61: 1047, July 14, 1956.

SUMMARY

A case of congenital multiple rhabdomyoma of the heart in both of a set of twins of like sex is presented. A separated diamnionic dichorionic placenta was found. However because both twins had the same sex, the same color of eyes, the same blood group and very similar plantar prints pattern they were considered MZ. Twin A died after 10 days because of intractable heart failure. Twin B died one hour after birth of hydrops fetalis. The autopsies showed the presence of multiple rhabdomyoma in the walls of both hearts and in Twin B a widely patent ductus arteriosus. No other extracardiac anomalies were noted. The diagnosis of rhabdomyoma of the heart, as is usual, was not made. It should be suspected in any infant who shows evidence of cardiac disease. On the other hand, this first case, known so far in the world literature of congenital rhabdomyoma of the heart in both twins could be an important contribution to the knowledge of the nature of this so discussed lesion.

RIASSUNTO

È riportato un caso di rhabdomyoma multiplo del cuore in due gemelli di uguale sesso, frutto di una gravidanza bicoriale-biamniotica. I due gemelli furono considerati monozigoti. Il primo gemello morì dopo 10 giorni per scompenso cardiaco. Il secondo, un'ora dopo la nascita per idrope fetale. Le autopsie dimostrarono rhabdomyomi multipli nella parete di entrambi i muscoli cardiaci e nel caso del secondo gemello un dotto arterioso ampiamente aperto. Non furono trovate anomalie a carico degli altri organi. La diagnosi di rhabdomyoma, come accade di solito, non fu fatta *intra vitam*. Dovrebbe essere sospettata in ogni neonato che mostra sintomi a carico del cuore. Questo primo caso, segnalato finora nella letteratura, di rhabdomyoma del cuore occorso in entrambi i gemelli, potrebbe essere un importante contributo alla conoscenza della patogenesi di questa rara, tanto discussa, lesione cardiaca.

RÉSUMÉ

L'on rapporte sur un cas de rhabdomyome multiple cardiaque chez deux jumeaux du même sexe, bichoriaux, biamniotiques, que l'on a considéré MZ. Le premier jumeau mourut à 10 jours par insuffisance cardiaque, tandis que le deuxième mourut un heure après la naissance par hydrope fœtale. Les autopsies démontrèrent chez tous les deux des rhabdomyomes multiples dans les parois des muscles cardiaques et, chez le deuxième jumeau, un ductus arteriosus bien ouvert. L'on ne trouva pas d'autres anomalies concernant les autres organes. La diagnose de rhabdomyome, comme d'habitude, n'eût pas lieu *intra vitam*; il faudrait le suspecter chez tout enfant présentant des symptômes cardiaques. Ce cas, qui est le premier signalé dans la littérature, de rhabdomyome cardiaque concordant chez deux jumeaux, pourrait constituer une contribution importante à la connaissance de la pathogénèse de cette lésion cardiaque, rare et tant discutée.

ZUSAMMENFASSUNG

Die Arbeit bringt einen Fall von *Rhabdomyom multipl. cordis* bei zwei Zwillingen aus diamnionischer und dichorionischer Schwangerschaft. Die Zwillinge wurde als eineiig angesehen. Der erste Zwilling starb nach 10 Tagen an Herzdekompensation, der zweite eine Stunde nach Geburt an *Hydrops foetalis*. Bei Autopsie zeigten beide Zwillinge multiple Rhabdomyoma an der Herzmuskelwand und der zweite Zwilling auch noch einen weitoffenstehenden *ductus arteriosus*. Die anderen Organe waren o. B. Wie gewöhnlich wurde das Rhabdomyom *intra vitam* nicht diagnostiziert, doch sollte man bei jedem Neugeborenen mit Herzsymptomen Verdacht darauf schöpfen. Dieser in der Literatur bisher erste Fall von *Rhabdomyom cordis* in beiden Paarlingen dürfte einen wesentlichen Beitrag zur Kenntnis der Pathogenie dieser seltenen, so umstrittenen Herkläsion darstellen.