



Twin Reversed Arterial Perfusion Syndrome

W. Malinowski¹, W. Wierzba²

¹Department of Obstetrics and Gynaecology, Kutno Hospital, Poland; ²Department of Obstetrics and Gynaecology, Plock Hospital, Poland

Abstract. Twin reversed arterial perfusion (TRAP) syndrome is a rare but severe complication of monozygotic monochorionic twin pregnancies. The outcome is invariably fatal for the abnormal twins and for 50-75% of the normal co-twins. The prenatal diagnosis of the TRAP always has to be presumed in a multiple pregnancy within which a twin pair grows whenever cardiac activity can not be proved echographically. We present discuss – based upon literature research – pathogenic mechanisms, pathologic-anatomic, echographic diagnosis and management of these high-risk pregnancies.

Key words: Twin reversed arterial perfusion (TRAP) syndrome, Ultrasound diagnosis

“Twin reversed arterial perfusion” syndrome (TRAP), chorangiopagus parasiticus (CAPP), foetus acardiacus, are rarely occurring complications of monozygotic monochorionic multiple pregnancies. All the cases described so far referred solely to this kind of pregnancies. It is a variation of “interfetal blood transfusion” syndrome chronic form, where beside normally developing twin there coexists another foetus, which grows despite the heart action absence. It is considered that the occurrence frequency of this syndrome amounts to 1:35000 of all the pregnancies and 1:100 of monozygotic twin ones [1, 13, 19]. It usually refers to the first pregnancy. The sex percentage of foetuses affected by “twin reversed arterial perfusion” syndrome published in the literature is contained from the state of balance [19, 37] to considerable female sex predominance (4:1) [5, 47]. This syndrome frequency grows with the multiplicity of pregnancy [37]. One of the reports describes that 21,5% of all the cases referred to a pair of monozygotic twins coming from triple pregnancy [47]. It may generally be assumed that this syndrome occurs three times more frequently in monozygotic triple pregnancies than in twin pregnancies [19]. Also higher percentage of “twin reversed arterial perfusion” syndrome occurred more in monochorionic monoamniotic twin pregnancies (up to 40% of cases) than in monochorionic diamniotic ones [19, 47]. So far it is unexplained the frequent

co-occurrence with the amniotic bands syndrome and high AFP level [32]. The first descriptions of this anomaly date back to the 16th century [31]. At first the origin of such fetuses was attributed to the extraterrestrial space or coming from still undiscovered lands [cit. after 48]. As far back as the 18th century they were considered to be the effect of the pregnant's "staring" at e. g. guillotine. The first attempts of scientific explanation of this complication aetiology date back to the beginning of the 19th century. In 1836, through injection of vessels in placenta, the existence of vascular anastomoses between acardius and normally developing cotwin [cit. after 35] was shown. A few years later Hempel (in 1850) showed that as a result of vascular connections presence in placental chorionic plate, in acardius it comes to the reversion of blood circulation direction in umbilical and intrafetal vessels [48]. Over 400 descriptions dealing with this developmental anomaly appeared in the world literature up till now.

At first it was attempted to base it on the evaluation of abnormal fetuses' macroscopic structure. Though there are many similarities among them, so far we lack a description of two identical cases. Hence, nosology based only on morphological structure of these fetuses naturally had to become very complex, especially when they started to include in it the traits obtained from radiological and postmortem examination [4, 5]. It resulted in the isolation of 12 classes of this anomaly and at the same time some of them have even a few different names each [37, 42] (Table 1).

The word "acardius" is common in this classification. Hence it is often used to define this whole group. Yet some of these abnormal fetuses have rudimentary heart structures and even a functioning heart [3, 5]. This is why the definition "foetus acardiacus" is inaccurate.

Another common trait of these fetuses is the presence of direct vascular anastomoses within placental chorionic plate or in initially single umbilical cord. Owing to the presence of these vascular anastomoses the abnormal twin – "acardius" – may partially grow, parasitizing on normally developing co-twin. Consequently, this anomaly may be considered as a certain form of not completely separated twins, in which the link conjugation on the level of blood vessels. Hence the definition of these fetuses chorangiopagus parasiticus (CAPP) (chorionic or vascular parasite), which term was used for the first time in 1906 by Schwalbe [22]. This name indicates only the place where the twins are united, without appealing to their morphological appearance, but as the one expressing the essence of the phenomenon in the simplest way and it is now the most frequently used to define this gestational anomaly.

The most significant trait, acknowledged by everyone as the basic condition of the syndrome occurrence, is the presence – in these abnormally developing fetuses – of the reversed blood circulation direction in umbilical and intrafetal vessels. This is why we acknowledged the term "twin reversed arterial perfusion" syndrome – TRAP [44, 46, 47] as the one that most precisely expresses the essence of this pathological state and we used it in the title of this study.

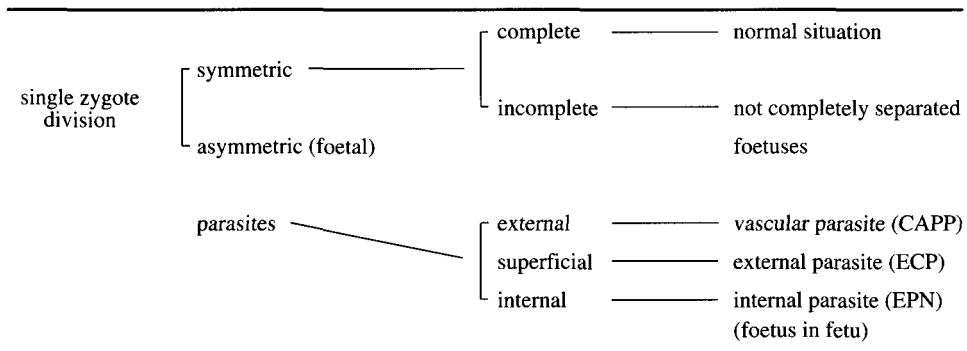
Recently, Baldwin [4, 5] – taking into account the final result of a single zygote division in the process of monozygotic twins formation – numbered these cases with the group of abnormal asymmetric division leading to the development of external foetal parasite (Table 2).

So far there is also no agreement as to the pathogenesis of "acardius" fetuses occurrence. The early reports suggested that the primary lesion of heart bud is the basic

Table 1 - "Twin reversed arterial perfusion syndrome". Classification of abnormally developing fetuses [37]

	Terminology	Percentage (in %)
Acardius holosomus (14,7%)	- holocranium	12,5
	- hemicranium	2,3
Acardius hemisomus (68%)	- acephalus	10,2
	- holocranium	3,4
	- hemicranium	6,8
	- acranium	35,2
	- athorax	6,8
	- arrhachis	3,4
Acardius amorphous (17%)	- acornus - incompletus	1,1
	- completus	1,1
Acardius amorphous (17%)	- externus	8,0
	- totalis	9,1

Table 2 - Variants of single zygote division in the process of monozygotic twins formation [4]



etiological factor [30, 40], whereas the further development of these fetuses is possible only owing to the existence of direct vascular anastomoses with the "pumping" co-twin ("donor"), supporting their circulation. It was also suggested that the key factor in this syndrome formation may be the presence of bivascular umbilical cord [24] or the hypoplasia of one of its arteries [21]. So far, however, sufficient number of arguments has been gathered, arguments denying the rightness of these theories.

For not all foetal parasites of this type are completely devoid of heart structures [3, 5] and moreover a lot of them have normal 3-vascular umbilical cord [37, 47]. Consequently, it suggests that the presence of direct vascular connections between fetuses may have significant meaning in the syndrome formation.

According to Benirschke and Harper [6] the direct vascular, arterioarterial and venous-venous anastomoses are directly responsible for the syndrome pathogenesis. In the case of occurrence of pressure predominance in the circulation system of one of the foetuses it may come – through strange anastomoses – to the reversion of arterial perfusion direction in umbilical vessels and intrafetal of another one. In such cases blood will flow into the weaker foetus (“recipient”) through the umbilical artery and flow out through the vein. In consequence, it led to the arrest of cardiac activity and its secondary atrophy [20]. Hence the definition “foetus acardiacus”, suggesting its primary non-existence, is not precise enough. One should rather use the term “regressive heart syndrome”. The changes taking place in foetuses at the moment of the reversion of arterial perfusion and a few weeks later were presented in the schematic form in figures 1 and 2 [15].

The newest views concerning the “twin reversed arterial perfusion” syndrome pathogenesis suggest that both the presence of developmental anomalies in one of the foetuses, enabling getting the other’s predominance over it, and the presence of direct vascular anastomoses, enabling the reversion of arterial perfusion direction, are equally important [47].

Consequently, according to van Allen et al. [47] the occurrence of multiple pregnancy anomaly of this kind demands compliance with two important conditions. Firstly: there must arise a close neighbourhood of embryonic blood vessel buds within the single placental disk (monochorionic pregnancy), which enables their direct connection in the period of placental angiogenesis (18th-21st day from fertilisation). Secondly: there must be present factors responsible for development inhibition of one of the embryos, which enables the normally developing foetus to reverse arterial perfusion direction, and then supporting of circulation in the one of co-twins with the arrested cardiac activity.

The triad of factors predisposing to the syndrome occurrence:

1. multiple monozygotic monochorionic pregnancy;
2. presence of vascular anastomoses between foetuses;
3. primarily asymmetric development of foetuses.

The causes of asymmetric intrauterine development of monozygotic twins may be sought in heterokaryocytic chromosomal anomalies [39], in formation of one of the twins as a result of I polar body twinning [8] and also in the presence – in one of them – of bivascular umbilical cord [21, 24].

Normal perfusion direction, its size and qualitative blood composition are the factors extremely essential for the development of each foetus. Consequently, the appearance of vascular connections between foetuses and the change of arterial perfusion direction become the cause of serious developmental complications in one, and sometimes in both twins simultaneously. In the case of “twin reversed arterial perfusion” syndrome appearance, the “recipient” twin receives from its stronger “donor” co-twin – through arterioarterial anastomoses – blood already partially devoid of oxygen (“used”) [25]. Just that deoxygenated blood, flowing in the reverse direction, is to be responsible for the arrest of cardiac activity and also for the resorption and reduction of already primarily formed tissues. Besides, such perfusion direction causes unequal body development of this foetus. The caudal part, because of its better perfusion, forms relatively normally,

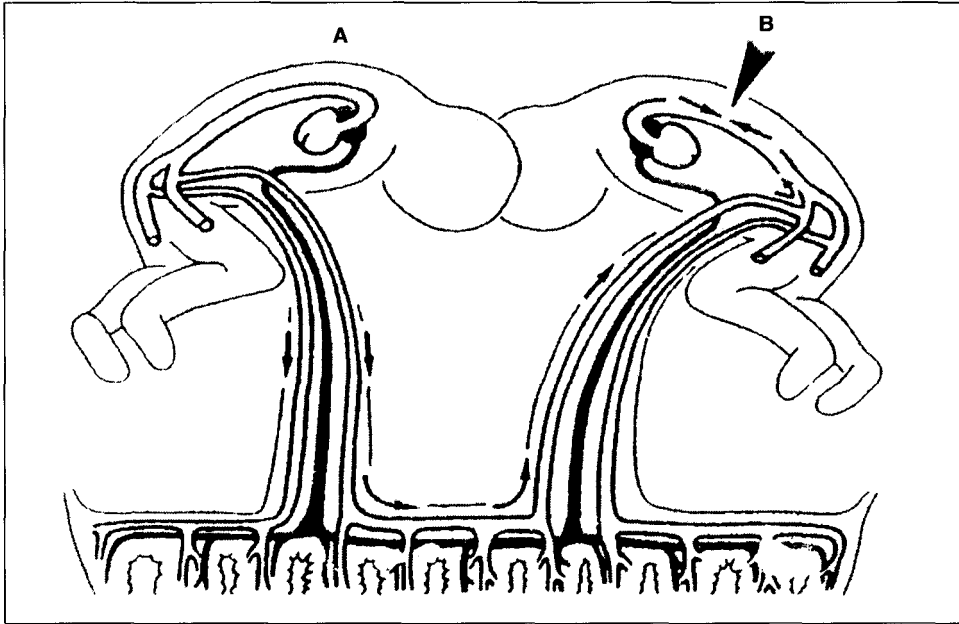


Fig. 1 - "Twin reversed arterial perfusion" syndrome. Situation at the moment of reversion of arterial perfusion direction [15].

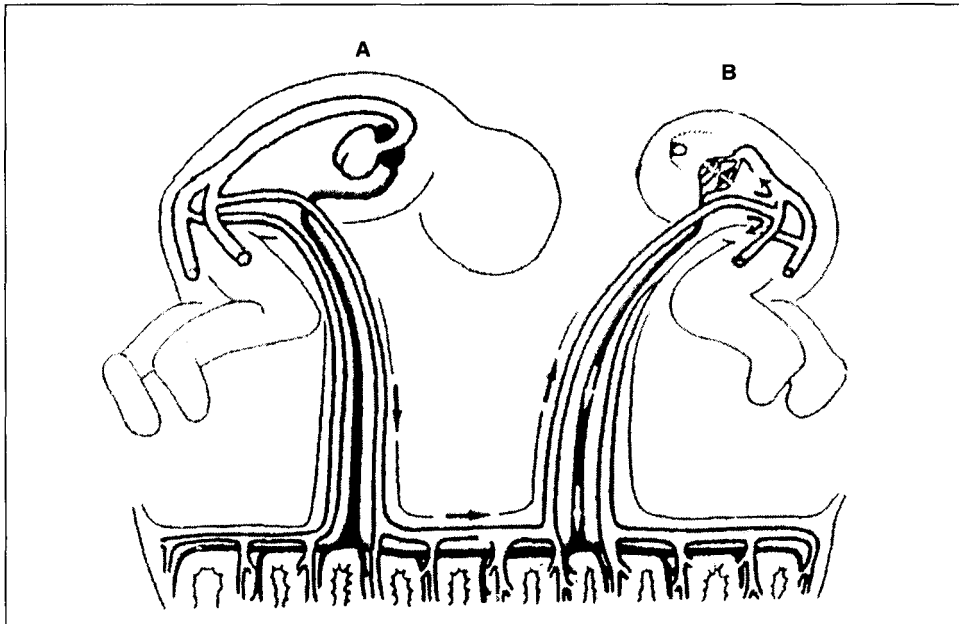


Fig. 2 - "Twin reversed arterial perfusion" syndrome. Situation a week later [15].

whereas the cephalad part usually has the form of a shapeless, spherical mass [20]. In the pathogenesis of body abnormal development of this foetus also other factors must be taken into consideration, as e.g. thrombus or embolism formation in chest and upper part of abdominal cavity vessels, with subsequent tissue resorption in these areas [49].

As we have earlier mentioned, no two identical (as regards morphological structure) foetal parasites coming from this syndrome have been described in literature so far. However, there are to be found certain recurrent traits. In most of the abnormally developed foetuses one finds body oedema of varied degree, relatively well developed lower limbs and abdominal organs and also partially shaped trunk. The upper part of the body usually forms a spherical, swollen mass which may sometimes have rudimentary upper limbs and certain elements resembling bony face structures. In the predominant number of cases there are no anatomical heart structures. However, sometimes one finds its rudimentary form. Also, there is usually no brain, although sometimes it exists in an underdeveloped form. Spinal cord is usually present, but with the underdevelopment of its upper part. Umbilical cord is most frequently attached to the trunk. Radiologically, osseous system of lower limbs and pelvis of the foetus is in some measure complete, vertebral column and ribs exist only in fragmentary form, whereas there are no upper limbs and no skull [5]. Generally it may be assumed that in foetuses relatively well formed, the lower part of the body below diaphragm is comparatively pretty well developed. In the case of more amorphous foetuses they only take the shape of ovoid mass of varied sizes, with deformed rudimentary lower limbs and no perineum development. Umbilical cord is then attached to the upper part of the body, near a skin flap resembling the head of the foetus [5]. Foetuses presenting deformed heart, upper limbs and bony face structures [3, 12, 49] were also described. In the cases when the foetus was in a separate amniotic sac (monochorionic diamniotic pregnancy) and it had a functioning renal tissue, hydramnion was frequently observed in its surroundings [39]. If there was no renal tissue or it was not functioning, oligohydramnios and amnion nodosum were observed [20]. In the literature there is also a description of the triple pregnancy in which two not completely separated "acardius" foetuses were growing owing to vascular anastomoses with the normally developing third foetus [1].

Genetic examinations performed in twins with "reversed arterial perfusion" syndrome brought differentiated results. In the predominant number of cases the karyotype anomalies were found only on the side of the abnormal foetus [8, 10, 28, 39, 47, 49]. In about 10% identical cytogenetic anomalies were observed in both foetuses simultaneously [28]. Still in other cases no chromosomal errors were found in any of the twins [6, 20].

Birth weight of the foetuses with abnormal arterial perfusion direction may amount from less than twenty to several thousand grams (from 16 to 6260 g.) and does not always depend on the impairment degree [47]. Their weight may therefore be smaller, the same and even bigger than the weight of the normal co-twin. In most pairs, however, the "donor" twin had a higher birth weight than its foetal "parasite" [3, 6, 10, 18, 20, 22, 24, 31, 35, 37, 39, 40, 44, 46, 49]. Therefore a question arises what the observed differences in body masses and in anatomical structure of "parasitizing" foetuses depend on. It seems that we have to do here with many factors. One of them may be a kind of primary developmental anomaly, determining the organisation degree of individual tissues and organs [32]. Another one may be the pregnancy period in which there came to

the reversion of arterial perfusion direction through the present vascular anastomoses. Still another one – the connecting vessels cross-section and the blood flow quantity resulting from this [5]. Certain significance may also be attributed to infarctions developing in hypoxemic, badly supplied with blood tissues. It is very probable, that not one isolated factor but several adding up and functioning simultaneously factors determine the differences in deformation degree and body masses.

As it has been earlier mentioned, the basic condition of “twin reversed arterial perfusion” syndrome occurrence is the presence of vascular anastomoses between foetuses. These anastomoses differ however from anastomoses commonly found in monochorionic twin pregnancies. They are exclusively arterioarterial and venous-venous anastomoses. These connections may come into being within vessels on the chorionic surface of placenta or umbilical vessels of abnormal foetus link directly with the vessels of another foetus in any place of its umbilical cord. Moreover, on the foetal “parasitic” side there are no villous vessels in placenta and thus no placental circulation [4, 5]. Only such kind of vascular anastomoses may lead to the complete reversion of arterial perfusion in one of the foetuses in the case of blood pressure predominance in the circulatory system of another one.

In abnormally developing foetuses one frequently observes two vascular umbilical cord, which quite recently was considered an integral part of the syndrome [24]. However, the more recent experiments have shown that 25% [37] to 57% [47] of these foetuses have a normal, 3-vascular umbilical cord. The literature describes also cases of two vascular umbilical cords existing in both foetuses simultaneously [5].

The host function which normally developing foetus fulfils towards the parasitizing co-twin, securing the blood circulation for it, is not without significance for its further intrauterine development. Perinatal mortality of these “pump twins” (“donors”) reaches 70% and is mainly caused by circulatory system insufficiency and prematurity [37, 47]. The necessity of blood circulation maintenance in vascular system of the foetal “parasite” and in its own one causes the excessive heart load. Moreover, through vascular anastomoses this foetus gets back part of the blood already doubly “used”, and so deoxidized to a high degree. In consequence it causes the decrease of minute heart volume leading to congestive heart failure with oedemas. Thus in the “donor” foetus are frequently observed: enlargement of the heart dimensions (even three times than it should be expected in the given gestational age), right ventricle hypertrophy, hepatosplenomegaly and non-immunological oedema [5]. Hypoproteinemia – besides the decrease of ejection volume – may also be the cause of the foetus oedema. It is caused by the disturbed synthesis of proteins resulting from impairment of liver function [16, 47]. In these foetuses it may also come to intrauterine growth retardation [5].

In the predominant number of cases in normally developing foetuses no developmental anomalies were found [47]. However, in about 10% of them the presence of defects – usually identical as in the parasitizing foetus [38] – was observed. Moreover, in 87% polyhydramnion occurred in their surroundings.

In the case described by us [27], on account of giant polyhydramnion and also exponents of generalised oedema in normally developing foetus, the pregnancy was terminated in the 34th week of its duration. Two male foetuses were extracted. The “donor” twin, with the birth weight of 2000 g, with considerable hepatosplenomegaly, hypoproteinemia and anaemia, survived and developed normally. His parasitizing co-twin had

the body mass of 900 g. Abnormalities occurring in the parasitizing foetus are always lethal for it. So far no case of fetal survival in extrauterine environment has been described. The death risk during the perinatal period is also very high for most of normally developing co-twins. That is why the early diagnosis of “twin reversed arterial perfusion” syndrome has excessively essential significance for the improvement of prognosis. This early diagnosis allows to monitor the normal foetus’ well-being, possible introduction of intrauterine therapy and also termination of pregnancy in the most optimal period.

Until quite recently, this syndrome diagnosis could be made only after the completed delivery. With the introduction of ultrasonographic examinations into diagnostics its diagnosis became possible also in the prenatal period, even as early as in the 12th week of pregnancy [26]. In the USG examination the diagnostic features for the foetus with reversed arterial perfusion direction are [9, 26, 27, 33, 45] (Fig. 3, 4):

1. no heart action with simultaneous enlargement of body sizes;
2. excess of echoes coming from soft tissues;
3. queer skeleton picture;
4. big cystoid structures within its body.

Observing the reversed arterial perfusion direction in umbilical vessels is sometimes possible in the case of using colour Doppler technique [7, 23]. Finding the presence of growing “foetus” despite non-visualization of heart action remains the basic ultrasonographic diagnostic symptom.

In the differential diagnosis one should take into account the coexistence with living foetus of [26]:

1. necrotic twin, undergoing regressive changes (“vanishing twin” syndrome);
2. submucous myoma indenting into the uterine cavity;
3. chorioangioma;
4. yolk sac;
5. foetal teratoma.

The final diagnosis of “twin reversed arterial perfusion” syndrome may be made after visualization – in serially performed ultrasonographic examinations – of the continuous, though slow growth of the observed “change”.

Another frequently occurring, easily perceptible in USG examination symptom is the presence of polyhydramnion and generalised oedema of the “donor” foetus, resulting from congestive heart failure. The sonographic oedema exponents are:

1. subcutaneous tissue thickening – over 5mm – most easily perceptible within the head (the so called “halo”);
2. presence of fluid in natural body cavities (peritoneum, pleura and pericardium).

Moreover, the enlargement visualisation of liver, spleen and heart is possible in ultrasonographic examinations. The blood flow examination by Doppler’s method may in turn give a lot of information about hemodynamic conditions prevailing in the organisms

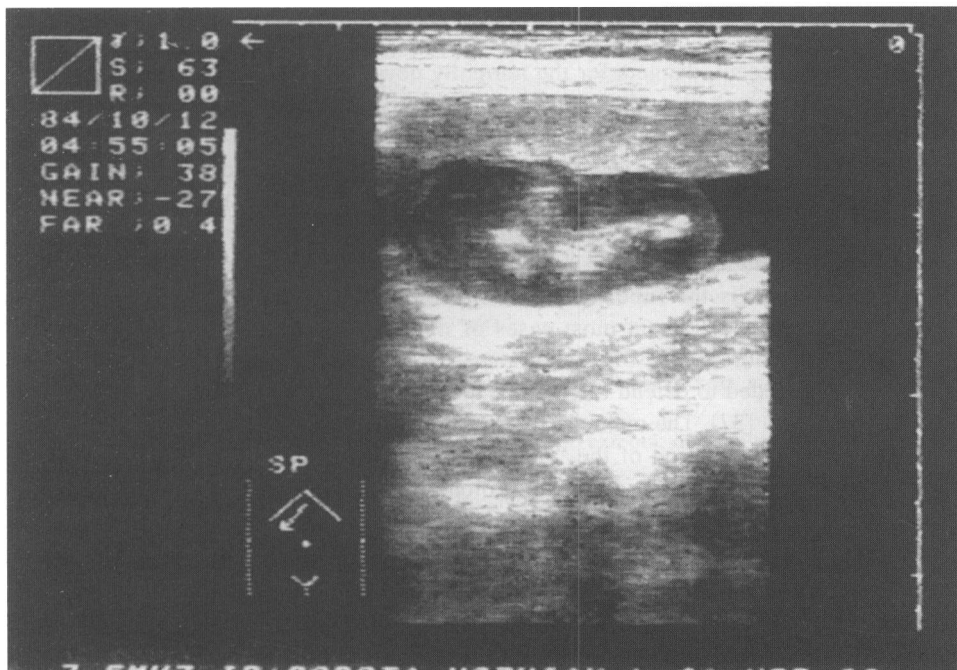
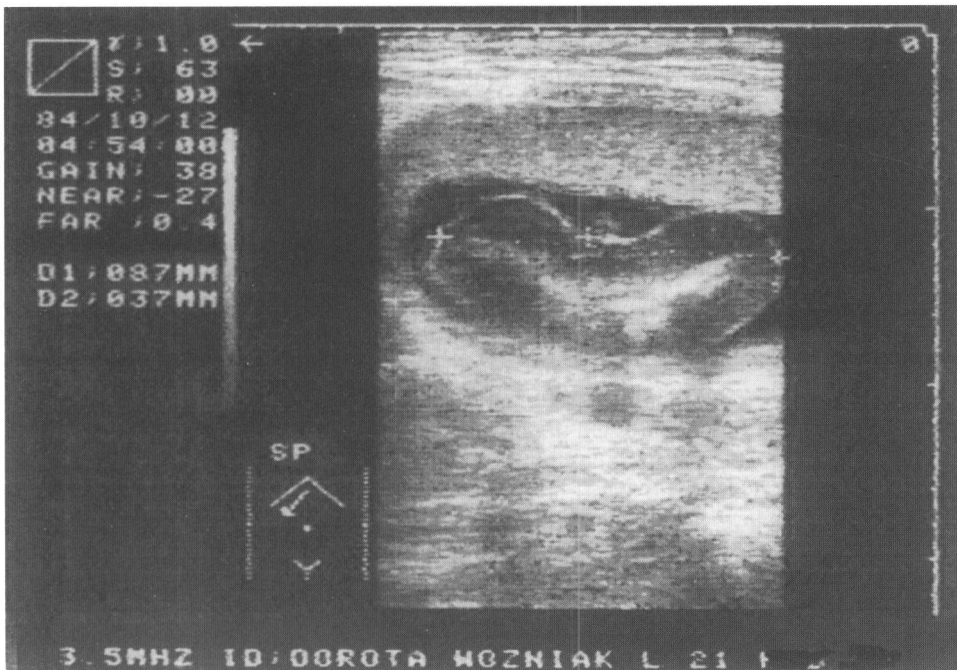


Fig. 3-4 - The foetus with reversed arterial perfusion.

of foetuses. It is acknowledged that S/D rate measurement in the “donor” twin’s umbilical artery corresponds with the sum of flow resistances in its placenta and in vascular system of the abnormal foetus, whereas in the “parasite” it corresponds with systemic resistance [41].

The heart load of normally developing “donor” twin depends first of all on the “recipient” cotwin’s sizes. The prognosis is particularly unfavourable when the body mass of the foetal “parasite” exceeds 70% of the normal foetus’ mass [29]. In such cases it often comes in the “donor” to congestive heart failure, non-immunological generalised oedema and consequently to its intrauterine death. The prognosis is additionally worsened by the fact of frequent coexistence of polyhydramnion and premature birth interdependent with it [29]. So the early determination of the fetal “parasite’s” body mass ratio to the one of normal foetus has essential significance, in the prediction of complications occurrence possibilities and in the introduction of proper prophylactic procedure. On the other hand, noting a low rate (< 25%) allows to assume an anticipating attitude, avoiding in this way undertaking the risky invasive procedure.

Due to the lack of typical anatomical structures, the ultrasonographic determination of presumable body mass of the abnormally developing foetus is extremely difficult. In such cases Moore et al. [29] propose to use the following formula;

$$\text{body mass in grams} = 1.2 L^2 - 1.7 L$$

where L stands for the longest dimension of foetus.

In “twin reversed arterial perfusion” syndrome therapeutic procedure is not always necessary. In the case when foetal “parasite” having small dimensions (< 25% of the host’s mass) is present, dangers for the normally developing co-twin are not great or do not exist at all. In such cases it is sufficient to adopt periodical ultrasonographic control and laser also cardiocographic one. Such pregnancies are usually carried to term without any harm to this foetus. Dangers for the “donor” twin may occur, if the abnormal foetus reaches bigger dimensions and particularly when the “parasite’s” weight exceeds 70% of the normal foetus’ mass. In such cases it is necessary to introduce early and appropriate therapeutic procedure.

Premature birth is the fundamental complication responsible for the high – about 70% – perinatal death rate in most cases of normally developing “donor” foetuses. Mean pregnancy duration in this syndrome is only about 29 weeks [29]. In the cases where they succeeded to extend the term to the 37th week the survival rate of these foetuses reached 80% [37]. The main causes of premature birth should be sought in circulatory system decompensation of the “donor” foetus and in polyhydramnion. Therefore, suitably early adopted therapy allows to prolong the pregnancy duration, to prevent circulatory failure and – in consequence – to lower the high perinatal death rate of foetuses and newborns.

Both non-invasive and invasive methods may be adopted in intragestational therapeutic procedure. In case of circulatory failure development in the normally developing foetus the attempts to beat the pregnant with digitalis preparations were undertaken [43]. Amniotic fluid excessive volume reduction was obtained through the use of indomethacin [2]. Prematurely aroused contractile activity of uterus were inhibited with the

use of tocolitics. In most cases such procedure did not greatly affect the lowering of perinatal death rate [29]. However, much better results were obtained when invasive methods were used. The mildest of them was recurrent amniocentesis, decompressing the excessive quantity of amniotic fluid [29]. In the cases of pregnancies lasting over 28 weeks, with confirmed maturity of the foetus' lungs, the use of elective pregnancy termination may be considered with the appearance of danger exponents in the so far normally developing foetus. Platt et al. [33] suggest tightening the umbilical cord of the foetal parasite by the surgical opening of uterine cavity or in foetoscope. The alternative, less invasive method is the administration of embolic material to umbilical artery of this foetus [34]. This method, however, is associated with considerable risk. In the case described by Baldwin [5], after administering the embolic material it came to its spreading also in the vascular system of the normal foetus, which caused the intrauterine death of both twins simultaneously. The most radical one among invasive methods is the surgical opening of uterine cavity combined with selective elimination of the abnormal foetus [1, 14, 36]. This operation was carried out only in monochorionic diamniotic pregnancies between the 16th and 26th week of their duration [11]. Owing to such procedure it was possible to delay the delivery by 4 to 16 weeks and obtain the survival of 4 out of 5 foetuses [11]. In the case terminated with failure, the death of foetus took place as a result of premature detachment of the placenta during the second hour after the performed operation.

The effectiveness degree of the therapeutic procedure depends on the early detection of "twin reversed arterial perfusion" syndrome and suitably frequent monitoring (USG, KTG) of the normal foetus. The weekly cycle, starting with the II trimester of pregnancy, seems to be optimal.

The prognosis regarding the course of the next pregnancies is very favourable, for as yet no case of repeated occurrence of the syndrome – even when these pregnancies were monochorionic – has been described.

REFERENCES

1. Amatuzio JC, Gorlin R (1981): Conjoined acardiac monsters. *Arch Pathol Lab Med* 105: 253-5.
2. Ash K, Harman CR, Gritter H (1990): TRAP sequence – successful outcome with indomethacin treatment. *Obstet Gynecol* 76: 960-2.
3. Auerback P, Wiglesworth FW (1978): Congenital absence of the heart: observation of a human funiculo pagus twinning with insertio funiculi furcata, fusion, forking and interpositio velamentos. *Tetralogy* 17: 143-50.
4. Baldwin VJ (1991): Pathology of Multiple Pregnancy. Textbook of Fetal and Perinatal Pathology. Scientific Publications, Boston 221.
5. Baldwin VJ (1994): Pathology of Multiple Pregnancy. New York, Springer-Verlag.
6. Benirschke K, Harper V (1977): The arcadiac anomaly. *Tetralogy* 15: 311-6.
7. Benson CB, Bieber FR, Genest DR, Doubilet PM (1989): Doppler demonstration of reversed umbilical blood flow in an acardiac twin. *J Clin Ultrasound* 17: 291-5.
8. Bieber FR, Nance WE, Morton CC et al. (1981): Genetic studies of an acardiac monster: evidence of polar body twinning in man. *Science* 213: 775-7.
9. Billah KL, Shah K, Odwin C (1981): Ultrasound diagnosis and management of acardius anencephalic twin pregnancy. *Med Ultrasound* 8: 108-9.

10. Deacon JS, Machin GA, Martin J et al (1980): Investigation of acephalus. *Am J Med Genet* 5: 85-9.
11. Fries MH, Goldberg JD, Golbus MS (1992): Treatment of acardiac-acephalus twin gestation by hysterotomy and selective delivery. *Obstet Gynecol* 79: 601-4.
12. Gewolb IH, Freedman RM, Kleinman CS, Hobbins JC (1983): Prenatal diagnosis of a human pseudo-acardiac anomaly. *Obstet Gynecol* 61: 657-62.
13. Gillim DL, Hendrics CH (1953): Holocardius: Review of the literature and case report. *Obstet Gynecol* 2: 647-53.
14. Ginsberg NA, Applebaum M, Rabin SA et al (1992): Term birth after midtrimester hysterotomy and selective delivery of an acardiac twin. *Am J Obstet Gynecol* 167: 33-7.
15. Hamada H, Okane M, Koresawa M et al (1992): Fetal therapy in utero by blockage of the umbilical blood flow of acardiac monster in twin pregnancy (English abstract). *Nippon-Sanaka-Fujinka-Gakkai-Zasshi* 41: 1803-9.
16. Harkavy KL, Scanlon JW (1978): Hydrops fetalis in a parabioc acardiac twin. *Am J Dis Child* 132: 638-9.
17. Heifetz SA (1984): Single umbilical artery. A statistical analysis of 237 autopsy cases and review of the literature. *Perspect Pediatr Pathol* 8: 345-78
18. Imai A, Hirose R, Kawabata I, Tamaya T (1991): Acardiac acephalic monster extremely larger than the co-twin. A case report. *Gynecol Obstet Invest* 32: 62-4.
19. James WH (1977): A note on the epidemiology of acardiac monsters. *Tetralogy* 16: 211-6.
20. Kaplan C, Benirschke K (1979): The acardiac anomaly. New case reports and current status. *Acta Gene Med Gemellol* 28: 51-9.
21. Keith L (1974): Holocardius. *J Reprod Med* 12: 82-5.
22. Ketchum J, Motyloff L (1957): Chorangiopagus parasiticus (Schwalbe). Report of a case of acardius acephalus and of a case of fetus amorphus. *Am J Obstet Gynecol* 73: 1349-54.
23. Kirkinen P, Herva R, Rasanen J et al (1989): Documentation of paradoxical umbilical blood supply of an acardiac twin in the antepartum state. *J Perinat Med* 17: 63-5.
24. Kyriazis A, Arean VM, Shanklin DR (1974): Placental radiographic analysis of parasitic acardiac fetus; partially acommon umbilical circulation. *J Reprod Med* 12: 74-81.
25. Leroy F (1976): Major fetal hazards in multiple pregnancy. *Acta Genet Med Gemellol* 25: 299-306.
26. Lindhal SA, Baldwin VJ, Wakeford J, Wittmann BK (1984): Early diagnosis of an acardiac acephalus twin by ultrasound. *Med Ultrasound* 8: 105-7.
27. Malinowski W, Lipiec W (1994): Ultrasound diagnosis of an acardiac twin. *Ultrason Pol* 4: 80-4.
28. Moore CA, Buehler BA, McManus BM et al (1987): Brief clinical report: acephalusacardia in twins with aneuploidy. *Am J Med Genet Suppl* 3: 139-43.
29. Moore TR, Gale S, Benirschke K (1990): Perinatal outcome of forty-nine pregnancies complicated acardiac twinning. *Am J Obstet Gynecol* 163: 907-12.
30. Nance WA (1981): Malformations unique to the twinning process. *Prog Clin Biol Res* 69: 123-33.
31. Napolitani FD, Schreiber I (1960): The acardiac monster. A review of the world literature and presentation of 2 cases. *Am J Obstet Gynecol* 80: 582-89.
32. Nerlich A, Wissner J, Draeger A et al (1990): Human acardiac anomaly: a report of three cases. *Eur J Obstet Gynecol Reprod Biol* 38: 79-85.
33. Platt LB, DeVore GR, Bieniarz A et al (1983): Antenatal diagnosis of acephalus acardia: A proposed management scheme. *Am J Obstet Gynecol* 146: 857-9.
34. Porreco RP, Barton SM, Haverkamp AD (1991): Occlusion of umbilical artery in acardiac acephalus twin. *Lancet* 1: 326-7.
35. Price B (1950): Primary biases in twin studies – a review of perinatal and natal difference producing factors in monozygotic pairs. *Am J Hum Genet* 2: 293-352.

36. Robie GF, Payne GG, Morgan MA (1989): Selective delivery of an acardiac acephalic twin. *N Engl J Med* 320: 512-3.
37. Sato T, Kaneko K, Konuma S et al (1984): Acardiac anomalies: review of 88 cases in Japan. *Asia-Oceana J Obstet Gynecol* 10: 45-52.
38. Schinzel AA, Smith DW, Miller JR (1979): Monozygotic twinning and structural defects. *J Pediatr* 95: 921-30.
39. Scott JM, Ferguson-Smith MA (1973): Heterokaryotypic monozygotic twins and the acardiac monster. *J Obstet Gynaecol Br Cwlth* 80: 52-9.
40. Severn CB, Holyoke EA (1973): Human acardiac anomalies. *Am J Obstet Gynecol* 116: 358-65.
41. Sherer DM, Armstrong B, Shah YG et al (1989): Prenatal sonographic diagnosis. Doppler velocimetric umbilical cord studies and subsequent management of an acardiac twin pregnancy. *Obstet Gynecol* 74: 472-5.
42. Simonds JP, Gowen GA (1925): Fetus amorphus (report of a case). *Surg Gynecol Obstet* 41: 171-9.
43. Simpson PC, Trudinger BJ, Walker A, Baird PJ (1983): The intrauterine treatment of fetal cardiac failure in a twin pregnancy with an acardiac acephalic monster. *Am J Obstet Gynecol* 147: 842-4.
44. Stephens TD (1984): Muscle abnormalities associated with the twin reverse- arterial-perfusion (TRAP) sequence (acardia). *Tetralogy* 30:311-8.
45. Stiller RJ, Romero R, Pace S, Hobbins JC (1989): Prenatal identification of twin reversed arterial perfusion syndrome in the first trimester. *Am J Obstet Gynecol* 160: 1194-6.
46. Van Allen MI (1981): Fetal vascular disruptions: mechanisms and some resulting birth defects. *Pediatr Ann* 10: 219-33.
47. Van Allen MI, Smith DW, Shepard TH (1983): Twin reversed arterial perfusion (TRAP) sequence: a study of 14 twin pregnancies with acardius. *Sem Perinat* 7: 285-93.
48. Warkany J (1971): *Congenital Malformations*. Chicago: Year Book Medical Publishers; 474.
49. Wolf HK, Mac Donald J, Bradford WB, Lahman JT (1991): Acardius anceps with evidence of intrauterine vascular occlusion: report of a case and discussion of pathogenesis. *Pediatr Pathol* 11: 143-52.

Correspondence: Dr Witold Malinowski, Department of Obstetrics and Gynecology, Kutno Hospital, 42 Kościuszki Street, 99-300 Kutno, Poland.