

An unusual presentation of small bowel intussusception

Samantha Dankoff, MDCM*[‡]; Pramod Puligandla, MD, MSc^{†§}; Alana Beres, BSc, MDCM[§]; Farhan Bhanji, MD, MSc^{††}

ABSTRACT

A previously healthy 2-year-old boy presented to the emergency department with a decreased level of consciousness. A physical examination was unremarkable except for miosis and atypical limb movements. The patient underwent an extensive workup, including the search for metabolic, infectious, neurologic, and toxicologic etiologies. An abdominal ultrasound was performed because the child continued to remain neurologically impaired with no cause identified on other investigations. The ultrasound revealed a persistent uncomplicated ileoileal intussusception. The patient was taken to the operating room for surgical reduction. The child recovered fully postoperatively. This case illustrates the rare presentation of intussusception encephalopathy, which can be a diagnostic dilemma, especially when none of the symptoms of intussusception are present. Endogenous opioid poisoning is hypothesized to be the cause of the miosis and may hint at the diagnosis and aid in early management.

RÉSUMÉ

Un petit garçon de deux ans, auparavant en bonne santé, a été conduit au service des urgences (SU) pour une altération de l'état de conscience. Il n'y avait rien à signaler à l'examen physique, à part un myosis et des mouvements anormaux des membres. Des examens approfondis ont été effectués, dont certains visaient la recherche de causes métaboliques, infectieuses, neurologiques ou toxiques. Une échographie abdominale a été réalisée pendant que l'enfant était toujours dans un état neurologique altéré, et ce, sans qu'aucune cause n'ait pu être décelée par d'autres examens. L'échographie a

montré une invagination iléo-iléale persistante, sans complications. L'enfant a été conduit à la salle d'opération pour une réduction de la malformation, puis s'est complètement rétabli après l'intervention. Voilà un bel exemple d'« encéphalopathie par invagination », qui peut poser un dilemme diagnostique, surtout en l'absence de tout symptôme d'invagination. On a supposé qu'un empoisonnement à des opioïdes endogènes était à l'origine du myosis, et cela a pu avoir contribué à la pose du diagnostic et à la prise en charge précoce de l'affection.

Keywords: Ileoileal Intussusception, Intussusception Encephalopathy, Altered Level of Consciousness, Miosis

INTRODUCTION

Intussusception is the most common cause of intestinal obstruction between 6 and 36 months of age. Eighty percent of those affected are in the first 2 years of life.¹ It is characterized by the telescoping of one segment of bowel (intussusceptum) into its neighbouring segment (intussusciptens), situated most commonly near the ileocecal valve (*ileocolic*). In 75% of cases, the invagination is idiopathic. In children less than age 3 months or older than 5 years, however, it more commonly originates from a pathologic lead point (e.g., Meckel diverticulum, polyp, hemangioma) or can be associated with conditions causing hypertrophy of Peyer patches (e.g., Henoch-Schönlein purpura, lymphoma, rotavirus infection). The characteristic symptoms include episodes of unremitting, colicky abdominal pain with drawing up of the knees, vomiting, and, in the later stages, currant jelly stools. The signs may include a tender abdomen with a sausage-shaped mass in the mid-abdomen. The classical triad of

From the *Departments of Pediatrics; †Pediatric Critical Care; ‡Emergency; and §Surgery, The Montreal Children's Hospital, McGill University Health Centre, Montreal, QC

Correspondence to: Samantha Dankoff, MDCM, Department of Pediatric Emergency, Montreal Children's Hospital, 2300 Tupper St., Montreal, QC H3H 1P3; Email: samantha.dankoff@mail.mcgill.ca

© Canadian Association of Emergency Physicians

CJEM 2015;17(3):318-321

DOI 10.1017/cem.2014.42



CJEM • JCMU

2015;17(3) 318

pain, abdominal mass, and currant jelly stools is seen in less than 15% of patients at the time of presentation.² Interestingly, lethargy has been described as a rare presenting symptom in a subset of patients.^{3,4,5} Prompt diagnosis and treatment are important, given the risk for bowel necrosis, peritonitis, and sepsis. Abdominal ultrasonography is the gold standard for investigating intussusception, with the “target sign” (i.e., bowel within bowel) being pathognomonic. Pneumatic or hydrostatic (barium or saline) enema under fluoroscopic or sonographic guidance can also be diagnostic and is the standard of care for the nonsurgical reduction of classical ileocolic intussusception. Emergency surgical reduction is necessary when radiologic attempts are unsuccessful, if the child is hemodynamically unstable, or if the child has evidence of peritonitis or intestinal perforation. Importantly, persistent intussusceptions involving only the small bowel are not amenable to radiologic reduction, in which case surgical reduction is necessary.

CASE REPORT

A previously well 2-year-old boy presented to the emergency department of a tertiary pediatric centre with a 4-hour history of altered mental status. He had been well throughout the day, but, shortly after being put to bed, he was found to have episodes of what the parents initially thought were nightmares with the child “screaming and thrashing in bed with his eyes closed, unresponsive and looking confused.” Between these episodes, he became increasingly lethargic. The parents did not relate any history of trauma, toxic exposures or ingestions, upper respiratory tract infection symptoms, fever, or gastrointestinal symptoms. They denied the presence of any opioids in the household. The boy’s past medical history was unremarkable (he took no medications and had no known allergies), and his immunizations were up to date.

At presentation to the hospital, his vital signs were as follows: blood pressure at 95/60 mm Hg, heart rate at 100 bpm, respiratory rate at 32 with a normal respiratory pattern, temperature of 35.9°C (96.6°F), and oxygen saturation at 96% in room air. A bedside glucose measurement was 5.4 mmol/L. He had a depressed level of consciousness, withdrawing only minimally to painful stimulation (Glasgow Coma Scale [GCS] 8/15: 2, 2, and 4 for eye, verbal, and motor response, respectively). Physical examination was unremarkable, except for reactive pinpoint pupils (1 mm). Given this child’s marked lethargy, an initial workup for possible

infectious, metabolic, and toxicologic etiologies was performed and consisted of a complete blood count, glucose, electrolytes, capillary blood gas, lactate, urinalysis, liver and renal function, as well as serum and urine toxicology screening. All of these tests were within normal limits. Head computed tomography (CT) scan was also normal. He was given one dose of ceftriaxone for meningitis coverage prior to head CT and was transferred to the pediatric intensive care unit (PICU) for further observation and management. Given persistent lethargy, a lumbar puncture was done. All analyses of the cerebrospinal fluid were normal (2 white blood cells/ μ L, 1 red blood cell/ μ L, protein 0.34 g/L, glucose 3.4 mmol/L). He was nevertheless continued on ceftriaxone, vancomycin, and acyclovir, pending the microbiology results for possible meningoencephalitis.

While in the PICU, his GCS remained 8/15, but he began having intermittent episodes of athetoid-like movements involving all four limbs lasting approximately 5–10 minutes (Figure 1). It was unclear whether these were seizures, so in the absence of an electroencephalography, the neurology consulting service recommended loading him with 20 mg/kg of phenytoin. Despite this, he continued to have these intermittent movement episodes while looking uncomfortable. Given that all investigations failed to explain the child’s abnormal level of consciousness, the diagnosis of intussusception was entertained, despite the absence of any obvious gastrointestinal symptoms.

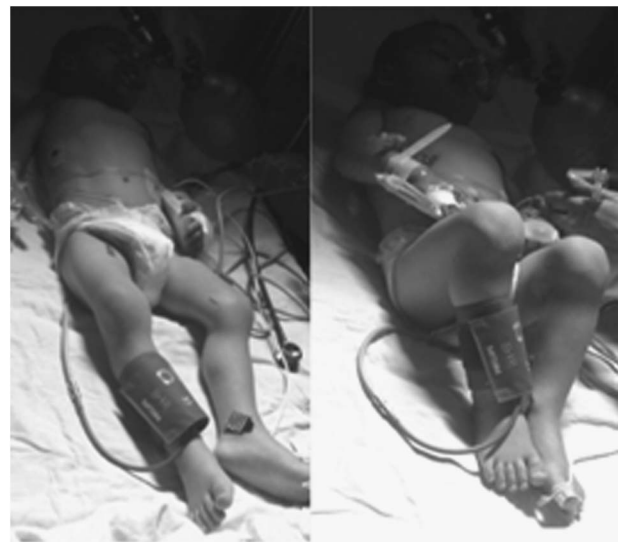

Figure 1. Episodes of atypical movements and discomfort (night) compared to baseline lethargy (left).

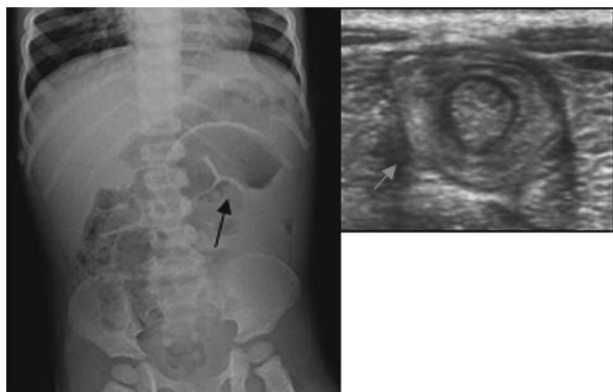


Figure 2. Abdominal radiography (left) showing possible bowel obstruction; abdominal ultrasound (right) showing “target sign” of bowel-within-bowel.

The abdominal radiographs were thought to be suggestive of a possible bowel obstruction, with a dilated loop in the left upper quadrant and a paucity of gas in the distal colon. However, the radiology report was essentially normal, showing “nonspecific bowel gas pattern without signs of obstruction or free air.” An initial bedside abdominal ultrasound demonstrated an ileoileal intussusception (Figure 2). Given that an intussusception confined to the small bowel frequently reduces spontaneously, an abdominal ultrasound was repeated an hour later. It showed persistent ileoileal intussusception, and thus the patient was brought to the operating room for emergency surgical reduction. This was performed laparoscopically. Intraoperatively, the small-bowel intussusception was confirmed with evidence of lymphoid hyperplasia but no bowel necrosis. The intussusception was easily reduced without the need for intestinal resection. Postoperatively, the patient became progressively more alert. He returned to his baseline neurologic state within 24 hours and experienced no further complications.

DISCUSSION

This case highlights a rare presentation of intussusception encephalopathy secondary to ileoileal intussusception, whereby a child presented with a depressed level of consciousness in the context of a negative toxicologic, metabolic, and structural workup for the most likely etiologies of lethargy in this age group. Table 1 provides a framework outlining a commonly used mnemonic TIPS from the VOWELS to determine the cause of a depressed level of consciousness in a child. The pathophysiology of this presentation is not fully understood. In 1979, Singer⁶ described two cases of

Table 1. Altered level of consciousness TIPS-AEIIOU

Trauma
Intussusception
Psychological
Shock/stroke/syncope
Alcohol
Epilepsy
Infection/insulin
Overdose
Uremia

infants with altered consciousness as a manifestation of intussusception and posited that it could be due to the systemic action of toxic metabolites released from ischemic gut that depressed the central nervous system (CNS). This is less likely, given the pathophysiology in our patient and others like him in whom the diagnosis of intussusception was made early in the disease process and where there was no evidence of ischemic bowel. In 1987, Tenenbein and Wiseman⁷ described a child presenting with coma and miosis, both responding temporarily to naloxone administration, leading to a hypothesis of massive endorphin secretion during the painful paroxysms. However, a subsequent study demonstrated no difference in plasma β -endorphin levels in patients admitted with intussusception compared to the controls.⁸ It remains plausible that the encephalopathy could have been due to another endogenous opioid or that the CNS may be more susceptible to circulating levels of endogenous endorphins in a subset of infants.⁹ Although a trial of naloxone could have been administered in this case, given the absence of respiratory depression and the absence of narcotics in the household, it was not attempted in this child. In conclusion, this case underlines the importance of including intussusception as part of the differential diagnosis of infants presenting with unexplained altered sensorium even when there are no gastrointestinal signs and symptoms. The finding of miosis, without signs of toxic ingestion, may serve as an important clue to the etiology and aid in prompt treatment.

REFERENCES

1. Kitagawa S, Miqdady M. Intussusception in children. *UpToDate*, July 2012.
2. Simon RA, Hugh TJ, Curtin AM. Childhood intussusception in a regional hospital. *Aust N Z J Surg* 1994; 699-702.
3. Heldrich F. Lethargy as a presenting symptom in patients with intussusception. *Clin Paediatr* 1986;363-5.

4. Hickey R, Sodhi SK, Johnson WR. Two children with lethargy and intussusception. *Ann Emerg Med* 1990; 390-2.
5. Martin d'Escrienne M, Velin P, Filippigh P, et al. Forme léthargique d'invagination intestinale aiguë du nourrisson. *Arch Pédiatr* 1996;3;44-6.
6. Singer J. Altered consciousness as an early manifestation of intussusception. *Paediatrics* 1979;93-5.
7. Tenenbein M, Wiseman NE. Early coma in intussusception: endogenous opioid induced? *Pediatr Emerg Care* 1987;22-23.
8. Ros SP, Reynolds SL, Bhisitkul DM, et al. Plasma beta-endorphin levels and childhood intussusception. *J Emerg Med* 1994;767-9.
9. Goetting MG, Tiznado-Garcia E, Bakdash TF, et al. Intussusception encephalopathy: an underrecognized cause of coma in children. *Pediatr Neurol* 1990;6;419-21.