

# Generalized Nonconvulsive Status Epilepticus with Reactive Alpha Rhythm

*Evelyne Côté-Mantha, Martin Savard*

Can J Neurol Sci. 2011; 38: 345-346

Bihemispheric ictal activity has been reported to unequally involve certain thalamocortical pathways<sup>1</sup>. This phenomenon is seen in absence epilepsy, in which certain brain areas do not seem to be as involved as others<sup>1</sup>, as proven by the lack of motor manifestation. However, to our knowledge, no one has ever reported persistent physiological electroencephalogram (EEG) findings supporting this concept.

## CASE REPORT

A 48-year-old man with mild mental retardation was brought to the emergency department having had a seizure. He was taking lamotrigine, carbamazepine and phenytoin for generalized tonic-clonic seizures and absence-like spells since childhood. Previous EEG showed normal background (Figure A) with widespread photoparoxysmal activity, which suggested the diagnosis of probable generalized photosensitive epilepsy. Over the past decade, he had been assessed many times in the emergency room for episodes of confusion and bradyphrenia. No formal diagnosis had been made and the patient was then discharged once back to his baseline.

The day of admission, he had a generalized tonic-clonic seizure. In hospital, he was confused and disoriented. He could obey simple commands, but his reactions were slow. The neurological exam was otherwise within normal limits. A cerebral computed tomography scan and blood work were normal. As there was no improvement of the confusion three hours after his arrival, an EEG was performed. It showed bisynchronous, 2 Hz generalized spike-waves and polyspike-waves, maximal in the frontal regions. A remarkable feature was an alpha rhythm in bilateral posterior regions, which was reactive to eye opening and closure. This reactive alpha rhythm was seen concomitantly with the generalized epileptiform activity, for the whole duration of the 20 minute recording. (Figure B and C)

Following the recording, the patient had a two minute generalized tonic-clonic seizure treated with 2 mg of intravenous lorazepam. Afterward, he was drowsy, was not obeying commands and his verbal answers were incomprehensible. When stimulated, the patient became transiently agitated but there was no clinical sign of ongoing seizure. His level of consciousness gradually improved. A second EEG done 90 minutes after the seizure showed diffuse delta and theta activity prominent in the anterior regions, without epileptiform activity, and with partially reactive alpha activity in the posterior regions. (Figure D)

The following day, the patient was alert, oriented and his neurological exam was within normal. He was discharged home two days after admission.

## DISCUSSION

The source of alpha rhythm is still unproven. While some authors believe that it is generated by the thalamus<sup>2</sup>, others suggest that it might arise from the neocortex<sup>3</sup>.

In the literature, the only described alpha activity during a generalized status epilepticus is a widespread, unreactive one and considered as a part of the pathological process<sup>4</sup>, which is different from the one seen in our patient. Moreover, reactive alpha rhythm may be a pseudoseizure sign, which is not the case here since a continuous generalized rhythmic epileptiform activity, incompatible with pseudoseizure, was seen concurrently.

The clinical presentation (confusion and bradyphrenia but ability to follow commands, occurrence of tonic-clonic seizures) and the EEG (2 Hz continuous generalized spike-wave or polyspike-wave activity) of our patient are very similar to a rare generalized form of epilepsy, the absence status<sup>5</sup>.

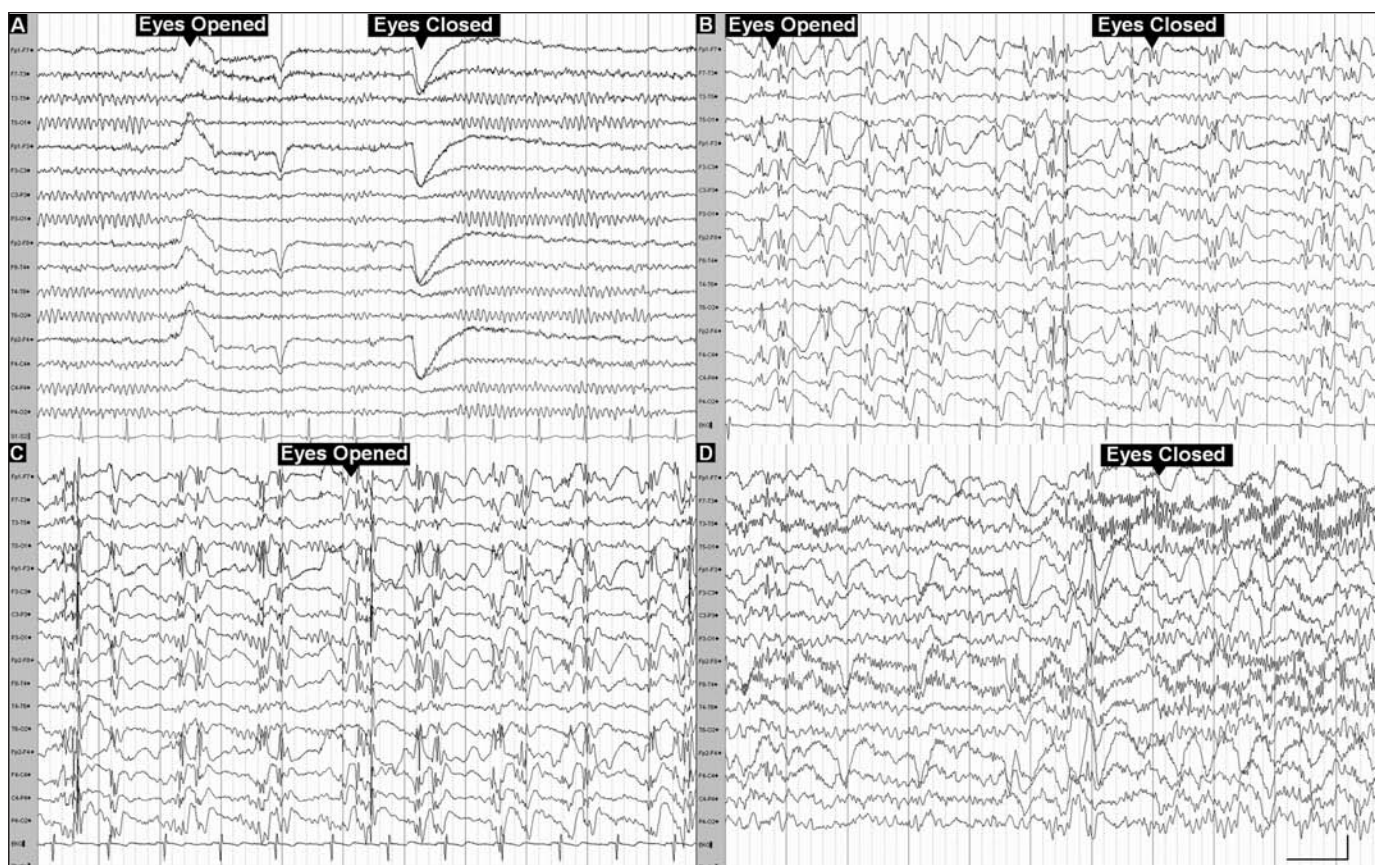
It is well known that both thalamus and cortex are involved in typical spike-wave discharges, even if the debate continues about their relative importance<sup>1</sup>. It is hypothesized that, in some forms of generalized epilepsy, spike and wave discharges intensely involve selective thalamocortical networks while sparing others<sup>1</sup>. Absences are an example of such phenomenon. Although a generalized form of epilepsy, phase oppositions in the anterior channels localize the main activity in the prefrontal region. This could explain the lack of organized motor behaviour, apart from automatisms, in this type of epilepsy.

In our patient, as the frontal regions were maximally involved in the epileptic process, we can suppose that anterior thalamocortical networks were more implicated than the posterior ones. It suggests certain "independence" of the occipital cortex from the pathological process involving the

From the Hôpital de l'Enfant-Jésus du CHA, Québec, Québec, Canada.

RECEIVED AUGUST 16, 2010. FINAL REVISIONS SUBMITTED OCTOBER 13, 2010.

Correspondence to: Martin Savard, Hôpital de l'Enfant-Jésus du CHA, 1401 18ième rue, Québec, Québec, G1J 1Z4, Canada.



**Figure:** A. Interictal EEG recording with longitudinal bipolar montage, high pass filter 0.500 Hz, low pass filter 70 Hz, showing reactive alpha rhythm. B and C. Electroencephalogram recordings with longitudinal bipolar montage, high pass filter 0.500 Hz, low pass filter 70 Hz, showing generalized 2 Hz spike-waves and polyspike-waves, maximal in the anterior regions, consistent with generalized nonconvulsive status epilepticus. In the posterior leads, an alpha rhythm reactive to eye opening and closure is seen. D. Postictal EEG recording with longitudinal bipolar montage, high pass filter 0.500 Hz, low pass filter 30 Hz, showing diffuse delta and theta activity prominent in the anterior regions, without epileptiform activity, and with partially reactive alpha activity in the posterior regions.

thalamus, where we could see normal, physiological alpha activity. Here, we suppose that this independence allowed the posterior cortex to generate a normal, physiologic alpha activity.

Our case brings electrophysiological support to these hypothesis by demonstrating bihemispheric, synchronous, spike-wave discharges, more prominent in the anterior regions and contemporaneous physiological reactive alpha activity in the posterior regions. This observation suggests that the generation of the alpha rhythm might not depend exclusively on the thalamus.

In conclusion, we showed that generalized nonconvulsive status epilepticus may be compatible with simultaneous physiological reactive alpha activity. We thus conclude that certain thalamocortical pathways can be unequally involved in generalized nonconvulsive status epilepticus, allowing normal physiological activity, as the alpha rhythm, to persist. Therefore, this suggests that the alpha rhythm is probably not exclusively under the influence of those networks but rather generated by the cortex.

## REFERENCES

1. Blumenfeld H. Cellular and network mechanisms of spike-wave seizures. *Epilepsia*. 2005;46 Suppl 9:21-33.
2. Schreckenberger M, Lange-Asschenfeld C, Lochmann M, et al. The thalamus as the generator and modulator of EEG alpha rhythm: a combined PET/EEG study with lorazepam challenge in humans. *Neuroimage*. 2004;22:637-44.
3. Nunez P, Wingeier B, Silberstein R. Spatial-temporal structures of human alpha rhythms: theory, microcurrent sources, multiscale measurements, and global binding of local networks. *Hum Brain Mapp*. 2001;13:125-64.
4. Bauer J, Neumann M, Kölmel HW, Elger CE. Ictal generalized rhythmic alpha activity during non-convulsive status epilepticus. *Eur J Neurol*. 2000;7:735-40.
5. Genton P, Ferlazzo E, Thomas P. Absence status epilepsy: delineation of a distinct idiopathic generalized epilepsy syndrome. *Epilepsia*. 2008;49:642-9.