

Letter to the Editor: New Observation

Antibody-Negative Stiff Person Syndrome Non-Responder After Hematopoietic Cell Transplant

Tefani Perera¹ , Ilja Tchajkov² and Jan Storek³

¹Department of Clinical Neurosciences, University of Calgary, Calgary, AB, Canada, ²Department of Radiology, Niagara Health St. Catharines Site, St. Catharines, ON, Canada and ³Department of Hematology, University of Calgary, Calgary, AB, Canada

Keywords: Stiff person syndrome; hematopoietic cell transplantation

Stiff person syndrome (SPS) is an uncommon immune-mediated disease characterized by muscle stiffness, spasms, and rigidity. Approximately 65% of cases are antibody-positive with multiple reported antibody targets, including glutamic acid decarboxylase (GAD65), the $\alpha 1$ -subunit of the glycine receptor, amphiphysin, gephyrin, dipeptidyl peptidase-like protein 6 (DPPX), and the γ -aminobutyric acid-A receptor (GABA_AR).¹ SPS can be refractory to conventional immunosuppression. Autologous hematopoietic cell transplantation (HCT) has been reported as a treatment option in refractory autoantibody-positive cases.^{2–4} Herein we describe a case of antibody-negative SPS with no improvement after HCT.

A middle-aged man with type 1 diabetes presented in March 2018 with constant stiffness in his low back. Over the next year, the stiffness spread up his trunk and into his neck, legs, and arms with superimposed painful spasms that were triggered spontaneously and at times by unexpected motion such as bumps on the road while driving. Symptoms progressed to the point where he was unable to work. Initial testing included normal magnetic resonance imaging of the whole spine and negative testing for glutamic acid decarboxylase 65 (GAD65; radioimmunoassay), anti-gamma-aminobutyric acid (GABA_AR; cell-based assay), amphiphysin (cell-based assay), and DPPX (immunofluorescence assay) through Mayo Clinic Laboratories in both serum and cerebrospinal fluid (CSF). CSF studies showed elevated protein at 0.67 g/l (normal \leq 0.4 g/l) but were otherwise normal including absent oligoclonal bands. Anti-nuclear antibodies were positive in a speckled pattern at a high titer (1:640). Diazepam had initially been helpful, but its use was limited by side effects; trials of baclofen, tizanidine, and dantrolene showed minimal benefit.

He continued to be followed in the neuromuscular clinic. Exam in December 2019 was remarkable for increased paraspinal muscle tone and axial and lower limb rigidity without exaggerated startle response or hyperlordosis. He had a characteristic stiff-legged “tin man” gait. Nerve conduction studies and needle electromyography (EMG) revealed continuous paraspinal muscle activity as well as agonist and antagonist co-contraction with patellar reflex. Repeat GAD65 testing done locally (sandwich immunoassay, DynaLife Labs) was initially borderline positive in the serum (5.1 IU/ml,

normal \leq 5.0 IU/ml) but was negative when repeated. Serum anti-glycine antibodies were negative (cell-based assay, Oxford Neuroimmunology Laboratory). Whole-body positron emission tomography (PET) was negative for malignancy but did show a significant increase in metabolic activity in axial/limb muscles (Fig. 1), as previously described in SPS.⁵

His symptoms continued to worsen despite a two-month trial of intravenous immunoglobulin (2 g/kg induction and monthly 1 g/kg maintenance). Rituximab (1000mg for 2 doses, 2 weeks apart) was subsequently given without improvement in symptoms. A course of pulsed high-dose oral prednisone (1250 mg) for 5 days

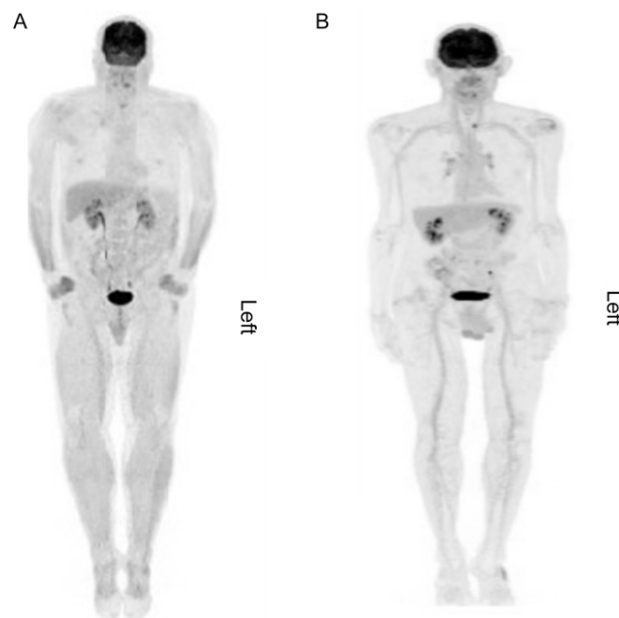


Figure 1. Whole-body ¹⁸F-FDG PET scan showing generalized increased uptake within the musculature, most evident within the forearms, thighs, and calves (a.) with a normal scan for comparison (b.).

Corresponding author: T. Perera; Email: tefani.perera@ucalgary.ca

Cite this article: Perera T, Tchajkov I, and Storek J. Antibody-Negative Stiff Person Syndrome Non-Responder After Hematopoietic Cell Transplant. *The Canadian Journal of Neurological Sciences*, <https://doi.org/10.1017/cjn.2023.296>

© The Author(s), 2023. Published by Cambridge University Press on behalf of Canadian Neurological Sciences Federation. This is an Open Access article, distributed under the terms of the Creative Commons Attribution licence (<http://creativecommons.org/licenses/by/4.0/>), which permits unrestricted re-use, distribution and reproduction, provided the original article is properly cited.

was followed by maintenance daily prednisone (1 mg/kg), which was discontinued due to side effects. He then continued weekly pulsed oral prednisone (1250mg) for 1 month then biweekly for 2 months with only a slight reduction of stiffness and spasms. Plasmapheresis (5 exchanges over 10 days) was also ineffective. Multiple symptomatic therapies including levetiracetam, gabapentin, pregabalin, vigabatrin, and valproic acid had minimal benefit.

Due to refractory severe symptoms, we proceeded with autologous HCT in September 2020 using the Ottawa protocol for multiple sclerosis (using high doses of busulfan and cyclophosphamide and rabbit antithymocyte globulin followed by infusion of autologous CD34⁺ cells).⁶ Peri-transplant complications included pulmonary embolism, neutropenic fever, presumed proctitis, and cytomegalovirus reactivation. With therapy, these complications resolved.

Monthly neurological reassessment occurred for 13 months after HCT. He reported ongoing progression of stiffness/spasms and has developed progressive neuropathic pain in his legs responsive to diazepam as well as a new diagnosis of bilateral adhesive capsulitis. His exam continued to demonstrate axial and lower extremity rigidity and a new lumbar hyperlordosis. Sensory exam has remained normal. Repeat electrophysiology demonstrated continued agonist-antagonist co-contraction.

This report illustrates a case of SPS refractory to HCT. It is the first antibody-negative patient to undergo HCT in the literature. Despite the lack of antibody positivity, we felt confident in the diagnosis of SPS given the clear findings on exam, EMG, and PET scan. Nonetheless, diagnosis of antibody-negative SPS remains challenging given that the specificity of both clinical findings and para-clinical tests such as EMG and PET are unknown.⁷

More data are needed to determine whether autoantibody-negative SPS is a contraindication to HCT. A limitation of this report is the lack of pretransplant antibody testing for gephyrin.

A recent clinical trial of HCT in GAD65-positive SPS suggested lack of efficacy in certain sub-populations of patients including those with negative GAD65 antibodies in CSF.⁶ There are however

other clinical characteristics that may predict poor response such as rigidity on examination, and EMG-documented simultaneous contraction of agonist-antagonist limb muscles, both of which were seen in this case. While some patients with SPS clearly improve with HCT, this case demonstrates that HCT may not be effective for all forms of refractory SPS.

Acknowledgements. None.

Statement of authorship. Case written and reviewed by TP, IT, and JS. Figures created by IT and JS.

Funding. None.

Competing interests. None.

References

- Martinez-Hernandez E, Ariño H, McKeon A, et al. Clinical and immunologic investigations in patients with stiff-person spectrum disorder. *JAMA Neurol.* 2016;73:714. DOI: [10.1001/jamaneurol.2016.0133](https://doi.org/10.1001/jamaneurol.2016.0133).
- Burt RK, Balabanov R, Han X, et al. Autologous hematopoietic stem cell transplantation for stiff-person spectrum disorder: a clinical trial. *Neurology.* 2021;96:e817–e830. DOI: [10.1212/WNL.0000000000001338](https://doi.org/10.1212/WNL.0000000000001338).
- Sanders S, Bredeson C, Pringle CE, et al. Autologous stem cell transplantation for stiff person syndrome: two cases from the ottawa blood and marrow transplant program. *JAMA Neurol.* 2014;71:1296. DOI: [10.1001/jamaneurol.2014.1297](https://doi.org/10.1001/jamaneurol.2014.1297).
- Kass-Iliyya L, Snowden JA, Thorpe A, et al. Autologous haematopoietic stem cell transplantation for refractory stiff-person syndrome: the UK experience. *J Neurol.* 2021;268:265–75. DOI: [10.1007/s00415-020-10054-8](https://doi.org/10.1007/s00415-020-10054-8).
- O'Toole O, Murphy R, Tracy JA, McKeon A. Teaching neuroImages: PET-CT hypermetabolism paralleling muscle hyperactivity in stiff-person syndrome. *Neurology.* 2013;80:e109–e109. DOI: [10.1212/WNL.0b013e3182840bad](https://doi.org/10.1212/WNL.0b013e3182840bad).
- Atkins HL, Bowman M, Allan D, et al. Immunoablation and autologous haemopoietic stem-cell transplantation for aggressive multiple sclerosis: a multicentre single-group phase 2 trial. *The Lancet.* 2016;388:576–85. DOI: [10.1016/S0140-6736\(16\)30169-6](https://doi.org/10.1016/S0140-6736(16)30169-6).
- Balint B, Meinck HM. Pragmatic treatment of stiff person spectrum disorders: pragmatic treatment of SPSP. *Mov Disord Clin Pract.* 2018;5:394–401. DOI: [10.1002/mdc3.12629](https://doi.org/10.1002/mdc3.12629).