

Cervical Column Morphology and Craniofacial Profiles in Monozygotic Twins

Liselotte Sonnesen,¹ Carsten Pallisgaard,² and Inger Kjær¹

¹ Department of Orthodontics, Institute of Odontology, Faculty of Health Sciences, Copenhagen University, Denmark

² Clinic of Orthodontics, Aalborg Community Dental Service, Denmark

Previous studies have described the relationships between cervical column morphology and craniofacial morphology. The aims of the present study were to describe cervical column morphology in 38 pairs of adult monozygotic (MZ) twins, and compare craniofacial morphology in twins with fusions with craniofacial morphology in twins without fusion. Visual assessment of cervical column morphology and cephalometric measurements of craniofacial morphology were performed on profile radiographs. In the cervical column, fusion between corpora of the second and third vertebrae was registered as fusion. In the twin group, 8 twin pairs had fusion of the cervical column in both individuals within the pair (subgroup A), 25 pairs had no fusions (subgroup B), and in 5 pairs, cervical column morphology was different within the pair (subgroup C), as one twin had fusion and the other did not. Comparison of craniofacial profiles showed a tendency to increased jaw retrognathia, larger cranial base angle, and larger mandibular inclination in subgroup A than in subgroup B. The same tendency was observed within subgroup C between the individual twins with fusion compared with those without fusion. These results confirm that cervical fusions and craniofacial morphology may be interrelated in twins when analysed on profile radiographs. The study also documents that differences in cervical column morphology can occur in individuals within a pair of MZ twins. It illustrates that differences in craniofacial morphology between individuals within a pair of MZ twins can be associated with cervical fusion.

Recently it has been reported that fusions of the upper cervical vertebrae occur in healthy subjects as well as in pathological cases. It has been found that in healthy subjects with normal craniofacial morphology and neutral occlusion, fusions between the second cervical vertebra, C2, and the third cervical vertebra, C3, occur in 14.3 per cent (Sonnesen et al., 2007). Therefore, fusions of the upper cervical column within that range are considered normal. Still, other previous studies have found an association between malformations of the upper cervical vertebrae and patients with cleft lip and/or palate (Horswell, 1991; Sandham, 1986; Ugar & Semb, 2001). Furthermore, an

association has been found between malformation of the upper cervical vertebrae, not only in patients with condylar hypoplasia (Sonnesen et al., 2007), but also in patients with extreme skeletal deep bite (Sonnesen & Kjær, 2007a), and extreme skeletal mandibular overjet (Sonnesen & Kjær, 2007b). The prevalence and the pattern of malformation of the upper cervical vertebrae in these cases were different from the prevalence and pattern found in healthy subjects with normal craniofacial morphology and neutral occlusion. This indicates that morphological deviations of the upper cervical vertebrae are associated with malformation of the jaw, craniofacial morphology, and occlusion.

In a previous study, an association was found between posture of the head and neck, and fusions of the upper cervical vertebrae (Sonnesen et al., 2007). Furthermore, previous studies have also found an association between the development of craniofacial morphology and posture of the head and neck (Helsing et al., 1987; Huggare, 1987; Huggare, 1991; Kylämarkula & Huggare, 1985; Marcotte, 1981; Sandikcioglu et al., 1994; Solow & Tallgren, 1976; Solow et al., 1984; Solow & Siersbæk-Nielsen, 1986; Solow & Siersbæk-Nielsen, 1992; Sonnesen et al., 2001). It is possible that fusions of the upper cervical vertebrae influence the posture of the head and neck, and thereby the development of craniofacial morphology and occlusion.

Previous studies have focused on the possibility of a genetic component in the development of craniofacial morphology and occlusion. In skeletal class III malocclusion it is known that there is a significant genetic component, and it has been observed for many years that mandibular prognathia is hereditary (Bui et al., 2006). In general though, the extent of the genetic contribution to variation in craniofacial development is still unclear. In order to try to clarify the genetic mapping of the development of craniofacial morphology, twins have been used

Received 27 September, 2007; accepted 24 October, 2007.

Address for correspondence: Liselotte Sonnesen, Department of Orthodontics, Institute of Odontology, Faculty of Health Sciences, Copenhagen University, 20 Nørre Allé, DK-2200 Copenhagen N, Denmark. E-mail: lls@odont.ku.dk

(Keusch et al., 1991; Lobb, 1987; Peng et al., 2005; Sorin et al., 1991; Townsend et al., 2006). In these studies, a genetic association has been demonstrated in craniofacial morphology of monozygotic (MZ) twins within a pair. Still, other twin studies have found a difference in craniofacial morphology between the individuals in a twin pair — for example, in cleft lip and palate patients (Chatzistavrou et al., 2004; Cronin & Hunter, 1980; Keusch et al., 1991; Laatikainen, 1999; Trotman et al., 1993).

Accordingly, it is relevant to focus on the prevalence and location of fusions of the cervical column, the associations between the morphology of the cervical column, and craniofacial morphology in adult MZ twins. Also, the discussion of similarities and dissimilarities within and between twin pairs are of importance for understanding the relationship between the morphology of the cervical column and the craniofacial profile. To our knowledge, no studies have so far been performed on cervical column morphology in MZ twins.

The aims of the present study were: (1) to describe the morphology of the cervical column in adult MZ twins, focusing on subgrouping the individuals according to occurrence of fusion between C2 and C3; and (2) to compare craniofacial morphology in a group of adult MZ twins with fusions with craniofacial morphology in twins without fusion.

Subjects

Craniofacial profiles from 38 MZ twins were included in the study. The twin group consisted of 21 females aged 18 to 23 years (mean age 21.1) and 17 males aged 18 to 23 years (mean age 20.2). The diagnosis of monozygosity was made using the method of the

Danish Twin Register (Hauge, 1981). Tests by similarity scheme, determination of three blood types (ABO, Rhesus, MNS), and a test of HLA (humans lymphocyte antigen), were also employed to assure monozygosity. The accuracy of the diagnosis of monozygosity was calculated to be 99.65 per cent. The twins had neutral occlusion or minor malocclusion, not requiring orthodontic treatment. The sample used has previously been described by Grymer et al. (1991). Twins are designated within the twin pair as either T1 or T2.

Method

The profile radiographs were taken in a cephalost, with a film-to-focus distance of 180 cm, and a film-to-median plane distance of 10 cm. No correction was made for the constant linear enlargement of 5.6 per cent (Grymer et al., 1991).

On each profile radiograph, the cervical column and the craniofacial profiles were described.

Subgrouping of Material According to Vertebral Column

The visual assessment of the cervical column consisted of the first five cervical vertebral units that are normally seen on a standardized lateral skull radiograph. Characteristics of the cervical column were classified according to Sandham (1986) and divided into two categories: 'Posterior arch deficiency' and 'Fusion anomalies'. Posterior arch deficiency consisted of partial cleft and dehiscence. Fusion anomalies consisted of fusion, block fusion, and occipitalization. Only fusion anomalies of fusion between corpora of the second (C2) and third vertebrae (C3) were found in the 38 MZ twin pairs. Accordingly, the 38 pairs were divided into three groups.

Table 1

Comparison of Craniofacial Profiles Between T1 and T2 Within the Twin Pair With Fusion (Subgroup A) and Comparison of Craniofacial Profiles Between T1 and T2 Within the Twin Pair Without Fusion (Subgroup B)

Variable (degrees)	Twins with fusion (A) (n = 8 twin pairs)				Twins without fusion (B) (n = 25 twin pairs)				p
	Mean	SD	Mean	SD	Mean	SD	Mean	SD	
Sagittal angles									
s-n-ss	79.88	5.98	79.44	7.60	81.24	4.75	81.18	3.52	NS
s-n-pg	79.38	4.48	79.06	6.01	81.38	3.66	80.98	3.65	NS
ss-n-pg	0.50	3.52	0.38	3.16	0.40	2.35	0.20	1.97	NS
ss-n-sm	2.06	3.08	2.00	2.49	2.00	1.88	2.19	1.94	NS
Vertical angles									
NSL-NL	8.62	3.53	7.69	2.30	8.30	2.94	8.56	3.19	NS
NSL-ML	31.81	10.18	31.44	9.45	27.96	7.03	27.66	6.50	NS
NL-ML	23.31	11.29	23.88	9.35	19.66	6.80	19.10	5.58	NS
Cranial base angle									
n-s-ba	133.12	4.39	134.36	5.13	131.94	2.24	133.69	5.44	NS
Incisor-relations									
Overjet (mm)	3.30	1.22	3.26	0.96	3.56	1.12	3.31	1.10	NS
Overbite (mm)	3.00	1.07	2.44	0.90	3.10	1.84	3.08	1.85	NS

Note: NS: Not significant, paired t test
p: p value

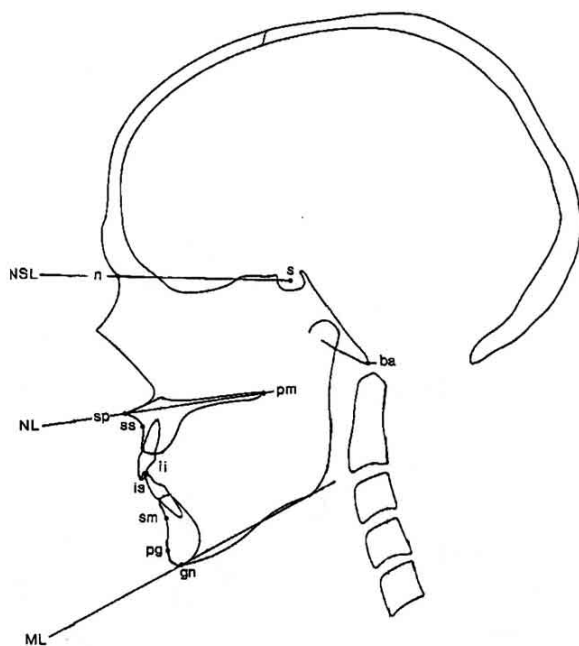


Figure 1
Cephalometric reference points and lines according to Solow and Tallgren (1976).

- Note: ML: Mandibular line. The tangent to the lower border of the mandible through gn
 NL: Nasal line. The line through sp and pm
 NSL: Nasion-sella line. The line through n and s
 gn: Gnathion. The most inferior point on the mandibular symphysis
 sp: spinal point. The apex of the anterior nasal spine
 pm: Pterygomaxillare. The intersection between the nasal floor and the posterior contour of the maxilla
 n: Nasion. The most anterior point of the frontonasal suture
 s: Sella. The centre of the sella turcica. The upper limit of the sella turcica is defined as the line joining the tuberculum and the dorsum sellae
 ba: Basion. The most postero-inferior point on the clivus
 ss: Subspinale. The most posterior point on the anterior contour of the upper alveolar arch
 sm: Supramentale. The most posterior point on the anterior contour of the lower alveolar arch
 pg: Pogonion. The most anterior point on the mandibular symphysis

- Subgroup A: twin pairs where both twins had fusions in the cervical column
- Subgroup B: twin pairs where neither twin had fusions in the cervical column.
- Subgroup C: twin pairs in which only one twin had fusion.

Craniofacial Dimensions

On each profile radiograph ten variables representing the cranial base angle, the vertical craniofacial dimensions, and the sagittal craniofacial dimensions were calculated (Table 1, Figure 1).

In twin pairs with different cervical column morphology within the twin pair (subgroup C), the profile radiographs were superimposed on the stable structures

in the anterior cranial base by the method previously used by Björk (1947, 1975) and traced accordingly.

Reliability

The reliability of the visual assessment of morphological characteristics of the cervical vertebral units was determined by inter-observer examinations between the authors. The inter-observer examinations showed ‘very good’ agreement ($K = .82$) as assessed by the kappa coefficient (Cohen, 1960).

The reliability of the variables describing the cranial base and vertical craniofacial dimensions was assessed by remeasurement of 20 lateral radiographs, selected at random from the previously recorded radiographs. The radiographs were digitized again after two weeks, and the differences between the two sets of recordings were calculated. No significant differences between the two sets of recordings were found. The method errors ranged from .09 to .69 degrees (Dahlberg, 1940), and the reliability coefficients from .99 to 1.00 (Houston, 1983).

Statistical Methods

The normality of the distributions was assessed by parameters of skewness and kurtosis, and by Shapiro-Wilks W-test. The cephalometric measurements were normally distributed. Differences in means of craniofacial dimensions between groups, and between subjects with and without fusions of the cervical column, were assessed by unpaired *t*-test. Differences within the groups were assessed by paired *t* test. The results from these tests were considered to be significant at *p* values below .05. Statistical analyses were performed using Statistical Package for Social Sciences, version 13.00 (SPSS, Inc., Chicago, Illinois, USA).

Results

Subgrouping According to Fusion of the Cervical Column

Of the total twin group, eight pairs (21%) had fusion of the cervical column in both individuals within the twin pair (subgroup A), 25 pairs (66%) had no fusions (subgroup B), and in five pairs (13%) the cervical column morphology was different within the pair (subgroup C). In each twin pair in subgroup C, one twin had fusion and the other had no fusion.

Craniofacial Morphology in and Between the Subgroups

The differences in craniofacial profiles between T1 and T2 within the twin pair with fusion (subgroup A) were not statistically significant. The differences in craniofacial profiles between T1 and T2 within the twin pair without fusion (subgroup B) were also not statistically significant (Table 1). Therefore, cephalometric values from T1 and T2 were added in subgroup A, and the combined values considered representative for craniofacial profiles in subgroup A. In subgroup B, the cephalometric values were likewise added, and the combined values considered representative of the group craniofacial profile. Comparison between subgroup A and subgroup B was then performed (Table 2).

Table 2

Comparison of Craniofacial Profiles in the Twin Group Where Both Twins Had Fusion (Subgroup A) and in the Twin Group Where Both Twins in the Pair Had No Fusion (Subgroup B)

Variable (degrees)	Twin group with fusion (<i>n</i> = 8 twin pairs)		Twin group without fusion (<i>n</i> = 25 twin pairs)		<i>p</i>
	Mean	<i>SD</i>	Mean	<i>SD</i>	
Sagittal angles					
s-n-ss	79.66	6.59	81.21	3.76	NS
s-n-pg	79.22	5.12	81.36	3.75	NS
ss-n-pg	0.44	3.12	0.30	1.99	NS
ss-n-sm	2.03	2.54	2.07	1.71	NS
Vertical angles					
NSL-NL	8.16	2.73	8.43	2.84	NS
NSL-ML	31.63	9.75	27.81	6.48	NS
NL-ML	23.59	10.21	19.38	5.98	NS
Cranial base angle					
n-s-ba	133.83	4.43	132.81	3.72	NS
Incisor-relations					
Overjet (mm)	3.44	0.97	3.28	0.95	NS
Overbite (mm)	2.72	0.92	3.09	1.74	NS

Note: NS: Not significant, unpaired *t* test
p: *p* value

Craniofacial profiles of subgroup A showed a tendency to retrognathia, of the jaw (s-n-ss, s-n-pg), larger cranial base angle (n-s-ba), and larger mandibular and maxillary inclination (NSL-ML, NSL-NL), when compared with subgroup B (Table 2). The same tendency was observed in the 5 twin pairs in subgroup C. When the 5 individual twins with fusion were compared with the 5 individual twins without fusion, those with fusion showed a tendency to retrognathia, of the jaws (s-n-ss, s-n-pg), larger cranial base angle (n-s-ba), and larger mandibular and maxillary inclination (NSL-ML, NSL-NL), when compared with those without fusion (Table 3, Figures 2–6). Statistically, these tendencies to differ in craniofacial profile were not significant.

Discussion

The aims of this study were to describe the morphology of the cervical column in adult MZ twins, focusing on subgrouping the individuals according to the occurrence of fusion, and to compare craniofacial morphology in a group of adult MZ twins with fusions with craniofacial morphology in twins without fusion. Analyses of the cervical column and comparison of the findings to the craniofacial profile in adult MZ twins have not previously been described in the literature.

Morphology of the Cervical Column

In this study, when compared with a singleton group with neutral occlusion, the prevalence and location of cervical vertebral body fusions was approximately the same in MZ twins where both twins had neutral occlusion with fusion of the cervical column (Sonnesen et al., 2007). In both groups, the cervical vertebral body fusions always occurred between the

corpora of the second (C2) and third vertebrae (C3), and the prevalence ranged between 14% to 20%. This finding confirms that it is considered normal to have fusions between C2 and C3 within the range of 14% to 20%, and accordingly, the present twin data increases the normal data available for future investigations, and strengthens previous studies. Furthermore, it can be concluded that MZ twins with neutral occlusion, or minor malocclusion, do not have significantly more fusions compared with singletons with neutral occlusion (Sonnesen et al., 2007). Still, previous studies of groups with severe skeletal malocclusions in patients with extreme skeletal deep bite (Sonnesen & Kjær, 2007a) and extreme skeletal mandibular overjet (Sonnesen & Kjær, 2007b) showed that the prevalence of cervical body fusion was higher, ranging from 42% to 61%.

In the present study, five twin pairs were found to have differences in cervical column morphology within the pair. In each case, one twin in the pair had fusion of the cervical column and the other twin did not. This finding documents that differences in cervical column morphology can occur in individuals within a pair of genetically MZ twins.

Craniofacial Dimensions

Even though the association between cervical column morphology and craniofacial morphology was not statistically significant in the present study, the same tendency was illustrated systematically in all the subgroups. Most interesting is the finding that, in twin pairs where the twins each have different cervical column morphology, there is a tendency to retrognathia of the jaws, a larger cranial base angle, and a larger inclination of the mandible and maxilla, in the

Table 3

Comparison of Craniofacial Profiles in the Twin Group Between Five Individual Twins With Fusion and Five Individual Twins Without Fusion (Subgroup C)

Variable (degrees)	Twin group with fusion (<i>n</i> = 5 twin pairs)		Twin group without fusion (<i>n</i> = 5 twin pairs)		<i>p</i>
	Mean	<i>SD</i>	Mean	<i>SD</i>	
Sagittal angles					
s-n-ss	79.00	3.98	80.50	3.50	NS
s-n-pg	80.50	3.59	81.80	3.62	NS
ss-n-pg	-1.10	1.29	-1.30	1.57	NS
ss-n-sm	0.90	1.24	0.60	2.07	NS
Vertical angles					
NSL-NL	8.20	3.91	7.60	3.91	NS
NSL-ML	29.00	7.58	28.50	6.71	NS
NL-ML	20.80	6.75	20.90	7.14	NS
Cranial base angle					
n-s-ba	133.40	7.67	132.00	7.65	NS
Incisor-relations					
Overjet (mm)	3.60	0.55	2.50	1.32	NS
Overbite (mm)	2.80	2.17	2.60	1.67	NS

Note: NS: Not significant, unpaired *t* test
p: *p* value

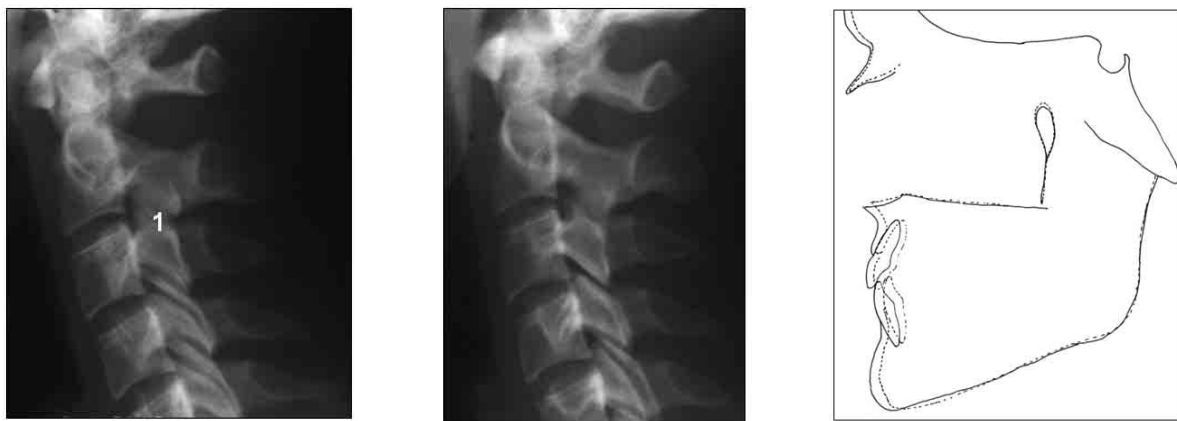

Figure 2

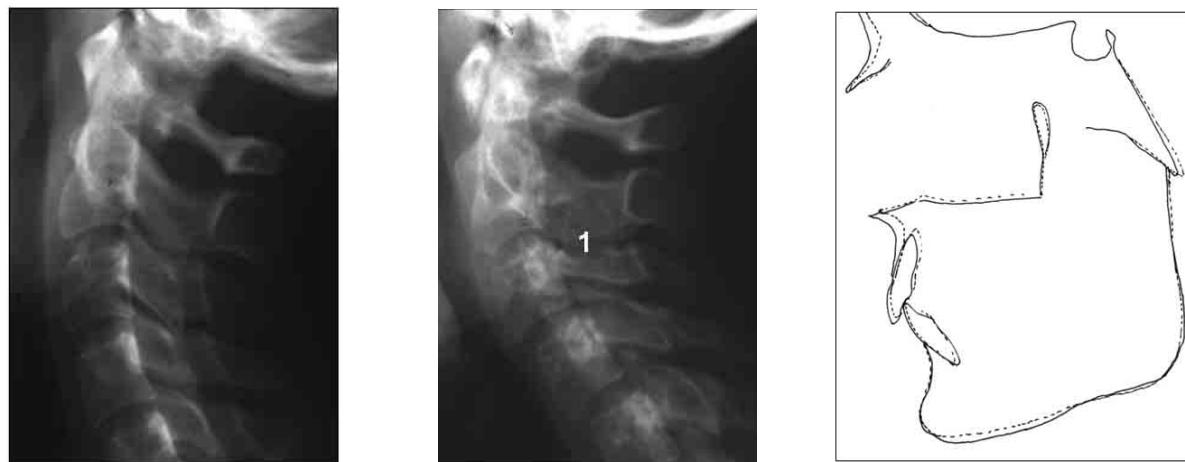

Figure 3

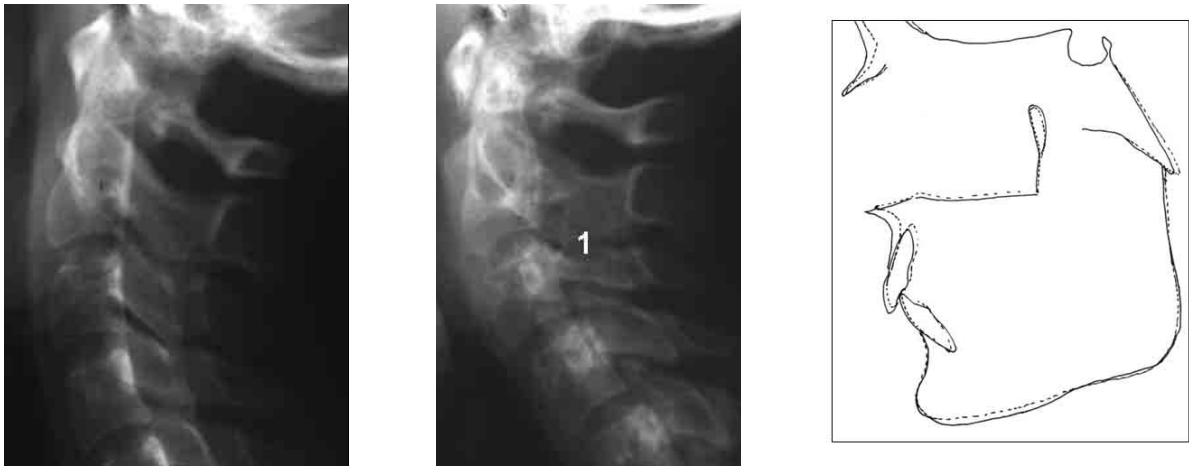

Figure 4

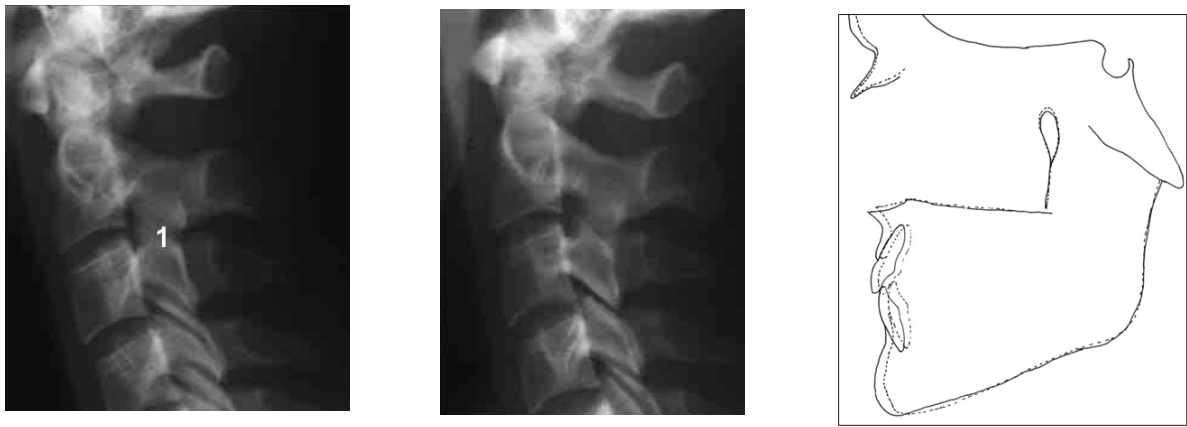

Figure 5

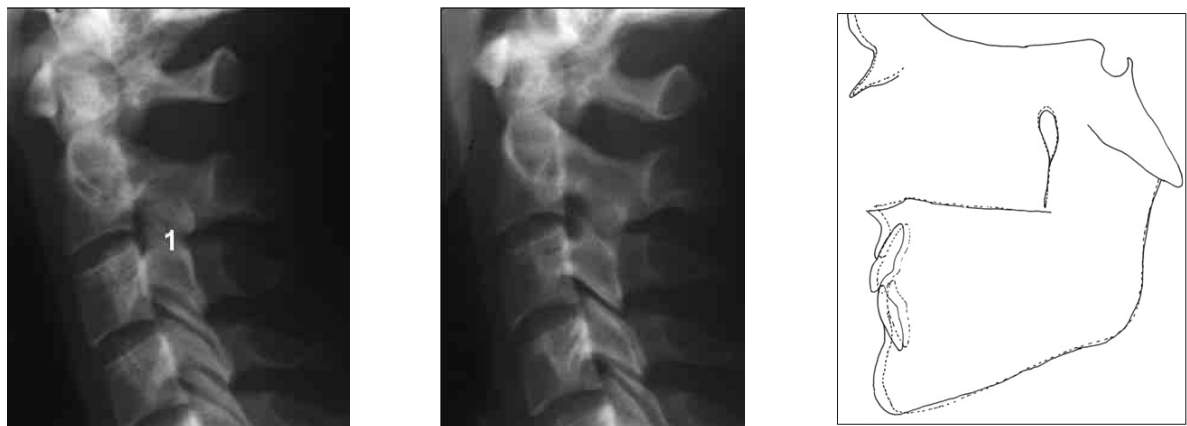

Figure 6

Figures 2–6

Drawings of structures observed on profile radiographs from five twin pairs. Within each of the five pairs one twin had fusion (dotted line) and the other had no fusion (solid line). The drawings demonstrate differences in craniofacial morphology between the individual twins within the pairs. Radiographs were superimposed on the stable structures in the anterior cranial base.

Note: 1: Fusion of the second and third cervical vertebrae on profile radiographs.

- Tracing of the twin with fusion of the cervical vertebrae
- ____ Tracing of the twin without fusion of the cervical vertebrae

twin with fusion of the cervical column compared with the twin without fusion. This pattern of skeletal differences in craniofacial profile in individuals with minor malocclusions is the same pattern found in previous studies on associations between the morphology of the cervical column and craniofacial morphology in patients with severe skeletal malocclusion and craniofacial morphology (Sonnesen & Kjær 2007a; 2007b). It is expected, and logical, that the deviations are less in minor malocclusions than in severe malocclusions, but it is interesting that the pattern of deviation in the two types of malocclusion is the same. The twin sample has provided a unique opportunity to study associations between fusion of the cervical column and craniofacial morphology on genetically MZ subjects.

An explanation for the association between retrognathia of the jaws and fusions of the cervical vertebral bodies may be found in the signalling from the notochord to the neural crest cells determined for craniofacial morphology before the notochord is surrounded by bone tissue (vertebral bodies) and disappears (Kjær et al., 1994; Kjær, 1995; Kjær & Fischer-Hansen, 1995; Kjær, 1998; Müller & O'Rahilly, 1980; Nolting et al., 1998; Sadler, 2005). The jaws develop from tissue that derives from the neural crest. In the first branchial arch, the neural crest cells migrate from the neural crest towards the mandible, followed by the cells to the maxilla, and lastly by the cells to the nasofrontal region (Kjær, 1998). How the migration of the neural crest cells is influenced by signals from the notochord is still unclear. The genetic signalling during early embryogenesis between the notochord, paraaxial mesoderm, the neural tube, and the neural crest may explain the association between retrognathia of the craniofacial structures and the cervical vertebrae.

In the present study, as in previous MZ twin studies (Chatzistavrou et al., 2004; Cronin & Hunter, 1980; Keusch et al., 1991; Laatikainen, 1999; Trotman et al., 1993), twins within the twin pair did have individual differences in craniofacial morphology, even though their genotype was MZ. Whether the differences within the MZ twin pairs here were caused by mutations, environmental factors, or by coincidences, can be questioned. It is possible that fusions of the cervical vertebral bodies influence the posture of the head and neck, and thereby the development of craniofacial morphology. A previous study found an association between the inclination of the cervical column and fusions of the cervical vertebral bodies (Sonnesen et al., 2007). Furthermore, other previous studies have found an association between the development of craniofacial morphology and posture of the head and neck (Hellsing et al., 1987; Huggare, 1987; Huggare, 1991; Kylämarkula & Huggare, 1985; Marcotte, 1981; Sandikcioglu et al., 1994; Solow & Tallgren, 1976; Solow et al., 1984; Solow & Siersbæk-Nielsen, 1986; Solow & Siersbæk-Nielsen, 1992; Sonnesen et al., 2001). The findings in the present study illustrate that

differences in craniofacial morphology between individuals within a pair of MZ twins can be associated with deviations in the cervical column.

Conclusions

In the twin group, eight twin pairs had fusion of the cervical column in both individuals within the pair (subgroup A), 25 pairs had no fusions (subgroup B), and in five pairs the cervical column morphology was different within the pair (subgroup C), as one twin had fusion and the other did not. Craniofacial profiles in subgroup A compared with subgroup B showed a tendency to retrognathia of the jaws, larger cranial base angle, and larger mandibular and maxillary inclination. The same tendency was observed within subgroup C between the individual twins with fusion compared with those without fusion.

These results confirm that cervical fusions and craniofacial morphology may be interrelated in twins when analysed on craniofacial profile radiographs. The study also documents that differences in cervical column morphology can occur in individuals within a pair of MZ twins. It illustrates that differences in craniofacial morphology between individuals within a pair of MZ twins can be associated with deviations in the cervical column.

Acknowledgments

Maria Kvetny, MA, is acknowledged for linguistic support and manuscript preparation. The study has been financial supported by the IMK Foundation.

References

- Björk, A. (1947). *The face in profile*. Svensk Tandläkebladet, 40, Supplement 5B.
- Björk, A. (1975). Kæbernes relation til det øvrige kranium. In A. Lundstrøm (Ed.), *Nordisk Lærobok i Ortodonti* (pp. 69–110). Stockholm: Sveriges Tandläkarförbunds Förlagsförening.
- Bui, C., King, T., Proffit, W., & Frazier-Bowers, S. (2006). Phenotypic characterization of Class III patients. A necessary background for genetic analysis. *Angle Orthodontist*, 76, 564–569.
- Chatzistavrou, E., Ross, R. B., Tompson, B. D., & Johnston, M. C. (2004). Predisposing factors to formation of cleft lip and palate: Inherited craniofacial skeletal morphology. *Cleft Palate Craniofacial Journal*, 41, 613–621.
- Cohen, J. (1960). A coefficient of agreement for nominal scales. *Educational and Psychological Measurement*, 20, 37–46.
- Cronin, D. G., & Hunter, W. S. (1980). Craniofacial morphology in twins discordant for cleft lip and/or palate. *The Cleft Palate Journal*, 17, 116–126.
- Dahlberg, G. (1940). *Statistical methods for medical and biological students*. New York: Interscience Publications.

- Grymer, L. F., Pallisgaard, C., & Melsen, B. (1991). The nasal septum in relation to the development of the nasomaxillary complex: A study in monozygotic twins. *Laryngoscope*, *101*, 863–868.
- Hauge, M. (1981). The Danish twin register. In S. A. Mednick, A. E. Baert & B. P. Bachmann (Eds.), *Prospective longitudinal research. An empirical basis for the primary prevention of psychosocial disorders* (pp. 218–221). New York: Oxford University Press.
- Hellsing, E., McWilliam, J., Reigo, T., & Spangfort, E. (1987). The relation between craniofacial morphology, head posture and spinal curvature in 8, 11 and 14-year-old children. *European Journal of Orthodontics*, *9*, 254–264.
- Horswell, B. B. (1991). The incidence and relationship of cervical spine anomalies in patients with cleft lip and/or palate. *Journal of Oral Maxillofacial Surgery*, *49*, 693–697.
- Houston, W. J. B. (1983). The analysis of errors in orthodontic measurements. *American Journal of Orthodontics*, *83*, 382–390.
- Huggare, J. (1987). A cross-sectional study of head posture and craniofacial growth in children from the north of Finland. *Proceedings of the Finnish Dental Society*, *83*, 5–15.
- Huggare, J. (1991). Association between morphology of the first cervical vertebra, head posture, and craniofacial structures. *European Journal of Orthodontics*, *13*, 435–440.
- Keusch, C. F., Mulliken, J. B., & Kaplan, L. C. (1991). Craniofacial anomalies in twins. *Plastic and Reconstructive Surgery*, *87*, 16–23.
- Kjær, I. (1995). Human prenatal craniofacial development related to brain development under normal and pathologic conditions. *Acta Odontologica Scandinavica*, *53*, 135–143.
- Kjær, I. (1998). Neuro-osteology. *Critical Review of Oral Biology Medicine*, *9*, 224–244.
- Kjær, I., & Hansen, B. F. (1995). The adeno-hypophysis and the cranial base in early human development. *Journal of Craniofacial Genetic Deviation Biology*, *15*, 157–161.
- Kjær, I., Keeling, J. W., & Græm, N., (1994). Midline maxillofacial skeleton in human anencephalic fetuses. *Cleft Palate-Craniofacial Journal*, *31*, 250–256.
- Kylämarkula, S., & Huggare, J. (1985) Head posture and the morphology of the first cervical vertebra. *European Journal of Orthodontics*, *7*, 151–156.
- Laatikainen, T. (1999). Etiological aspects on craniofacial morphology in twins with cleft lip and palate. *European Journal of Oral Sciences*, *107*, 102–108.
- Lobb, W. K. (1987). Craniofacial morphology and occlusal variation in monozygous and dizygous twins. *Angle Orthodontist*, *57*, 219–233.
- Marcotte, M. R. (1981) Head posture and dentofacial proportions. *Angle Orthodontist*, *51*, 208–213.
- Müller, F., & O’Rahilly, R. (1980). The early development of the nervous system in staged insectivore and primate embryos. *The Journal of Comparative Neurology*, *193*, 741–751.
- Nolting, D., Hansen, B. F., Keeling, J. W., & Kjær, I. (1998). Prenatal development of the normal human vertebral corpora in different segments of the spine. *Spine*, *23*, 2265–2271.
- Peng, J., Deng, H., Cao, C., & Ishikawa, M. (2005). Craniofacial morphology in Chinese female twins: A semi-longitudinal cephalometric study. *European Journal of Orthodontics*, *27*, 556–561.
- Sadler, T. W. (2005). Embryology of the neural tube development. *American Journal of Medical Genetics*, *135C*, 2–8.
- Sandham, A. (1986). Cervical vertebral anomalies in cleft lip and palate. *Cleft Palate Journal*, *23*, 206–214.
- Sandikcioglu, M., Skov, S., & Solow, B. (1994). Atlas morphology in relation to craniofacial morphology and head posture. *European Journal of Orthodontics*, *16*, 96–103.
- Solow, B., Siersbæk-Nielsen, S., & Greve, E. (1984). Airway adequacy, head posture, and craniofacial morphology. *American Journal of Orthodontics*, *86*, 214–223.
- Solow, B., & Siersbæk-Nielsen, S. (1986). Growth changes in head posture related to craniofacial development. *American Journal of Orthodontics*, *89*, 132–140.
- Solow, B., & Siersbæk-Nielsen, S. (1992). Cervical and craniofacial posture as predictors of craniofacial growth. *American Journal of Orthodontics and Dentofacial Orthopedics*, *101*, 449–458.
- Solow B., & Tallgren, A. (1976). Head posture and craniofacial morphology. *American Journal of Physical Anthropology*, *44*, 417–435.
- Sonnesen, L., Bakke, M., & Solow, B. (2001). Temporomandibular disorders in relation to craniofacial dimensions, head posture and bite force in children selected for orthodontic treatment. *European Journal of Orthodontics*, *23*, 179–192.
- Sonnesen, L., & Kjær, I. (2007a). Cervical vertebral body fusions in patients with skeletal deep bite. *European Journal of Orthodontics*, *29*, 464–470.
- Sonnesen, L., & Kjær, I. (2007b). Cervical column morphology in patients with skeletal class III and mandibular overjet. *American Journal of Orthodontics and Dentofacial Orthopedics*, *132*, 427, e7–12.
- Sonnesen, L., Pedersen, C. E., & Kjær, I. (2007). Cervical column morphology related to head posture, cranial base angle, and condylar malformation. *European Journal of Orthodontics*, *29*, 398–403.
- Sorin, M. S., Ramsey, T. C., Hart, T. C., & Farrington, F. H. (1991). Comparison of craniofacial morphology in

- monozygotic twins with their siblings. *Journal of Clinical Pediatric Dentistry*, 15, 169–173.
- Townsend, G., Richards, L., Messer, L. B., Hughes, T., Pinkerton, S., Seow, K., Gotjamanos, T., Gully, N., & Bockmann, M. (2006). Genetic and environmental influences on dentofacial structures and oral health: Studies of Australian twins and their families. *Twin Research and Human Genetics*, 9, 727–732.
- Trotman, C. A., Collett, A. R., McNamara, J. A. jr., & Cohen, S. R. (1993). Analyses of craniofacial and dental morphology in monozygotic twins discordant for cleft lip and unilateral cleft lip and palate. *Angle Orthodontist*, 63, 135–139.
- Ugar, D. A., & Semb, G. (2001). The prevalence of anomalies of the upper cervical vertebrae in subjects with cleft lip, cleft palate, or both. *Cleft Palate-Craniofacial Journal*, 38, 498–503.
-