

Original Article

Cite this article: Hendriks AA, Kis Z, Akca F, Yap S-C, Wijchers SA, Bhagwandien RE, and Szili-Torok T (2020) Extensive scar modification for the treatment of intra-atrial re-entrant tachycardia in patients after congenital heart surgery. *Cardiology in the Young* 30: 1231–1237. doi: [10.1017/S1047951120001900](https://doi.org/10.1017/S1047951120001900)

Received: 8 December 2019
Revised: 4 May 2020
Accepted: 14 June 2020
First published online: 23 July 2020

Keywords:

Catheter ablation; atrial tachycardia; CHD; extensive scar modification

Author for correspondence:

Tamas Szili-Torok, MD, PhD, Thoraxcenter, Department of Clinical Electrophysiology, Erasmus MC, Postbus 2040, 3015 CE Rotterdam, The Netherlands. Tel: +31-10-7033991; Fax: +31-10-7034420. E-mail: t.szilitorok@erasmusmc.nl

Extensive scar modification for the treatment of intra-atrial re-entrant tachycardia in patients after congenital heart surgery

Astrid A. Hendriks , Zsuzsanna Kis, Ferdi Akca, Sing-Chien Yap, Sip A. Wijchers, Rohit E. Bhagwandien and Tamas Szili-Torok

Department of Clinical Electrophysiology, Erasmus Medical Center, Rotterdam, The Netherlands

Abstract

Background: Catheter ablation is an important therapeutic option for atrial tachycardias in patients with CHD. As a result of extensive scarring and surgical repair, multiple intra-atrial re-entrant tachycardia circuits develop and serve as a substrate for arrhythmias. The best ablation approach for patients with multiple intra-atrial re-entrant tachycardias has not been investigated. Here, we compared substrate-based ablation using extensive scar modification to conventional ablation. **Methods:** The present study included patients with surgically corrected CHD that underwent intra-atrial re-entrant tachycardia ablation. Extensive scar modification was defined as substrate ablation based on a dense voltage map, aimed to eliminate all potentials in the scar region. The control group had activation mapping-based ablation. A clinical composite endpoint was assessed. Points were given for type, number, and treatment of intra-atrial re-entrant tachycardia recurrence. **Results:** In 40 patients, 63 (extensive scar modification 13) procedures were performed. Acute procedural success was achieved in 78%. Procedural duration was similar in both groups. Forty-nine percent had a recurrence within 1 year. During a 5-year follow-up (2.5–7.5 years), 46% required repeat catheter ablation. Compared to baseline, clinical composite endpoint significantly decreased by 46% after 12 months ($p = 0.001$). Acute procedural success, procedural parameters, recurrence and repeat ablation were similar between extensive scar modification and activation mapping-based ablation. **Conclusion:** Catheter ablation using extensive scar modification for intra-atrial re-entrant tachycardias occurring after surgically corrected CHD illustrated similar short- and long-term outcomes and procedural efficiency compared to catheter ablation using activation mapping-based ablation. The choice of ablation approach for multiple intra-atrial re-entrant tachycardia should remain at the discretion of the operator.

Atrial arrhythmias have a major impact on the quality of life in patients with CHD. Surgical incisions in the atrium and atrial fibrosis form the substrate of intra-atrial re-entrant tachycardia. The presence of extensive scar may cause multiple intra-atrial re-entrant tachycardia circuits.^{1–3} During catheter ablation, the mapping of all the critical isthmuses of these circuits can be time-consuming. Moreover, even after a successful ablation of all identified critical isthmuses, the long-term results are hampered by a high recurrence rate.^{4,5} A scar-related approach has been used with success in patients with scar-related ventricular tachycardia⁶ and even in atrial fibrillation.⁷

One of the most important limitations of long-term success in this population is complex scar with multiple re-entrant circuits. To the best of our knowledge, there have not been studies performed addressing this small but very significant patient group. Extensive scar modification is a treatment option for multiple intra-atrial re-entrant tachycardia circuits using the same scar. We hypothesised that extensive scar modification compared to activation map-based ablation for the treatment of intra-atrial re-entrant tachycardia in patients with CHD reduces procedure times and improves efficiency of procedural outcomes.

Methods**Study population and data collection**

Forty-eight consecutive patients with a surgically corrected congenital defect and atrial arrhythmias were screened. Forty of these patients had entrainable tachycardias and were included into the study. These 40 patients underwent 63 ablation procedures for scar-related intra-atrial re-entrant tachycardia between May 2006 and May 2016 in our centre. Intra-atrial re-entrant tachycardia was defined as an arrhythmia from which the central obstacle was a surgical scar or any anatomical barrier other than the tricuspid annulus.⁸ If more than three different intra-atrial re-entrant tachycardias were present, we defined it as multiple.

© The Author(s), 2020. Published by Cambridge University Press. This is an Open Access article, distributed under the terms of the Creative Commons Attribution licence (<http://creativecommons.org/licenses/by/4.0/>), which permits unrestricted re-use, distribution, and reproduction in any medium, provided the original work is properly cited.

All catheter ablation procedures were performed in accordance with institutionally approved local medical treatment protocols. The local ethical committee approved data collection (MEC-2016-705). Procedural informed consent was obtained from all the patients prior to the electrophysiological study. All patient information was de-identified.

Procedural protocol

Anti-arrhythmic drugs were discontinued for at least four half lives prior to the procedure with the exception of amiodarone. The procedures were performed under local or general anaesthesia. The procedures were guided using EnSite NavX 3D (St. Jude Medical Inc., St. Paul, Minnesota, United States of America) mapping or CARTO system (Biosense Webster, Inc., Diamond Bar, California, United States of America). Only detailed extensive maps were included in the study. Intracardiac bipolar electrograms filtered at 30 to 500 Hz were recorded by a computerised electrophysiological recording system. In all catheter ablations for intra-atrial re-entrant tachycardia, the chamber of origin was determined. When a left-sided intra-atrial re-entrant tachycardia was suspected, a deflectable decapolar catheter was inserted into the coronary sinus and functioned as a reference mapping catheter.

Per definition re-entry is the mechanism in patients with intra-atrial re-entrant tachycardia, and mapping is aimed to map the whole cycle length. Intra-atrial re-entrant tachycardias were separated from another based on both morphology and cycle length.

The target of ablation was identified by activation and/or voltage mapping. Irrigated catheters were used for the majority of the procedures. The electrode-tip temperature limit was set at 43°C, with a power ranging from 30 to 45 W, and needed irrigation flow of 20–30 ml/min. The catheter selection was dependent on clinical judgement of the operator. Remote magnetic navigation (Stereotaxis, Inc., St. Louis, Missouri, United States of America) was used in 58% of the cases.

If the patient was not in atrial tachycardia at the beginning of the procedure, atrial tachycardia was induced, most commonly with rapid atrial pacing or atrial extra-stimuli. An electroanatomic map was created during atrial tachycardia. The only exception for creating a biatrial map was if activation mapping-based ablation was performed and the whole atrial cycle length could be mapped in the chamber of origin and tachycardias remained non-inducible after ablation. Entrainment pacing was used to identify and/or confirm atrial tachycardia circuits. Sites with a post-pacing interval minus atrial tachycardia cycle length within 30 ms were considered to lie within the circuit. Hereafter in the presence of multiple re-entry circuits and at the preference of the operator, a conventional activation mapping-based ablation or extensive scar modification approach was chosen.

Activation mapping-based approach

A line was created across the critical isthmus, usually between areas of scar or between a scar and an anatomical structure (e.g. the inferior caval vein, superior caval vein or tricuspid annulus). Pacing was performed to prove bidirectional block. Localised re-entry was treated with discrete ablation lesions. After termination of an intra-atrial re-entrant tachycardia, we attempted to re-induce the intra-atrial re-entrant tachycardia using the stimulation protocol as described previously.

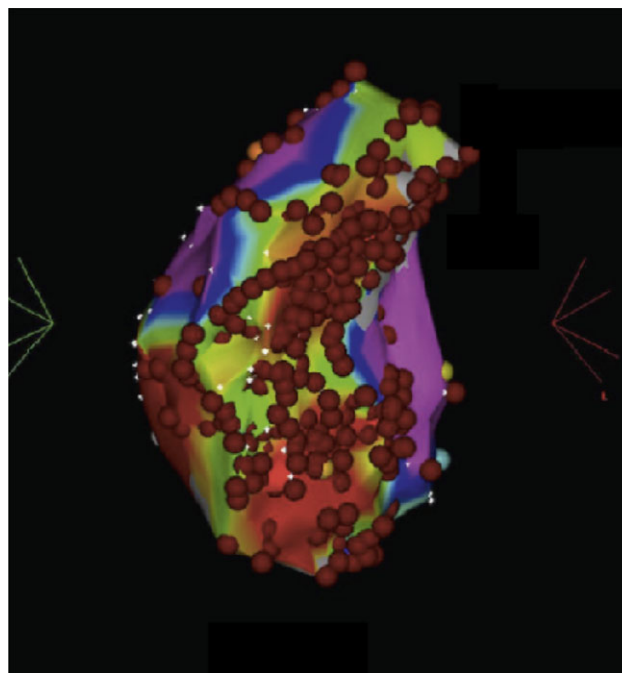


Figure 1. An illustration of a patient with atrial extensive scar modification. This is an illustration of a CARTO map of patient who underwent extensive scar modification. Bipolar voltage scale was in the range of 0.1–0.5 mV. The dots represent a location of ablation. In case of dragging every 15 seconds, a subsequent dot is placed.

Extensive scar modification

Using a detailed 3D bipolar voltage map, an effort was made to identify the sites of surgical incisions and sutures. Substrate mapping was performed during sinus rhythm with standard settings defined as normal tissue greater than 0.5 mV and very low-voltage area as 0.1 mV.⁹ Dense scar was defined as areas with amplitudes less than the baseline noise level of the recording system (amplitude of <0.05 mV). Maps were considered complete when both atria were extensively mapped and all scar borders were clearly defined. After mapping, the ablation was extended throughout the entire scar.⁹ Ablation was continued until the scar was unexcitable which was proven with pacing manoeuvres. A final result of extensive scar modification is illustrated in Figure 1.

Post-procedural protocol

All patients underwent continuous rhythm monitoring for 48 hour, a resting 12-lead electrocardiogram, laboratory tests and chest radiograph after the procedure. Regular follow-up was performed at 3 months after the ablation and thereafter depending on the underlying symptoms and pathology for every 3–12 months. A 24-hour Holter recording was performed when a patient experienced recurrence symptoms.

Outcome definitions

We analysed the following outcome data per strategy (substrate – extensive scar modification versus non-substrate – activation mapping-based ablation): acute procedural success, early atrial tachycardia recurrences, median time to atrial tachycardia recurrence and redo and His bundle ablations during follow-up. Acute procedural success was defined as termination and non-inducibility of all intra-atrial re-entrant tachycardia. Any atrial

Table 1. Clinical composite endpoint count

Points	Documented intra-atrial re-entrant tachycardia	Acute treatment	Long-term treatment
0	None	None	None, betablocker, verapamil, digoxin
1	Non-sustained only	1 ECV	Class I, sotalol
2	One sustained	>2 ECV	Class III
3	Incessant	Hospitalisation for symptoms of heart failure, syncope of cardiac arrest	His, repeat ablation

ECV = electrical cardioversion.

tachycardia during follow-up was considered a recurrence. Early recurrences were defined as recurrences within 1 year after ablation. If during an electrophysiology study the arrhythmia was an isthmus-dependent atrial flutter without the involvement of scar, it was not considered a repeat ablation.

A clinical composite endpoint was calculated at baseline, at 6 months' and 12 months' follow-up. The clinical composite endpoint was a score per subject and therefore only focused on the index procedure (first procedure in our centre, or first procedure after May 2006). Points (1–4) were given for three categories: electrocardiographically documented occurrence of intra-atrial re-entrant tachycardia, acute and long-term treatment (Table 1). Review of medical records and procedure notes was performed to ascertain the dates of occurrence of cardioversion and emergency room visit or hospital admission for management of arrhythmia or symptoms of the arrhythmia.

Statistical analysis

Data were analysed using SPSS 15.0 (SPSS Inc., Chicago, IL, United States of America). Descriptive statistics for categorical data were expressed in absolute numbers and percentages. Student t-test, chi-square test and Fisher exact test were used to compare differences across groups. After checking for normality, mean values and standard deviations were calculated for normally distributed continuous variables. Median and interquartile ranges were computed for continuous variables with non-normal distribution, and the Mann-Whitney U-test to compute statistical significance. Wilcoxon signed rank test was used to calculate differences in significance for the clinical composite endpoint at different points in time. A two-sided P-value <0.05 (two tailed) was considered significant.

Results

Clinical characteristics

Sixty-three procedures for intra-atrial re-entrant tachycardia in a total of 40 patients with surgically repaired CHD were included in this analysis (one procedure n = 21, two procedures n = 15 and three procedures n = 4). Thirteen procedures were a substrate approach. Two patients with an activation mapping-based ablation index procedure (Supplement 2A) underwent extensive scar modification during a repeat procedure. Two patients with an extensive scar modification index procedure (Supplement 2B) underwent

an activation mapping-based ablation approach during the repeat procedure.

A median number of two sustained intra-atrial re-entrant tachycardia episodes were recorded in the 6 months before ablation. Four patients had incessant intra-atrial re-entrant tachycardia at the index procedure. Thirty-one percent used Amiodarone at baseline. Six procedures were performed in children.

In 13 intra-atrial re-entrant tachycardia ablation procedures, the approach was extensive scar modification, and in 50 procedures, it was activation mapping-based ablation. In 43 out of 63 procedures, multiple intra-atrial re-entrant tachycardias could be induced. There were no differences in baseline characteristics between the two groups (Table 2). The congenital cardiac anomalies in this cohort are described in Table 3 according to the presence of multiple intra-atrial re-entrant tachycardia and extensive scar modification. Transposition of the great arteries was present in 12 cases, Ebstein or tricuspid atresia in eight cases and tetralogy of Fallot in five cases. Six out of forty patients had a Fontan operation, and 10 patients were following a Mustard operation.

Procedural data

Number of applications (26 – interquartile range 18–69), time (1124 seconds – interquartile range 627–2385) and procedural duration (240 minutes – interquartile range 163–298) were similar in both groups (Table 4).

Complications

There were six complications, one in the extensive scar modification group and five in the activation mapping-based ablation group (8 and 9%, respectively, in extensive scar modification and activation mapping-based ablation) (P = Not Significant). Four were vascular peripheral complications: there were two haematomas, one arterio-venous fistula and one thrombus in the common femoral artery in relation to a percutaneous left ventricular support device. There was one cerebral vascular event in a patient who had an activation mapping-based ablation approach. One ablation led to altered impedance of the pacemaker lead.

Outcome of the procedures

Acute procedural success was reached in 78% (Table 5) of the intra-atrial re-entrant tachycardia population. Forty-nine percent of the total patients had a recurrence within 1 year. One patient was lost to follow-up. The median time to recurrence was 120 days (interquartile range 30–525). In case of a successful procedure (50), the 1-year recurrence rate was 45%. In case of an unsuccessful procedure (13), there was a 1-year recurrence rate of 57% (p = 0.55). The clinical composite endpoint in the overall group was reduced by more than one-third after 6 and 12 months (Fig 2). After 6 and 12 months, 66 and 68% of the patients improved. This was a significant change compared to baseline (Table 6) (Fig 2). Three patients required reinstitution and two patients needed an increase of anti-arrhythmic drugs at 12 months after the index procedure, while seven patients were able to discontinue their anti-arrhythmic drugs altogether. Of the 16 patients with an early recurrence of intra-atrial re-entrant tachycardia, 4 had non-sustained atrial tachycardia episodes.

Table 2. Baseline characteristics

	Total N = 63 procedures	Extensive scar modification N = 13 procedures	Activation mapping-based ablation N = 50 procedures	p-value
Male	40 (64)	9/13 (69)	31/50 (62)	0.75
Median age [IQR]	34 [25–47]	33 [26–43]	35 [25–47]	0.66
Median age at correction (years) [IQR]	5 [2–11]	5 [1–10]	5 [3–12]	0.44
Number of patients who were paediatric at the time of the ablation	7/63 (11)	1/13 (6)	6/50 (12)	1.00
Number of sustained episodes 6 months before the procedure [IQR]	2 [1–3]	1.5 [0–2.75]	2 [1–3]	0.65
Pacemaker for sinus node dysfunction at baseline	17 (27)	1 (8)	16 (32)	0.16
Index procedure is a repeat procedure*	31 (49)	9 (69)	22 (44)	0.129
Medication				
Betablocker	16 (25)	1 (8)	15 (30)	0.16
Verapamil	1 (2)	0 (0)	1 (2)	1.00
Class 1C anti-arrhythmic drug	1 (2)	0 (0)	1 (2)	1.00
Sotalol	24 (38)	7 (54)	17 (34)	0.21
Amiodarone	19 (30)	5 (39)	14 (28)	0.51
Procedure				
Multiple intra-atrial re-entrant tachycardia morphologies	40 (63)	13 (100)	27 (68)	0,006
Haemodynamic support device	3 (5)	2 (15)	1 (2)	0.51
Remote magnetic navigation	40 (64)	8 (62)	32 (64)	1.00
Follow-up				
Median duration of follow-up (years) [IQR]	5 [2.5–7.5]	5 [3–7]	5 [1.5–8]	0.98

*In 13 of the repeat procedures, the index procedure was performed before 2006 or in another centre.
IQR = interquartile range.

Table 3. Patient characteristics CHDs

CHDs	All – 40	Multiple – 26	Extensive scar modification – 9
Tricuspid atresia	6	5	1
Ebstein	2	2	1
Transposition of the great arteries	12	7	1
Double-outlet left ventricle	5	4	1
Tetralogy of Fallot	5	3	2
Atrial septal defect/venous sinus defect	5	3	1
Concomitant atrial septal defect	5	3	1
Atrioventricular septal defect	2	1	0
Hypoplastic left ventricle	1	1	1
Cor triatriatum	1	1	0
Pulmonary stenosis, valvular or sub or supra-valvular	5	3	0
Congenital aortic stenosis, valvular and subvalvular	1	1	0
Surgery correction congenital heart defect			
Fontan	6	6	3
Mustard	10	5	1

The distribution of anomalies among all procedures, procedures with multiple intra-atrial re-entrant tachycardias (multiple) and extensive scar modification procedures.

Substrate modification versus a conventional approach

There was no significant difference in procedural success between both approaches. Extensive scar modification compared to activation mapping-based ablation was similar with regard to early and late recurrence and repeat procedures. The clinical composite endpoint after 6 and 12 months was not significantly different between the two groups (Table 7).

Repeat procedure

During a median follow-up of 5 years (interquartile range 2.5–7.5), a repeat procedure was considered necessary in 29 patients, 46% of the patients in both groups. One of the patients had multiple intra-atrial re-entrant tachycardias, and one had a single intra-atrial re-entrant tachycardia which foci could not be reached during the index ablation. Both patients had activation mapping-based ablation as an ablation strategy.

In four patients, a His bundle ablation with pacemaker implantation was needed, and in six patients cavo-tricuspid isthmus ablation after intra-atrial re-entrant tachycardia ablation was necessary to control recurrence. The underlying CHD in the patients who required cavo-tricuspid isthmus was pulmonary stenosis, double-outlet ventricle, atrial septal defect (2) and tetralogy of Fallot (2).

Discussion

To the best of our knowledge, this is the first study that analysed different ablation approaches in a difficult patient population. The

Table 4. Procedural parameters

Median (IQR)	All	Extensive scar modification	Activation mapping-based ablation	p-value
Applications number	26 [18–69]	31 [23–68]	24 [15–71]	0.43
Application time (sec)	1124 [627–2385]	1100 [851–2494]	1148 [459–2400]	0.39
Procedural duration (min)	240 [163–298]	240 [165–329]	225 [158–293]	0.73

Table 5. Procedural outcome

	All	Extensive scar modification (%)	Activation mapping-based ablation (%)	p-value
Acute success	50/63 (79)	11/13 (85)	39/50 (78)	0.719
Early recurrence	29/63 (46)	4/13 (31)	25/50 (50)	0.349
Repeat procedure	29/62* (46)	6/13 (46)	23/49* (46)	1.00

*One patient was lost to follow-up.

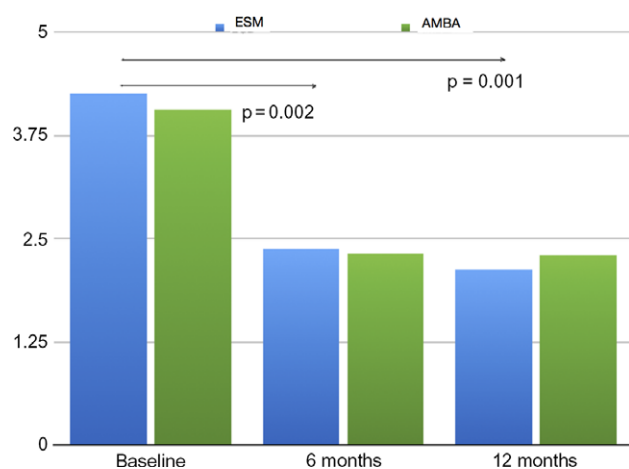


Figure 2. Clinical composite endpoint. Clinical composite endpoint in p/subject in the ESM and AMBA groups at baseline, 6 months and 12 months. AMBA=activation map-based ablation; ESM=extensive scar modification.

major finding of this study is that extensive scar modification compared to activation mapping-based ablation in patients with intra-atrial re-entrant tachycardia as a result of congenital heart surgery is not different with regards to short- and long-term outcome and procedural efficiency.

Outcome intra-atrial re-entrant tachycardia ablation

Intra-atrial re-entrant tachycardia ablation in the present study has an acute success of 78% and leads to a significant reduction in arrhythmia burden after 6 and 12 months. A high recurrence rate after ablation and even after repeat ablation in patients with intra-atrial re-entrant tachycardia is a standard in today's practice.^{4,5}

Complex atrial anatomy, markedly enlarged, scarred right atria with wall thickening and high right atrial pressure are factors associated with poor ablation outcome.⁴ In the contrary, intra-atrial re-entrant tachycardia that is cavo-tricuspid isthmus dependent is associated with a better long-term outcome after ablation. Cavo-tricuspid isthmus-dependent intra-atrial re-entrant tachycardia was excluded in the present study.

Even if intra-atrial re-entrant tachycardia episodes are not eliminated entirely by ablation, the procedure can often provide substantial improvement by reducing the frequency of episodes and eliminating the need for ongoing drug therapy¹⁰ illustrated by a significant drop in composite endpoint score after ablation. Triedman et al¹¹ reported similar results to the current study regarding the frequency of clinical events pre-ablation and post-ablation periods and found a subsequent significant decrease in clinical events.

In our study, alike other studies,¹² multiple atrial tachycardias are present in more than half of the patients referred for intra-atrial re-entrant tachycardia ablation. The clinical value of multiple arrhythmias during an ablation procedure is not completely known, also considering that one arrhythmia frequently dominates. Recurrences during the follow-up, however, frequently means the development of novel onset atrial tachyarrhythmias^{1–3} even in the absence of multiple atrial arrhythmias at baseline.

Challenges in the ablation of intra-atrial re-entrant tachycardia

The circuit of the intra-atrial re-entrant tachycardia predominantly uses a central obstacle formed by the right lateral patch or right lateral atriotomy scar¹⁴ and is less frequently formed between the scar and IVC (inferior vena cava), SVC (superior vena cava) or TV (tricuspid valve).¹³ Multiple intra-atrial re-entrant tachycardia circuits may develop due to incisional scar and obstacles in the atria.^{1–3} Rather than mapping all the intra-atrial re-entrant tachycardia individually, extensive scar modification can be applied as an alternative. In the present study, extensive scar modification was equally effective compared to activation mapping-based ablation in treating intra-atrial re-entrant tachycardia. The equal number of RF (radio frequency) applications and duration of RF between the two groups may be a representation of multiple unsuccessful ablation points in conventional ablation. A combination of extensive scar modification and activation mapping-based ablation is not performed in the present study, yet it is likely to assume it can become a successful future ablation approach, especially in case of a frequently re-occurring clinical intra-atrial re-entrant tachycardia.

Table 6. Composite endpoint – changes over time

	All	Extensive scar modification	Activation mapping-based ablation
Baseline versus 6 months (p/s)	25 improved 10 worsened 3 unchanged p = 0.002	6 improved 2 worsened 0 unchanged p = 0.139	19 improved 8 worsened 3 unchanged p = 0.006
Baseline versus 12 months (p/s)	26 improved 9 worsened 3 unchanged p = 0.001	6 improved 1 worsened 1 unchanged p = 0.073	20 improved 8 worsened 2 unchanged p = 0.04
6 months versus 12 months (p/s)	6 improved 7 worsened 25 unchanged p = 0.751	1 improved 1 worsened 6 unchanged p = 0.655	5 improved 6 worsened 19 unchanged p = 0.787

p/s = per subject.

Table 7. Composite endpoint

	Baseline (p/s)	6 months (p/s)	12 months (p/s)
ESM	4.25	2.38	2.13
AMBA	4.07	2.33	2.30
p-value	0.785	0.570	0.687

AMBA = activation map-based ablation; ESM = extensive scar modification.

Scar modification in VT ablation

Shorter procedural and fluoroscopy times are needed for a direct substrate VT (ventricular tachycardia) ablation strategy compared to ablation guided by entrainment manoeuvres.⁶ Higher scar heterogeneity is related to a higher arrhythmogenic potential of the ventricular scar,¹⁵ which rationalises scar modification in VT ablation. In a recent multi-centre randomised study that compared scar modification with clinical VT ablation in ischemic cardiomyopathy, a significantly larger freedom from VT recurrence is seen at 1 year.⁶ Moreover, a larger percentage of patients were able to discontinue anti-arrhythmic drugs after substrate ablation.

Scar modification in the atria

Possible drawbacks of scar modification approach are the lack of an established endpoint to verify individual or multiple point lesion efficacy, need for remapping to assess for complete elimination of abnormal electrograms, and ablation of bystander regions.¹⁶ In the atria, the latter might be of less importance. In VT ablation, abundant ablation leading to a reduced ventricular function is of critical importance. On the contrary, a large ablation area in a scarred atrium will not deprive cardiac output substantially. A theoretical disadvantage of extensive scar modification is a higher chance of complications with more extensive ablation. The current study does not support this potential hazard.

In extensive scar modification, there is no need for arrhythmia induction. This can be an advantage not only in case of non-inducibility, but also for haemodynamic instability. Especially, patients with a univentricular heart can become haemodynamically unstable during mapping and ablation.¹⁷ Substrate mapping would abolish the need for a haemodynamic support device.

Candidates for extensive scar modification

The recurrence risk is particularly high among Fontan patients who tend to have the largest number of intra-atrial re-entrant

tachycardia circuits, the largest atrial dimensions and most atrial hypertrophy.^{4,18} Therefore, potential candidates for extensive scar modification are patients with RA (right atrium)–PA (pulmonary artery) Fontan connections. On the contrary in Mustard patients, the cavo-tricuspid isthmus usually is the target.¹⁹ Our extensive scar modification cohort is represented by a heterogeneous group of CHD. Also surgically corrected ASD (atrial septal defect) and TOF (tetralogy of Fallot) patients, who usually have limited areas of low voltage, are represented. In the current study, invasiveness of congenital heart surgery did not correlate with the arrhythmia burden and the presence of multiple intra-atrial re-entrant tachycardias. Disease progression is a possible explanation for the presence of multiple intra-atrial re-entrant tachycardia. If multiple re-entrant circuits are present in ASD and TOF, more extensive areas of low voltage should be suspected and extensive scar modification can be a feasible approach.

Limitations of the study

The main limitation of the study is that it is a single-centre retrospective analysis with a low number of patients who underwent extensive scar modification. Not all patients with a recurrence had an electrophysiology study; therefore, we cannot be sure about the mechanism of the recurrent atrial tachycardia. In some analysis, patients were used repeatedly as unique events which adds potential bias. One should be cautious to draw conclusions on the specific congenital population referred for intra-atrial re-entrant tachycardia ablation there the analysis included a heterogeneity of anomalies. The follow-up duration in this study is representative of standard clinical practice. A single recurrence or the time to a first recurrence in this population does not represent the most important clinical outcome marker. In this article, we have made an effort to give an insight in the reduction of arrhythmia burden.

Conclusions

In the ablation treatment of intra-atrial re-entrant tachycardias in patients after congenital heart surgery, extensive scar modification illustrated similar outcome compared to a conventional mapping approach, even in the presence of multiple intra-atrial re-entrant tachycardias. Based on the outcome of this study, we do not recommend operators to change their current approach. Long-term recurrence rates remain high, so further studies are needed to develop the best treatment strategy.

Supplementary Material. To view supplementary material for this article, please visit <https://doi.org/10.1017/S1047951120001900>

Acknowledgements. We would like to thank Dustie Butteiger, Ken Lock and Lindsey Reichle for proofreading our manuscript.

Financial Support. None.

Conflict of Interest. None.

Ethical Standards. The authors assert that all procedures contributing to this work comply with the ethical standards of the relevant national guidelines on human experimentation (Central Committee on Research Involving Human Subjects) and with the Helsinki Declaration of 1975, as revised in 2008, and has been approved by the institutional committees (MEC-2016–705).

References

1. Triedman JK, Saul JP, Weindling SN, Walsh EP. Radiofrequency ablation of intra-atrial reentrant tachycardia after surgical palliation of congenital heart disease. *Circulation* 1995; 91: 707.
2. Van Hare GF, Lesh MD, Ross BA, Perry JC, Dorostkar PC. Mapping and radiofrequency ablation of intraatrial reentrant tachycardia after the senning or mustard procedure for transposition of the great arteries. *Am J Cardiol* 1996; 77: 985.
3. Kalman JM, VanHare GF, Olgin JE, Saxon LA, Stark SI, Lesh MD. Ablation of “incisional” reentrant atrial tachycardia complicating surgery for congenital heart disease. Use of entrainment to define a critical isthmus of conduction. *Circulation* 1996; 93: 502.
4. Yap SC, Harris L, Silversides CK, Downar E, Chauhan VS. Outcome of intra-atrial re-entrant tachycardia catheter ablation in adults with congenital heart disease: negative impact of age and complex atrial surgery. *J Am Coll Cardiol* 2010; 56: 1589.
5. Walsh EP, Cecchin F. Arrhythmias in adult patients with congenital heart disease. *Circulation* 2007; 115: 534–545.
6. Di Biase L, Burkhardt DJ, Lakkireddy D, et al. Ablation of stable VTs versus substrate ablation in ischemic cardiomyopathy: the VISTA randomized multicenter trial. *J Am Coll Cardiol* 2015; 66: 2872–2882.
7. Rolf S, Kircher S, Arya A, et al. Tailored atrial substrate modification based on low-voltage areas in catheter ablation of atrial fibrillation. *Circ Arrhythm Electrophysiol* 2014; 7: 825–833. doi: [10.1161/CIRCEP.113.001251](https://doi.org/10.1161/CIRCEP.113.001251).
8. Saoudi N, Cosio F, Waldo A, et al. A classification of atrial flutter and regular atrial tachycardia according to electrophysiological mechanisms and anatomical bases; a statement from a joint expert group from the working group of arrhythmias of the european society of cardiology and the north american society of pacing and electrophysiology. *Eur Heart J* 2001; 22: 1162–1182.
9. de Groot NM, Schaliij MJ, Zeppenfeld K, Blom NA, Van der Velde ET, Van der Wall EE. Voltage and activation mapping: how the recording technique affects the outcome of catheter ablation procedures in patients with congenital heart disease. *Circulation* 2003; 108: 2099–2106.
10. Triedman JK, Alexander MA, Love BA, et al. Influence of patient factors and ablative technologies on outcomes of radiofrequency ablation of intra-atrial tachycardia in patients with congenital heart disease. *J Am Coll Cardiol* 2002; 39: 1827–1835.
11. Triedman JK, Bergau DM, Saul JP, Epstein MR, Walsh EP. Efficacy of radiofrequency ablation for control of intraatrial reentrant tachycardia in patients with congenital heart disease. *JACC* 1997; 30:1032–1038.
12. Chiu SN, Lin JL, Tsai CT, et al. Radiofrequency catheter ablation of atrial tachyarrhythmias in adults with repaired congenital heart disease: constraints from multiple and new arrhythmic foci. *Acta Cardiol Sin* 2013; 29: 347356.
13. Lukac P, Pedersen AK, Mortensen PT, Jensen HK, Hjortdal V, Hansen PS. Ablation of atrial tachycardia after surgery for congenital and acquired heart disease using an electroanatomic mapping system: which circuits to expect in which substrate? *Heart Rhythm* 2005; 2: 64–72.
14. Uhm JS, Mun HS, WI J, et al. Importance of tachycardia cycle length for differentiating typical atrial flutter from scar-related in adult congenital heart disease. *PACE* 2012; 35: 1338.
15. Roes SD, Borleffs CJ, van der Geest RJ, et al. Infarct tissue heterogeneity assessed with contrast-enhanced MRI predicts spontaneous ventricular arrhythmia in patients with ischemic cardiomyopathy and implantable cardioverterdefibrillator. *Circ Cardiovasc Imaging* 2009; 2: 183–190.
16. Santangeli P, Marchlinski FE. Substrate mapping for unstable ventricular tachycardia. *Heart Rhythm* 2016; 13: 569.
17. Hendriks AA, de Vries LJ, Witsenburg M, Yap SC, Van Mieghem N, Szili-Torok T. Percutaneous ventricular assist device for circulatory support during ablation of atrial tachycardias in patients with a Fontan circulation. *Rev Esp Cardiol*. 2017; S1885–S5857: 30170–30176.
18. Nakagawa H, Shah N, Matsudaira K, et al. Characterization of reentrant circuit in macrore-entrant right atrial tachycardia after surgical repair of congenital heart disease: isolated channels between scars allow “focal” ablation. *Circulation* 2001; 103: 699–709.
19. Zrenner B, Dong J, Schreieck J, et al. Delineation of intra-atrial reentrant tachycardia circuits after Mustard operation for transposition of the great arteries using biatrial electroanatomic mapping and entrainment mapping. *J Cardiovasc Electrophysiol* 2003; 14: 1302–1310.