

# Extradural Middle Fossa Approach to a Clear Cell Meningioma in a Child

James King, Michael Cusimano, Cynthia Hawkins, Peter Dirks

Can. J. Neurol. Sci. 2009; 36: 257-261

Clear cell meningioma is an uncommon entity in children. We report on a case of a large clear cell meningioma with significant middle and posterior fossa involvement in a child, removed in total through an extradural middle fossa approach with no long term operative morbidity. The extradural middle fossa approach utilized for adult cases of trigeminal schwannoma can be effectively performed in children with meningioma in this location.

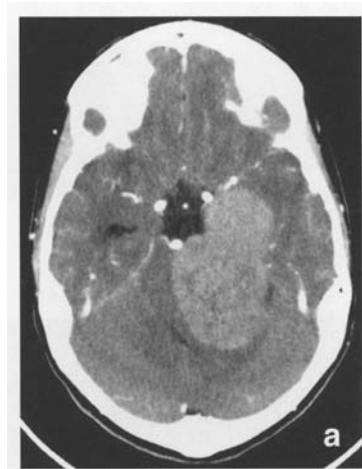
## History, examination and investigations

This previously well 11-year-old girl presented with a short history of headache and ataxia. Cranial nerve examination was normal with intact III, IV, V and VI nerve function, and there were no long tract signs although the patient did have evidence of mild left (L) dysdiadokinesis. Preoperative ophthalmologic examination revealed visual acuity of 20/20 in the right (R) eye and 20/50 in the L eye and fine horizontal nystagmus in both directions of gaze. There was no evidence of papilloedema. Formal audiologic testing was performed preoperatively and was normal bilaterally.

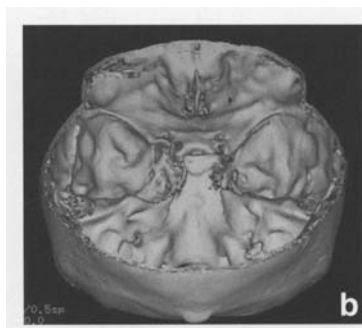A CT scan of the brain was performed (Figure 1) followed by a gadolinium enhanced MRI.(Figure 2)

## Operative detail

The patient underwent a left sided orbitozygomatic pterional craniotomy in the left semilateral position in the Sugita headrest<sup>1</sup>. BrainLab neuronavigation and intraoperative ultrasound were used. Electrophysiologic monitoring of cranial nerves III to XII, in addition to motor evoked potentials was performed throughout the case. A left frontal external ventricular drain was inserted at the commencement of the procedure through a left frontal burrhole. An extradural approach to the middle fossa floor was performed to expose the superior orbital fissure, foraminae rotundum, ovale and spinosum. The dura was opened over rotundum and ovale and thinned out fibres of V3 were separated to expose the tumour.(Figure 3) The tumour capsule was entered and tissue was sent for frozen section. Intracapsular debulking was performed with the cavitron ultrasonic aspirator (CUSA) and the arachnoid plane was developed around the tumour. The tumour was dissected free from the lateral brainstem and the large posterior fossa component was delivered through the middle fossa with arachnoidal dissection and the extended CUSA tip. Brain retraction was not utilized at all during the case. Intraoperative ultrasound was used at the completion of the procedure to



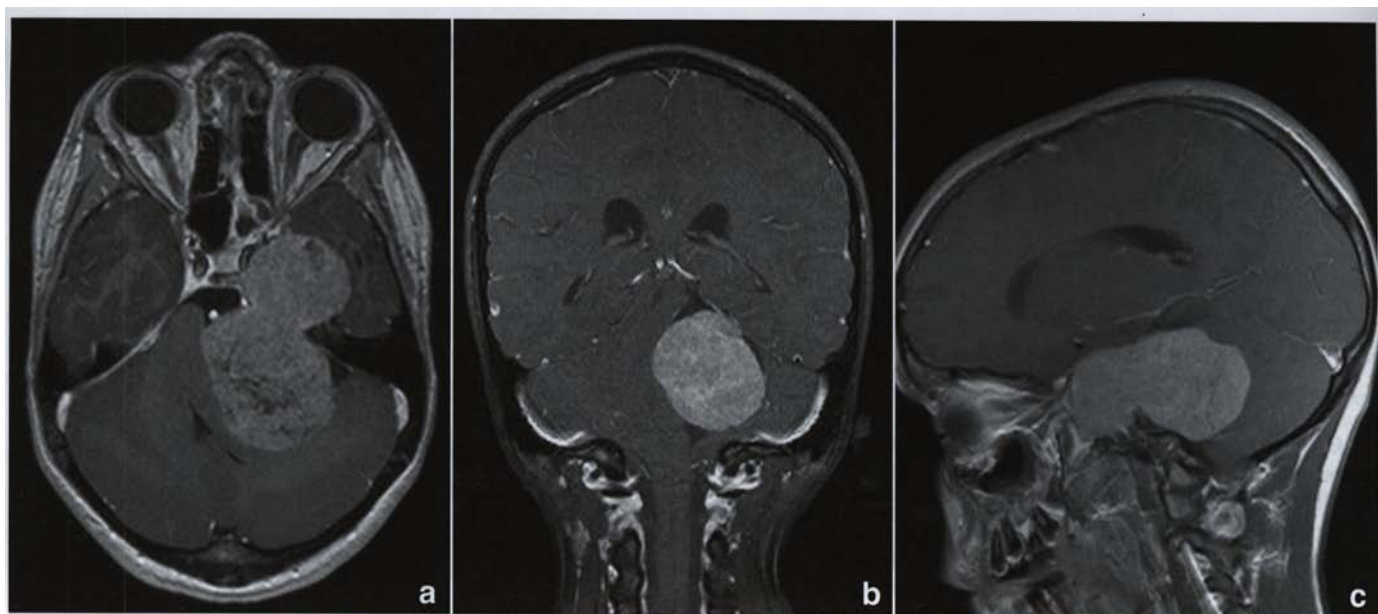
**Figure 1a:** Contrast enhanced axial CT brain of an enhancing dumbbell shaped tumour involving the middle and posterior fossae.



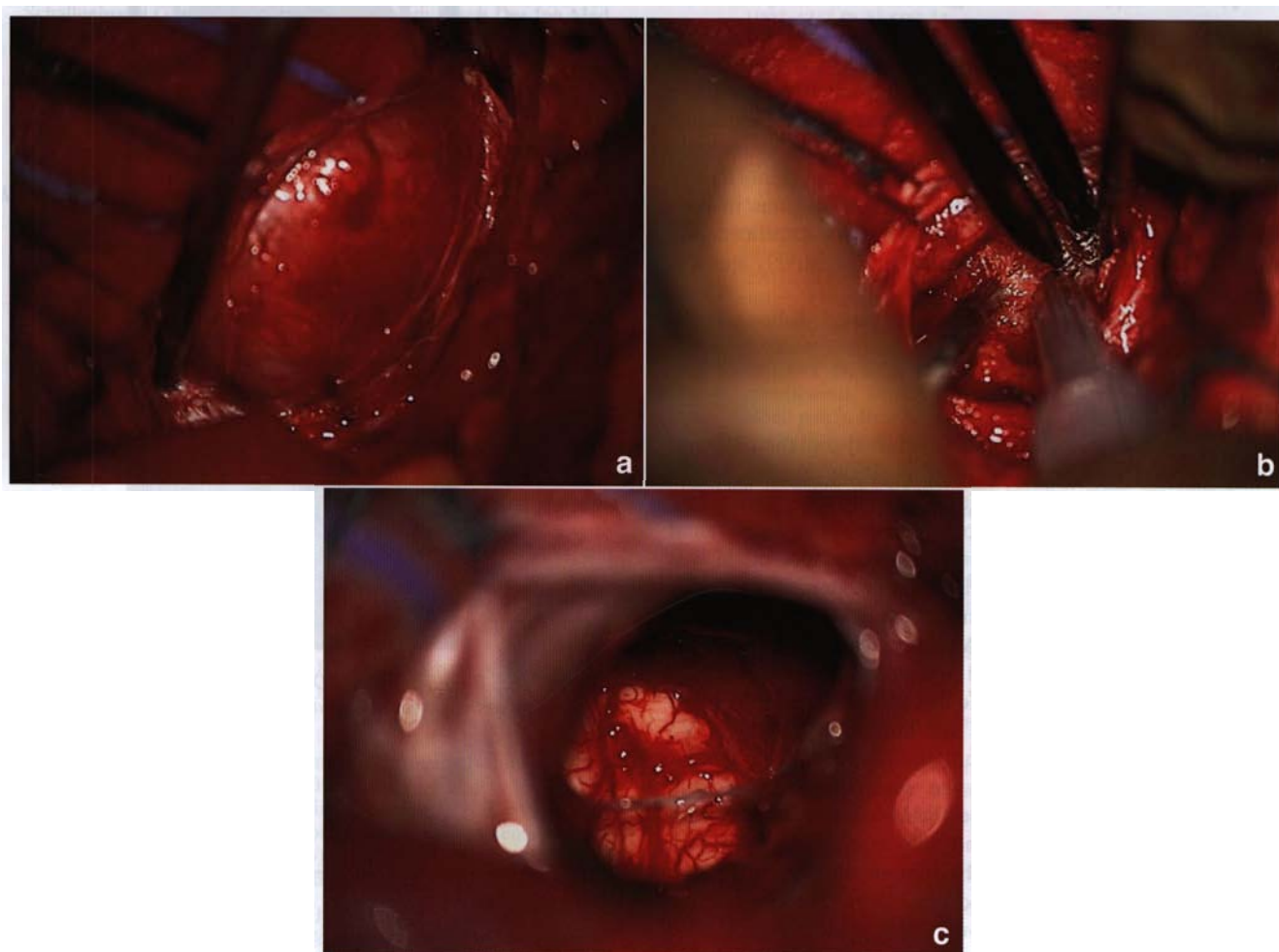
**Figure 1b:** Bone window 3D reconstruction CT showing bony remodeling in the L sphenoid and petrous apex.

From the Departments of Pathology and Neurosurgery (JK, CH, PD), The Hospital for Sick Children; Department of Neurosurgery (MC), St. Michael's Hospital, Toronto, Ontario, Canada.

RECEIVED SEPTEMBER 9, 2008. FINAL REVISIONS SUBMITTED OCTOBER 31, 2008.  
Correspondence to: James King, The Hospital for Sick Children, 555 University Avenue, Toronto, Ontario, M5G 1X8, Canada.



**Figure 2:** Gadolinium enhanced a) axial, b) coronal, c) sagittal MRI brain demonstrating imaging features mimicking trigeminal schwannoma.



**Figure 3:** a) Intraoperative image from the operative microscope on dural opening over foramen ovale, b) intralesional tumour removal, c) view of lateral brainstem after tumour removal.

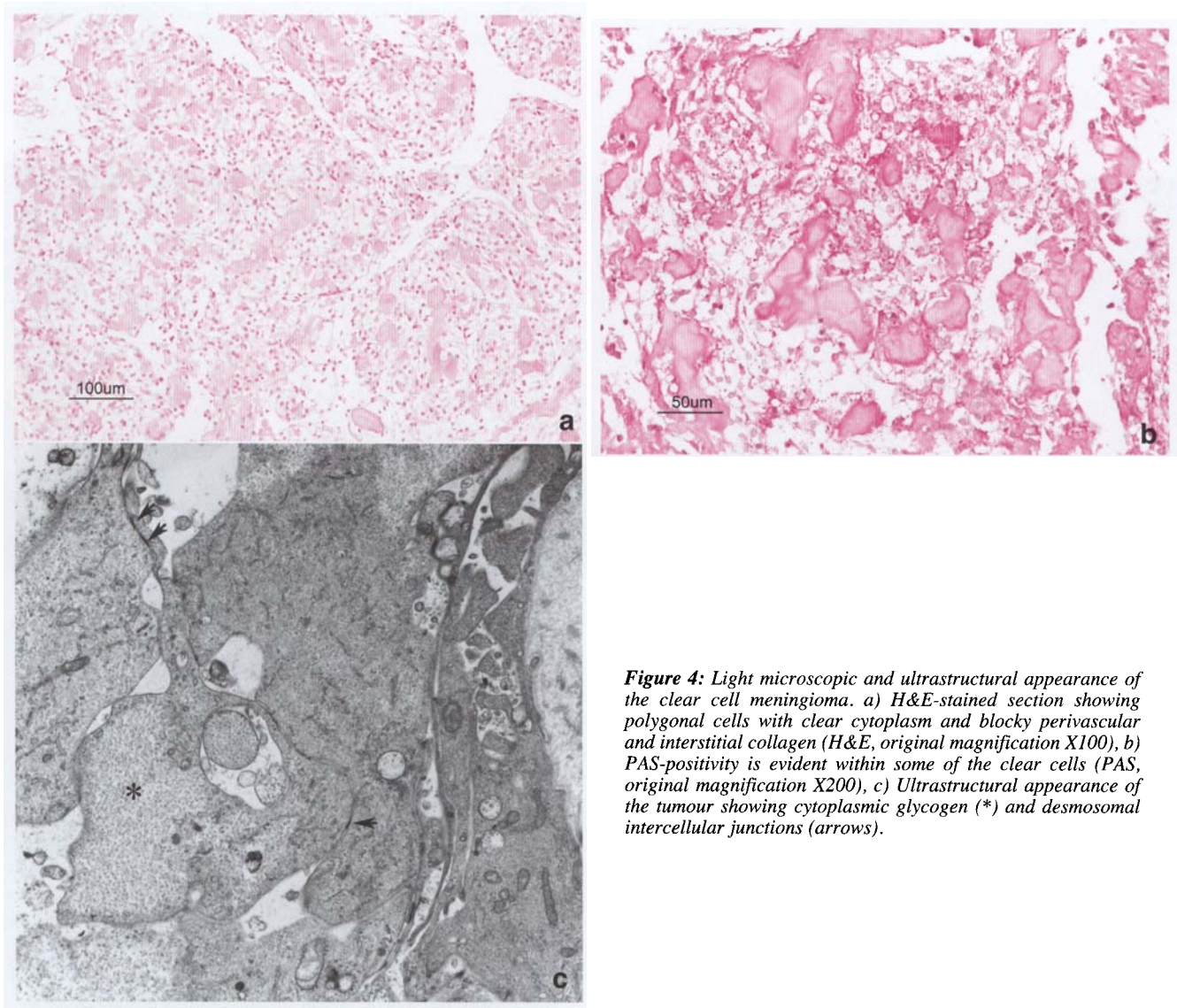


confirm gross macroscopic resection. A subgaleal Jackson Pratt drain was used in the closure. There were no significant changes from afferent somatosensory evoked potentials or efferent motor evoked responses throughout the procedure. There were no changes in the L sided motor cranial nerves monitored (III, V, VI, VII, IX, X, XI, XII) or auditory brainstem evoked responses during the case. Despite the long operative time the patient awoke immediately, was extubated and returned to the recovery room in good condition with no neurological deficit. The surgical time of 11 hours is considered reasonable for a tumour of this size in this location.

Intraoperative blood loss was estimated at 100 mls, a transfusion was not required and the serum haemoglobin was 127 g/L at the end of the procedure.

### Histological findings

The tumour was composed of irregular nests of polygonal clear cells within a background of markedly hyalinized stroma and thickened vessel walls. (Figure 4) Rare primitive whorl formations were noted. The nuclei were round and bland with no evidence of pseudoinclusions. Mitoses were not detected. Periodic acid-Schiff (PAS) and PASD confirmed the glycogen nature of the clear cytoplasmic contents. Immunohistochemistry was negative for epithelial membrane antigen (EMA) and the overall MIB-1 proliferative index was about 5%. Ultrastructurally there was massive cytoplasmic glycogen accumulation, well developed cell junctions, desmosomes and dense cytoplasmic filaments. The diagnosis was clear cell meningioma (WHO Grade 2).



**Figure 4:** Light microscopic and ultrastructural appearance of the clear cell meningioma. a) H&E-stained section showing polygonal cells with clear cytoplasm and blocky perivascular and interstitial collagen (H&E, original magnification X100), b) PAS-positivity is evident within some of the clear cells (PAS, original magnification X200), c) Ultrastructural appearance of the tumour showing cytoplasmic glycogen (\*) and desmosomal intercellular junctions (arrows).

### Post-operative Course

The patient had intact V1, V2, V3 and VI th cranial nerve function in the recovery room with an intact corneal reflex. On post-operative day three an incomplete L VIth Nerve palsy was evident and facial sensation was noted to be reduced in the V1 and V2 distributions. The patient developed a fever on day six post-operative however this resolved spontaneously without treatment and blood and urine cultures were negative. Post-operative audiology showed mild left sided conductive hearing loss thought to be due to a middle ear effusion. The patient was discharged on the ninth post-operative day.

At one month follow up the patient had evidence of partial resolution of the VIth nerve palsy with reduced sensation in V1 with a corneal abrasion. This was managed with a temporary tarsorrhaphy.

Post-operative MRI was performed six weeks after the procedure and revealed gross total resection of tumour, with residual enhancement in the trigeminal and abducens nerves on the left side. (Figure 5)

At six weeks post-operation, she had intact corneal sensation and a complete resolution of the previous 6th nerve palsy.

The clear cell variant of meningioma (CCM) has been reported in 18 pediatric cases<sup>7</sup>. The CCM is a WHO grade 2 meningioma variant and is defined by glycogen accumulation which can be demonstrated by strong periodic acid-Schiff (PAS) staining.

This subtype was first described by Scheithauer in 1990<sup>8</sup> with the most common locations being the cerebellopontine angle and lumbar region. This tumour is more common in females with a two to one ratio.

The traditional dural base seen in other subtypes of meningioma may or may not be present in CCM<sup>9</sup>. The CCM prognosis is worse than that for regular subtypes, with 11/18 reported pediatric cases having recurrence with a median of five months<sup>7</sup>, with two patients experiencing central nervous system metastasis. Complete surgical removal remains the treatment of choice with close clinical and radiologic surveillance post-operatively. Adjuvant therapy is reserved for incomplete resection or upon evidence of recurrence following gross total resection.

Our case shares a number of features previously reported, including female sex, occurrence in the cerebellopontine angle with no apparent dural attachment radiologically or at surgery. Novel aspects of this case are the large size, the dual fossae

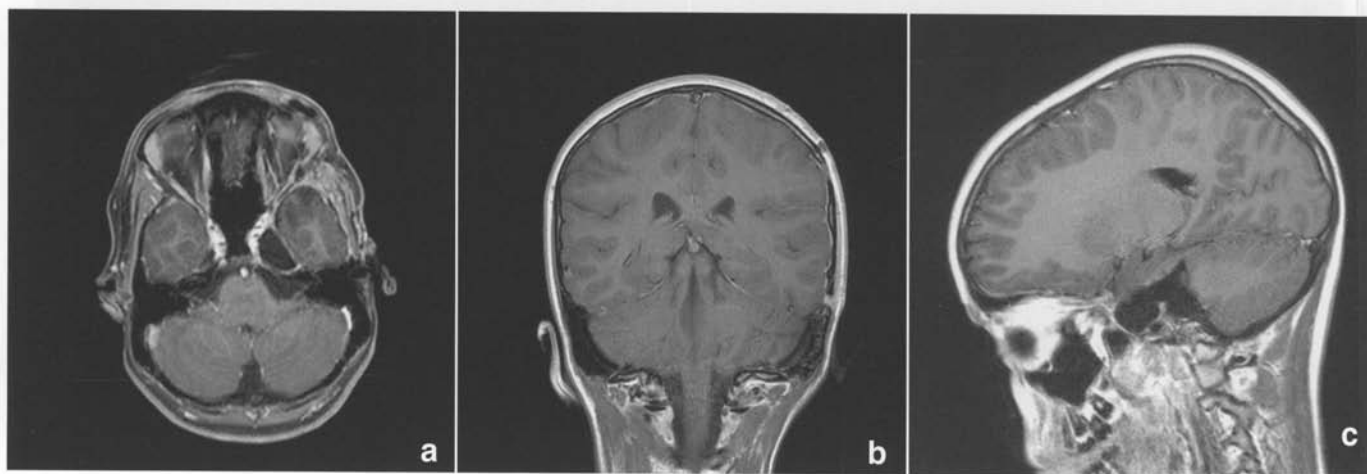


Figure 5: Post operative a) axial, b) coronal, c) sagittal MRI with gadolinium showing complete resection of tumour.

### DISCUSSION

Meningioma is a rare tumour in children and when encountered may be seen in the setting of neurofibromatosis type 2 or following radiotherapy at a young age. Only 0.44% of paediatric age tumours are meningiomas. Paediatric meningiomas exhibit a slight male predominance, are often located in atypical sites (intraventricular) and the proportion of atypical or anaplastic tumours is increased<sup>2,3</sup>. Meningiomas arising from cranial nerves are unusual in the pediatric population with only three case reports in the literature<sup>4-6</sup>.

location more consistent with trigeminal schwannoma on imaging, and the single surgical approach to the tumour with no long term cranial nerve or other morbidity.

Adult reports of surgery for trigeminal schwannoma involving both the middle and posterior fossae suggest that a single skull base approach utilizing an orbito zygomatic craniotomy and extradurotransduranstrigeminal approach can be performed successfully with a high rate of complete excision and lower cranial nerve morbidity<sup>10-13</sup>.

We report successful use of this approach in a child with clear cell meningioma. The origin of this tumour is thought to be the

arachnoid around the trigeminal nerve, in or around the site of entry of the nerve into Meckel's dural cave. As such the surgical approach is similar to that for trigeminal schwannoma, with an extradural approach favoured to minimize surgical morbidity in a single operation without temporal lobe retraction, venous injury or the need to drill off the petrous apex<sup>13</sup>. The authors would like to point out that this approach may not be feasible if the tumour consistency and vascularity are unfavourable, in which case a combined approach would be required. Additionally, the use of the extended tip (transphenoidal) CUSA was critical to the success of this procedure.

Clear cell meningioma is a rare tumour in children. Substantial involvement of the middle and posterior fossae potentially would mandate two discrete approaches to the tumour either at the same sitting or in a staged procedure. Performing the tumour removal from the middle fossa approach avoids the necessity for a second craniotomy / procedure and the concomitant potential morbidity.

#### REFERENCES

1. van Furth WR, Agur AM, Woolridge N, Cusimano MD. The orbitozygomatic approach. *Neurosurgery*. 2006;58(1 Suppl): ONS103-7; discussion ONS-7.
2. Arivazhagan A, Devi BI, Kolluri SV, Abraham RG, Sampath S, Chandramouli BA. Pediatric intracranial meningiomas--do they differ from their counterparts in adults? *Pediatr Neurosurg*. 2008;44(1):43-8.
3. Greene S, Nair N, Ojemann JG, Ellenbogen RG, Avellino AM. Meningiomas in children. *Pediatr Neurosurg*. 2008;44(1):9-13.
4. Liechty P, Tubbs RS, Loukas M, Blount JP, Wellons JC, Acakpo-Satchiviet L, et al. Spinal accessory nerve meningioma in a paediatric patient: case report. *Folia Neuropathol*. 2007;4(1): 23-5.
5. Obeng K, Rumboldt Z, Tuite G, Welsh CT, Patel S, Spampinato MV. Atypical cystic meningioma of the trigeminal nerve in a pediatric patient. *AJNR Am J Neuroradiol*. 2008;29(2):398-9.
6. Spittaler PJ, Johnston IH. Multiple extracranial meningiomas in a child. *Childs Nerv Syst*. 1992;8(3):144-6.
7. Oviedo A, Pang D, Zovickian J, Smith M. Clear cell meningioma: case report and review of the literature. *Pediatr Dev Pathol*. 2005;8(3):386-90.
8. Scheithauer BW. Tumors of the meninges: proposed modifications of the World Health Organization classification. *Acta Neuropathol*. 1990;80(4):343-54.
9. Zorludemir S, Scheithauer BW, Hirose T, Van Houten C, Miller G, Meyer FB. Clear cell meningioma. A clinicopathologic study of a potentially aggressive variant of meningioma. *Am J Surg Pathol*. 1995;19(5):493-505.
10. Al-Mefty O, Ayoubi S, Gaber E. Trigeminal schwannomas: removal of dumbbell-shaped tumors through the expanded Meckel cave and outcomes of cranial nerve function. *J Neurosurg*. 2002;96(3):453-63.
11. Dolenc VV. Frontotemporal epidural approach to trigeminal neurinomas. *Acta Neurochir (Wien)*. 1994;130(1-4):55-65.
12. Goel A, Muzumdar D, Raman C. Trigeminal neuroma: analysis of surgical experience with 73 cases. *Neurosurgery*. 2003;52(4): 783-90; discussion 90.
13. Zhou LF, Mao Y, Zhang R. Surgical treatment of dumbbell-shaped neurinomas: report of an experience with 57 cases in a single hospital. *Surg Neurol*. 2007;68(6):594-602.