
Ultrasound Determination of Chorionicity in Twin Pregnancy: Accuracy and Operator Experience

Roland G. L. Devlieger, Thomas Demeyere, Jan A. Deprest, Dominique Van Schoubroeck, Ingrid Witters, Dirk Timmerman, Myriam Hanssens

Department of Obstetrics and Gynecology, University Hospital Gasthuisberg, Katholieke Universiteit Leuven, Belgium.

To evaluate the accuracy of ultrasound in early detection of chorionicity and amnionicity in twin pregnancies and evaluate the role of operator-experience, a prospective follow up of 87 consecutive twin pregnancies was performed. Chorionicity and amnionicity were determined by 17 different observers, divided in 2 groups on the basis of their experience, using a composite of US markers at the first US examination confirming a viable intrauterine twin pregnancy. Accuracy of prediction was determined for both groups by comparison with postnatal pathology. From the 87 pregnancies examined at 10.1 (minimum 5.5 weeks, maximum 26.0) weeks of gestation, pathology was available in 82 cases and a correct prediction of chorionicity was made in all but two cases, both being diagnosed as monochorionic while dichorionic by observers belonging to the more experienced group. No monochorionic pregnancy was missed and amnionicity was correctly diagnosed in all cases, including two monoamniotic twins. We conclude that use of a composite of ultrasound markers for early detection of chorionicity and amnionicity is reliable in a clinical setting where physicians with a variable degree of experience perform ultrasound examination.

Monochorionic (MC) twins have an incidence of only 1 to 3 in 1000 pregnancies, but account for 50 % of the mortality in twin pregnancies (Sebire et al., 1997). Early detection of MC twinning allows the organization of appropriate follow-up and early detection of specific complications, such as twin-to-twin transfusion syndrome (TTTS) for which antenatal treatment options are now available (Allen et al., 2000; Deprest et al., 2000). The importance of an accurate diagnosis of chorionicity has therefore recently been stressed by leading authors in the field (Bajoria & Kingdom, 1997; Sepulveda, 1997; Taylor & Fisk, 2000).

Whereas certainty about chorionicity can only be obtained postnatally by pathological examination of the fetal membranes (Riethmuller et al., 1999), antenatal ultrasound (US) can be used for prenatal determination. The feasibility of antenatal diagnosis of chorionicity by US has been evaluated extensively (D'Alton & Dudley, 1989; Finberg, 1992; Hill et al., 1996; Kurtz et al., 1992; Montegudo, 1998; Scardo et al., 1995; Sepulveda et al., 1996; Townsend et al., 1988; Vayssiere et al., 1996; Winn et al., 1989), but the accuracy in clinical practice is less well documented. Indeed, in most studies the US examinations were performed by a single observer or by a small group of

very experienced ultrasonographers (Scardo et al., 1995). Other studies focused on a single marker for the detection of chorionicity (Townsend et al., 1988; Vayssiere et al., 1996) or did not include pathological confirmation of the diagnosis (Sepulveda et al., 1996). Recently, a possible role of lack of operator experience has been suggested as a possible factor in misdiagnosis of chorionicity in multiple pregnancies (Ecker et al., 1998). The present study was designed to evaluate the accuracy of the use of a composite of the most commonly suggested US markers for detection of chorionicity and amnionicity in a clinical setting where US examination is performed by physicians with different levels of experience.

Material and Method

The study was performed at the University Hospital "Gasthuisberg" in Leuven, Belgium from 1997 until 1999. In this teaching hospital, both residents and consultants perform routine US examination during pregnancy. Residents in training are usually graded as "juniors" or "seniors" depending on the duration (less or more than three years respectively) of their postgraduate training in Obstetrics and Gynecology. Similarly, ultrasonographers in this study were divided in an "experienced" and "less experienced" group, depending on whether they have been performing obstetric US for more or less than 3 years. At the beginning of each training period of six months, the main investigator informed the new residents about the study-protocol and updated them on the US characteristics of MC and DC twins. Patients were enrolled in the study at the time of the first US examination confirming an intrauterine twin pregnancy with detectable fetal heartbeats. Examinations were carried out on high resolution US equipment (Toshiba SSH 140A, Toshiba, Tokyo or Acuson Sequoia, Mountain view, California) with curvilinear transducers (frequencies ranging from 3.5 to 5 MHz). The trans-abdominal or

Address for Correspondence: Roland Devlieger, MD, Department of Obstetrics and Gynecology, University Hospital Gasthuisberg, Herestraat 49, B-3000 Leuven, Belgium. Email: roland.devlieger@uz.kuleuven.ac.be

trans-vaginal route was used as preferred by the physician or indicated by gestational age or patient characteristics.

After US examination, a study form was completed by the operator reporting on gestational age, number of gestational sacs, number of yolk sacs and fetuses, number of placentas, presence and thickness of an intertwin membrane and presence of the “lambda” (Finberg, 1992) or “twin peak” (Sepulveda et al., 1996) sign. Based on these a prediction of chorionicity was made. Pictures were kept for retrospective analysis. At delivery, the placenta and membranes were collected and examined by an experienced pathologist to determine chorionicity and amnionicity.

Results

During the study period, 87 twin pregnancies were enrolled and evaluated by 17 different physicians, 8 belonging to the less experienced group, and 9 to the more experienced group. The mean gestational age at

observation was 10.1 weeks (minimum 5.5 weeks, maximum 26.0 weeks). Three patients (3.4%) were lost for follow-up and 2 (2.3 %) miscarried. These pregnancies were excluded from further analysis. Thirty-five (42.7%) of the 82 remaining pregnancies studied resulted from in vitro fertilization, and 8 (9.8%) others from ovarian stimulation without IVF.

Pathologic evaluation of the placenta and fetal membranes at delivery was available in all 82 remaining pregnancies. The number and percentages of correct estimations for each type of placentation are displayed in Table 1, showing no significant differences in proportions of accurate diagnosis between the two groups of operators. Frequencies of US findings, sensitivity, specificity, positive and negative predictive values for the different US markers are summarized in Tables 2 and 3.

A retrospective analysis of the ultrasound pictures in the two cases where a wrong diagnosis was made showed a clear “lambda sign” at 9.5 weeks of gestation in the first case (Figure 1). The observer measured the thickness of the intertwin membrane (3 mm), but misinterpreted these findings and diagnosed a MCDA pregnancy. Pathology of the intertwin-membrane in this case revealed a DC pregnancy. The second error was a similar case of histologically proven DC twin pregnancy misdiagnosed as being MC at 10.7 weeks of gestational age. No twin peak sign was reported in this case and the intertwin septum was reported to be 1.0 mm.

Table 1
Number (Percentages) of Correct Diagnosis for Each Placentation Type in the Two Groups of Operators

Operator Group	Pathological diagnosis		
	DCDA	MCDA	MCMA
“Experienced”	38/40 (95)	3/3 (100)	2/2 (100)
“Less Experienced”	32/32 (100)	5/5 (100)	0
<i>P</i>	NS	NS	NS

Note: NS means not significant

Table 2
Frequency of Ultrasound Findings Markers in the Different Histological Placenta Types

	Total (%)	DCDA (%)	MCDA (%)	MCMA (%)
Patients	82	72	8	2
Septum measured	76 / 82 (92.7)	69 / 72 (95.8)	7 / 8 (87.5)	0 / 2 (0)
Septum ≥ 2mm	65 / 76 (85.5)	65 / 69 (94.0)	0 / 7 (0)	0 / 2 (0)
Septum < 2 mm	11 / 76 (14.5)	4 / 69 (5.8)	7 / 7 (100)	0 / 2 (0)
Comment Lambda sign	82 / 82 (100)	72 / 72 (100)	8 / 8 (100)	2 / 2 (100)
Lambda sign present	31 / 82 (37.8)	31 / 72 (43.0)	0 / 8 (0)	0 / 2 (0)
Comment placenta	69 / 82 (84.1)	61 / 72 (84.7)	6 / 8 (75.0)	2 / 2 (100)
Single placenta	18 / 69 (26.1)	8 / 61 (13.1)	6 / 6 (100)	2 / 2 (100)

Table 3
Sensitivity, Specificity and Positive (PPV) and Negative (NPV) Predictive Value of the Different US Markers

	Sensitivity %	Specificity %	PPV %	NPV %
Lambda sign in DC twinning	43.6	100	100	19.6
Intertwin membrane < 2 mm in MC twinning	100	94.2	63.6	100
Intertwin membrane > 2mm in DC twinning	94.2	100	100	63.6
Single placenta in MC twinning	100	83.6	44.4	100

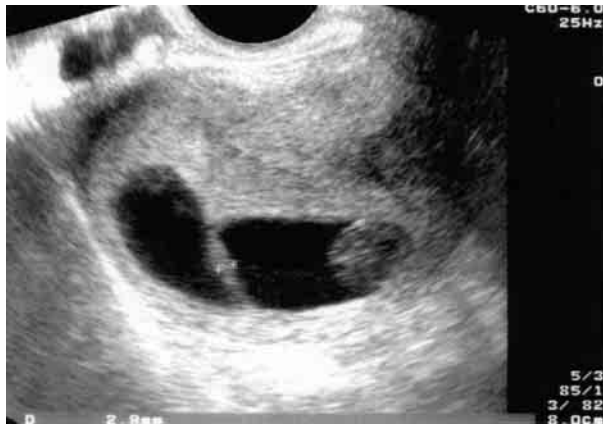

Figure 1.

Ultrasound picture showing the placento-membranous interface in a DC twin pregnancy at 9.5 weeks gestation showing a "lambda"-sign and a thick (3mm) intertwin septum. This pregnancy was misdiagnosed as being MC by an observer belonging to the "more experienced" group.

Discussion

While early antenatal US determination of chorionicity in multiple gestations is feasible, it is done far from optimal in clinical practice, due to a combination of factors: Firstly, physicians' unawareness of the importance of chorionicity on the fate of the fetus and secondly, insufficient knowledge on the US characteristics of MC and DC twinning (Sepulveda, 1997). Despite its importance and the need for a standardized approach, the ideal timing and method for accurate diagnosis of chorionicity in multiple pregnancies remains a subject of debate.

Since Finberg (1992) described the "twin peak" or "lambda" sign, the triangular projection of chorion between adjacent amnions at the interface of membranes and placenta in the case of dichorionicity, several authors have used it as a marker of dichorionic twinning (Sepulveda et al., 1996). In this series, the presence of a lambda sign was specific (PPV 100%) for DC twins. It was, however reported in only 37.8 % of DC twins. This is lower than the incidence found in other studies (Sepulveda et al., 1996), and may be related to the relatively early gestational age of studied pregnancies (Figure 2). Indeed, in DC gestations before 7 weeks of gestation, separate gestational sacs will generally be seen, surrounded by separated or fused trophoblastic rings rather than a typical lambda sign.

The intertwin membrane consists of two amnion layers in the case of mono chorionicity, four in the case of dichorionicity and is therefore substantially thicker on pathological examination. High definition US enables in some cases to count the number of separate layers (Vayssiere et al., 1996), but most authors use the thickness or the aspect of the intertwin membrane, using a cut-off point of 2 mm to differentiate MC and DC pregnancies (Townsend et al., 1988). Stagiannis et al. (1995) elegantly demonstrated possible pitfalls using this method (Cheung et al., 1990). In our series, all MC twins had an intertwin membrane of less than 2 mm (Figure 2). However, this was

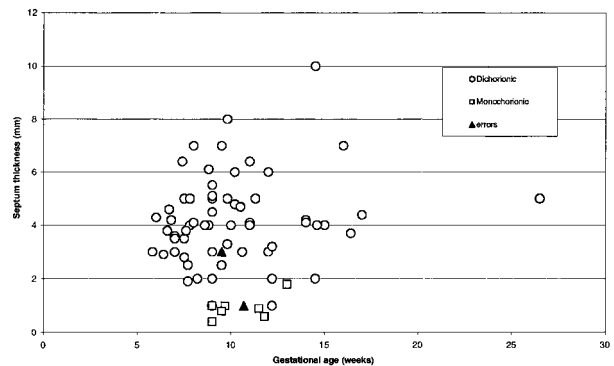


Figure 2.

Thickness (mm) of the intertwin membrane related to gestational age in correctly diagnosed MC (□) and DC (○) pregnancies. The two misdiagnoses are shown as (▲). Note: In the two cases indicated by a black arrow, retrospection of the pictures showed that the measurement was not performed at the thinnest part of the dividing membrane.

also found in some DC twins and in fact probably the cause of one of the misdiagnoses.

While the presence of two separated placentas excludes the presence of a MC pregnancy, the differentiation between fused DC placentas and a single MC placenta is not always possible on US. This resulted in a low PPV (44.4%) for single placenta and MC twinning in our series, comparable to the results found by others (Efrat et al., 1999).

The sex of the fetuses can be used in second and third trimester of pregnancy, but offers limited information. Indeed, different sex twins are dizygotic and thus DC. Most of the same sex twins are however DC as well. First trimester US gender determination is a domain of intensive research, but has not been evaluated in multiple pregnancies yet (Stagiannis et al., 1995). In our series, the gender of the fetuses was only reported in a single case seen at 26.0 weeks of gestation. The sexes were different and the correct diagnosis of DC twinning was made.

Analysis of the two misdiagnoses, surprisingly both in the "experienced" group, illustrates interesting pitfalls in the detection of chorionicity in twin pregnancies and (obstetric) ultrasound in general. In the first case the observer was a consultant, active mostly in clinical obstetrics who had been performing obstetric ultrasound for many years but only occasionally, lately. Unless it has been a simple miswriting, it can be supposed that most of the "senior" ultrasonographers are possibly less well updated on the possibilities of early determination of chorionicity, a fact that has been stressed only in recent years. A resident training for at least three years made the observations in the second wrong case. Retrospection showed suboptimal picture quality and only a transabdominal US examination was performed. In this case, the patient was obese and refused transvaginal scanning. This case illustrates the importance of proper image focussing and the use of transvaginal scanning when transabdominal visualization is poor, which was suggested by others in this context (Malinowski, 1997).

The study population included 10/82 (12,2%) of mono chorionic twins. This is lower than the reported figures in a

general population of pregnant woman and represents the relative importance of pregnancies resulting from assisted reproduction. It is known that the number of multiple pregnancies, and the proportion of dizygotic and thus DC twins increase with these techniques (Loos et al., 1998). However, it represents the general population that residents in training hospitals are exposed to and in view of the objectives of this study, does not represent a significant population bias. However, while we reported no errors in the detection of monochorionic and monoamniotic pregnancies, the relatively low numbers in these groups, result in broad confidence intervals for accuracy of detection using the studied criteria, while this is not the case for the group of dichorionic twins.

In summary, these data show that early detection of chorionicity with US can be performed with a high level of accuracy by both experienced and less experienced ultrasonographers after a basic introduction on specific US characteristics of MC and DC twins. In the “diagnostic cascade” (Sepulveda, 1997) leading to a correct diagnosis of chorionicity, the twin peak sign and the thickness of the intertwin membrane seem superior to the other markers, at least at the studied gestational age. Determination of chorionicity should routinely be performed in all multiple pregnancies. Timing between 11 and 14 weeks gestation allows the combination with measurement of nuchal translucency, a possible early marker for TTTS, the most common and treatable complication related to chorionicity (Sebire, 2000).

References

- Allen, M. H., Gabelis, N. S., Bornick, P. W., & Quintero, R. A. (2000). Minimally invasive treatment of twin-to-twin transfusion syndrome. *AORN Journal*, *71*, 796–810.
- Bajoria, R., & Kingdom, J. (1997). The case for routine determination of chorionicity and zygosity in multiple pregnancy. *Prenatal Diagnosis*, *17*, 1207–1225.
- Cheung, A., Wan, M., & Collins, R. J. (1990). Differentiation of monochorionic twin placentas by antenatal ultrasonic evaluation. *The Australian & New Zealand Journal of Obstetrics and Gynecology*, *30*, 134–136.
- D’Alton, M. E., & Dudley, D. K. (1989). The ultrasonographic prediction of chorionicity in twin gestation. *American Journal of Obstetrics and Gynecology*, *160*, 557–561.
- Deprest, J. A., Audibert, F., Van Schoubroeck, D., Hecher, K., & Mahieu-Caputo, D. (2000). Bipolar coagulation of the umbilical cord in complicated monochorionic twin pregnancy. *American Journal of Obstetrics and Gynecology*, *182*, 340–345.
- Ecker, J. L., Filly, R. A., Zaloudek, C., Wright, R. R., Drexler, B., & Goldberg, J. D. (1998). Chorionicity inaccurately predicted by early ultrasound: A case report. *Prenatal Diagnosis*, *18*, 485–489.
- Efrat, Z., Akinfenwa, O. O., & Nicolaides, K. H. (1999). First-trimester determination of fetal gender by ultrasound. *Ultrasound in Obstetrics & Gynecology*, *13*(5), 305–307.
- Finberg, H. J. (1992). The “twin peak” sign: Reliable evidence of dichorionic twinning. *Journal of Ultrasound in Medicine*, *11*, 571–577.
- Hill, L. M., Chenevey, P., Hecker, J., & Martin, J. G. (1996). Sonographic determination of first trimester twin chorionicity and amnionicity. *Journal of Clinical Ultrasound*, *24*, 305–308.
- Kurtz, A. B., Wapner, R. J., Mata, J., Johnson, A., & Morgan, P. (1992). Twin pregnancies: Accuracy of first-trimester abdominal US in predicting chorionicity and amnionicity. *Radiology*, *185*, 759–762.
- Loos, R., Derom, C., Vlietinck, R., & Derom, R. (1998). The East Flanders Prospective Twin Survey (Belgium): A population-based register. *Twin Research*, *1*, 167–175.
- Malinowski, W. (1997). Very early and simple determination of chorionic and amniotic type in twin gestations by high-frequency transvaginal ultrasonography. *Acta Geneticae Medicae et Gemellologiae (Roma.)*, *46*, 167–173.
- Monteagudo, A. (1998). Sonographic assessment of chorionicity and amnionicity in twin pregnancies: How, when and why? *Croatian Medical Journal*, *39*, 191–196.
- Riethmuller, D., Liegeon, B., Delicourt, C., Arbez-Gindre, F., Carbillet, J. P., Schaal, J. P., & Maillat, R. (1999). [Value of histologic examination of the interamniotic membrane in the twin placenta for confirmation of chorionicity diagnosis]. *Journal de Gynécologie, Obstétrique et Biologie de la Reproduction (Paris)*, *28*, 817–819.
- Scardo, J. A., Ellings, J. M., & Newman, R. B. (1995). Prospective determination of chorionicity, amnionicity, and zygosity in twin gestations. *American Journal of Obstetrics and Gynecology*, *173*, 1376–1380.
- Sebire, N. J., Snijders, R. J., Hughes, K., Sepulveda, W., & Nicolaides, K. H. (1997). The hidden mortality of mono-chorionic twin pregnancies. *British Journal of Obstetrics and Gynaecology*, *104*, 1203–1207.
- Sebire, N. J., Souka, A., Skentou, H., Geerts, L., & Nicolaides, K. H. (2000). Early prediction of severe twin-to-twin transfusion syndrome. *Human Reproduction*, *15*, 2008–2010.
- Sepulveda, W. (1997). Chorionicity determination in twin pregnancies: Double trouble [editorial]. *Ultrasound in Obstetrics & Gynecology*, *10*, 79–81.
- Sepulveda, W., Sebire, N. J., Hughes, K., Odibo, A., & Nicolaides, K. H. (1996). The lambda sign at 10–14 weeks of gestation as a predictor of chorionicity in twin pregnancies. *Ultrasound in Obstetrics & Gynecology*, *7*, 421–423.
- Stagiannis, K. D., Sepulveda, W., Southwell, D., Price, D. A., & Fisk, N. M. (1995). Ultrasonographic measurement of the dividing membrane in twin pregnancy during the second and third trimesters: A reproducibility study. *American Journal of Obstetrics and Gynecology*, *173*(5), 1546–1550.
- Taylor, M. J., & Fisk, N. M. (2000). Prenatal diagnosis in multiple pregnancy. *Baillieres Best Practice in Research and Clinical Obstetrics & Gynaecology*, *14*, 663–675.
- Townsend, R. R., Simpson, G. F., & Filly, R. A. (1988). Membrane thickness in ultrasound prediction of chorionicity of twin gestations. *Journal of Ultrasound in Medicine*, *7*, 327–332.
- Vayssiere, C. F., Heim, N., Camus, E. P., Hillion, Y. E., & Nisand, I. F. (1996). Determination of chorionicity in twin gestations by high-frequency abdominal ultrasonography: Counting the layers of the dividing membrane. *American Journal of Obstetrics and Gynecology*, *175*, 1529–1533.
- Winn, H. N., Gabrielli, S., Reece, E. A., Roberts, J. A., Salafia, C., & Hobbins, J. C. (1989). Ultrasonographic criteria for the prenatal diagnosis of placental chorionicity in twin gestations. *American Journal of Obstetrics and Gynecology*, *161*, 1540–1542.