



Neuroimaging Highlight

Visual Fields and Ocular Coherence Tomography Predict Location of the Intracranial Lesion

Marko M. Popovic  and Edward Margolin 

Department of Ophthalmology and Vision Science, University of Toronto, Toronto, ON, Canada

Keywords: Central nervous system malformations; Neuro-ophthalmology; Optical imaging

A 19-year-old woman presented to the neuro-ophthalmology clinic with a 3-month history of headaches and decreased vision in the right eye (RE). Visual acuity was 20/30 in the RE and 20/20 in the left eye (LE). There was right relative afferent pupillary defect. Ophthalmoscopy demonstrated subtle band atrophy of

right optic nerve and was normal on the left. Humphrey 24-2 visual field (VF) testing revealed left homonymous hemianopia as well as nerve fiber layer defect in the RE (Figure 1A). Ocular coherence tomography (OCT) of the ganglion cell-inner plexiform layer (GC-IPL) demonstrated generalized thinning in RE and nasal loss

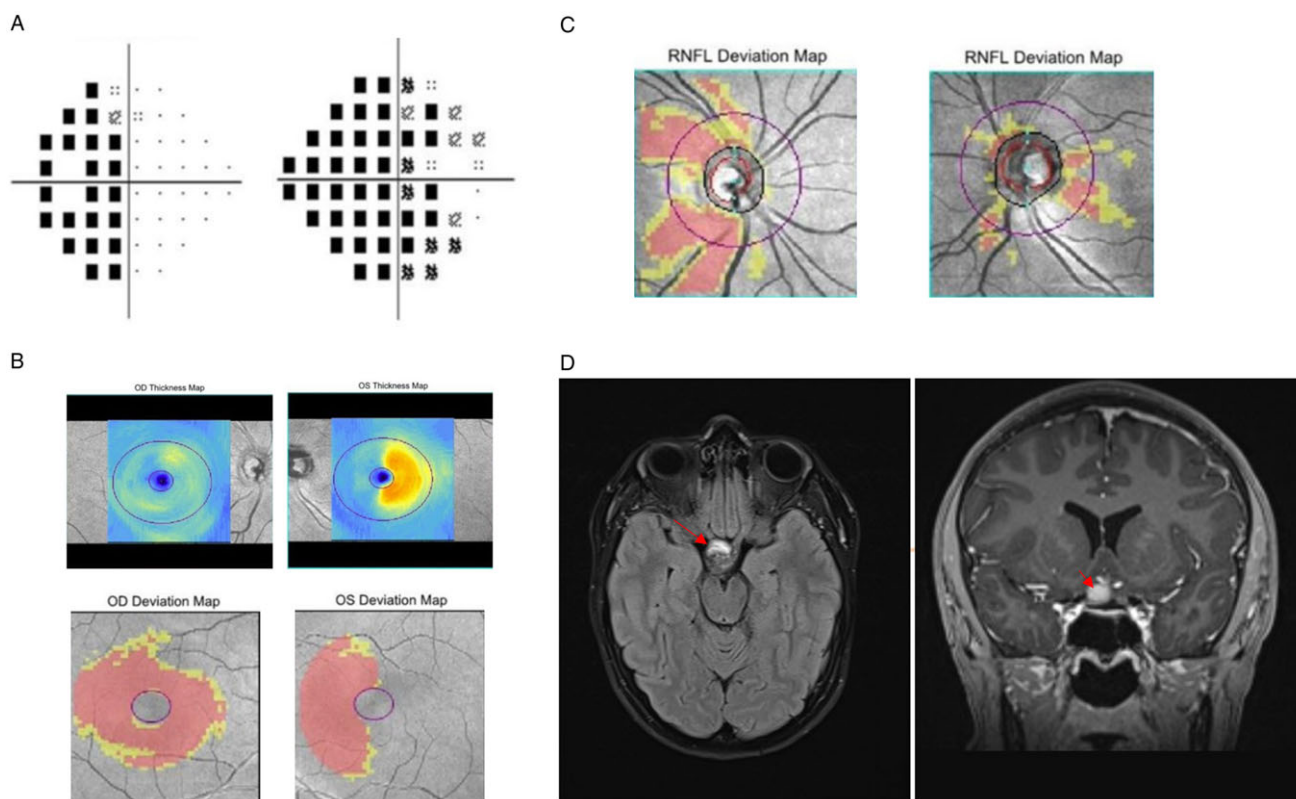


Figure 1: (A) 24-2 Humphrey visual field demonstrating central scotoma in right eye and left homonymous defect in left eye. (B) Ocular coherence tomography of the ganglion cell-inner plexiform layer demonstrating diffuse thinning in right eye and nasal thinning in left eye, consistent with junctional scotoma. (C) Optical coherence tomography of the retinal nerve fiber layer demonstrating band atrophy in right eye and hourglass atrophy in left eye. (D) Coronal T1 post-contrast sequence demonstrating compression of pre-chiasmatic right optic nerve (arrow, right) and axial FLAIR sequence demonstrating a lesion compressing right optic tract (arrow, left).

Corresponding author: Edward Margolin, MD, FRCSC, Dipl. ABO, Associate Professor, Department of Ophthalmology and Visual Sciences, Department of Medicine, Division of Neurology, Chief of Service, Neuro-Ophthalmology, University of Toronto, 801 Eglinton Ave West, Suite 301, Toronto, ON M5N 1E3, Canada. E-mail: edward.margolin@uhn.ca

Cite this article: Popovic MM and Margolin E. (2023) Visual Fields and Ocular Coherence Tomography Predict Location of the Intracranial Lesion. *The Canadian Journal of Neurological Sciences* 50: 626–627, <https://doi.org/10.1017/cjn.2022.263>

© The Author(s), 2022. Published by Cambridge University Press on behalf of Canadian Neurological Sciences Federation. This is an Open Access article, distributed under the terms of the Creative Commons Attribution licence (<http://creativecommons.org/licenses/by/4.0/>), which permits unrestricted re-use, distribution and reproduction, provided the original article is properly cited.

in LE, consistent with a junctional scotoma (Figure 1B). Junctional scotoma results from the lesion affecting pre-chiasmatic optic nerve, thus producing generalized depression on ipsilateral VF, and crossing nasal fibers from the contralateral eye, which results in temporal defect on VF in the fellow eye and correspondingly nasal thinning on GC-IPL. Peripapillary OCT demonstrated hour-glass atrophy in the RE and bowtie atrophy in the LE, suggesting a lesion in the right optic tract (Figure 1C): optic tract contains axons from the temporal retina from the ipsilateral eye, which enter optic nerve superiorly and inferiorly resulting in superior and inferior thinning on peripapillary OCT in ipsilateral eye, and crossed axons representing nasal retina from the contralateral eye, which enter optic nerves on its temporal and nasal sides, representing the so-called band atrophy.¹

The combination of VF testing, peripapillary OCT, and GC-IPL OCT in this case predicted a lesion that was affecting both right pre-chiasmatic optic nerve and right optic tract. T2-weighted unenhanced MRI confirmed this localization revealing an irregular heterogenous mass in the right suprasellar cistern extending and compressing right pre-chiasmatic optic nerve and right optic tract (Figure 1D). Elective neurosurgical resection of the lesion was performed and pathological examination was consistent with a cavernous malformation (CM).

Modern MRI techniques are very sensitive for diagnosing CM in the brain which demonstrate specific characteristics: mixed

hyper- and hypointensity on T1 sequences with surrounding hypointense rim most pronounced on T2 and gradient echo sequences.² Weighted imaging is especially sensitive for detecting features associated with CM and is superior to gradient-echo sequences. In this case, radiological features were typical of CM and the diagnosis was confirmed pathologically.

This case demonstrates importance of neuro-ophthalmic consultation in any patient with optic neuropathy as combination of examination findings along with formal VF testing, peripapillary OCT, and ganglion cell analysis of the macular complex can accurately predict the location of the intracranial lesion. The amount of thinning on ganglion cell analysis is also an excellent predictor of final visual outcome.

Statement of Authorship. All authors were involved in idea generation and data collection. M.M.P. and E.M. drafted the article. All authors revised the manuscript for intellectual content.

Conflicts of Interest. The authors have no conflicts of interest to declare.

References

1. Rodriguez AR, Reddy K. Pearls & Oysters: optic tract syndrome. *Neurology*. 2010;75:e86–7.
2. Wang KY, Idowu OR, Lin DDM. Radiology and imaging for cavernous malformations. *Handb Clin Neurol*. 2017;143:249–66.