

LETTER TO THE EDITOR**TO THE EDITOR****Simultaneous Classical and Holmes' Tremor in Parkinson's Disease: Involvement of the Cerebellum****Keywords:** Holmes tremor, Parkinson disease, cerebellum

The classical tremor of Parkinson's disease (PD) occurs during rest and is usually suppressed during movement. Holmes' tremor (HT) is a rare symptomatic movement disorder characterized by tremor at rest, enhanced by posture and further exacerbated by kinetic action, which occurs after a variety of lesions involving the brainstem and thalamus. The clinical phenomenology of HT is complex and may be accompanied by symptoms of ataxia, dystonia, ophthalmoplegia and bradykinesia.¹⁻³ Studies suggest that combined damage to the cerebello-thalamic and nigrostriatal systems is required for the genesis of HT.¹⁻⁴ Here, we report a patient with prior cerebellar dysfunction who subsequently developed bilateral PD with both HT and classical parkinsonian rest tremor.

In 2014 an 82-year-old patient presented with a two-year history of tremor in both hands. His medical history included vertebrobasilar stroke in 1989, at the age of 57, when cranial magnetic resonance imaging (MRI) revealed a left temporo-occipital hemorrhagic infarction, ischemic lesion in the right pontomedullary region, and a small ischemic lesion in the right cerebellar hemisphere. This stroke left him with a right homonymous hemianopia and a slight cerebellar ataxia on the right side, which had lasted for 25 years and forced him to become left-handed.

In 2014 clinical examination prior to beginning dopaminergic treatment demonstrated a bilateral tremor with inconsistent characteristics in his upper limbs: a coarse, irregular, low frequency resting tremor in the right arm which was accentuated by posture and further increased by goal-directed movements; on the left side, he had classic parkinsonian rest hand tremor without postural or intention tremor (video 1, segments 1-4). In addition, the patient had right homonymous hemianopia examined by confrontation, dystonic posturing in the right hand, mild hypomimia, chin tremor, and bilateral mild rigidity and bradykinesia (video 1, segment 5). Electromyographic recordings revealed alternating contraction of agonist and antagonist muscles of the left upper limb during the resting limb position at a frequency of less than 6 Hz and an irregular tremor at rest, at lower frequencies in the right arm (Figure 1). There was no co-contraction of the agonist-antagonist muscles in the right upper limb. Cranial MRI revealed left parieto-temporal atrophy with left ventricular ectasia, encephalomalacia in the left posterior cerebral artery territory, small infarction in the right cerebellum and lacunar infarction in the left thalamus (Figure 2 A-D). Single-photon emission computed tomography with I123 ioflupane (DaTSCAN) demonstrated a marked dopaminergic deficiency in the bilateral striatum (figure 3). PD was diagnosed and the patient received levodopa, reaching a final dose of 750 mg/day with positive response of the three components of HT. Rest tremor in the left arm, chin tremor and other parkinsonian symptoms (rigidity and bradykinesia) were slightly improved.

The right tremor in our case met the criteria for HT defined by the Ad Hoc Scientific Committee of the Movement Disorders

Society:¹ rest and intention tremor, sometimes postural tremor of low frequency, with irregular amplitude, and usually arrhythmic. HT is a symptomatic tremor that occurs after a variety of lesions centered on the brainstem/cerebellum and thalamus, although in some cases no lesion can be demonstrated.

The presence of a pre-existing brain lesion may change the clinical presentation of PD. Three cases presenting with atypical clinical features of PD associated with the mass effect of a significantly enlarged pre-existing Virchow-Robin space have been reported.⁵ Our case had a pre-existing cerebellar dysfunction, and the HT developed after the appearance of PD. A few patients have been reported with HT caused by pre-existing cerebellar dysfunction and subsequent nigrostriatal deficit.^{4,6} Another case report described a patient with PD who developed HT after acute cerebellar stroke.⁷

These findings provide strong clinical evidence that separate lesions in cerebellar and nigrostriatal pathways, with different etiologies and occurring at different times, also induce HT. In our patient, lacunar lesion of the cerebellum or the thalamus cannot explain the significant damage through the cerebello-thalamic pathways; however, as mentioned above, in some cases of HT no lesion can be demonstrated. A possible explanation for the occurrence of HT in our patient is that there was a pre-existing cerebello-thalamic dysfunction due to the vertebrobasilar stroke and a subsequent nigrostriatal dysfunction due to PD. These systems also have lesions along the further projections of their fiber tracts, and so the HT might also be caused by lesions in other locations (for example, at multiple cortical sites)¹.

Recent reports have speculated about the pathophysiological heterogeneity of HT. This is supported by DaTSCAN studies that show only minimal differences between the two sides, with slightly poorer uptake contralateral to the HT.² These studies raise the question of whether nigrostriatal pathway damage is crucial for the phenomenology of this condition. Levodopa responsiveness is also regarded as a marker of nigrostriatal involvement in HT: given that some patients fail to respond to levodopa, it has been speculated that variations in pathophysiology may explain the different responses to drugs.^{2,3,6,7} In our case, both the DaTSCAN study and the improvement after levodopa therapy suggest that nigrostriatal pathway damage is involved.

Finally, some studies of the cerebral interactions between motor planning and PD tremor at rest suggest that this tremor and voluntary movement execution arise from similar oscillations in the motor cortex, which may explain why they do not occur simultaneously.⁸ Our patient had a cerebellar dysfunction before the development of PD and presented resting tremor on both sides but with different frequencies and with an additional postural and intention tremor on the same side as the cerebellar dysfunction. Then, the observation that tremor at rest is no longer inhibited at movement onset when the cerebellum is malfunctioning suggests that the cerebellum may modulate the frequency and amplitude of PD tremor by treating it as if it were a voluntary motor behavior.^{4,6,8}

In conclusion, our case supports the hypothesis that the combined damage of cerebello-thalamic and nigrostriatal systems is required for the genesis of HT. Our findings also suggest that the cerebellum plays a role in the characteristics of PD tremor and

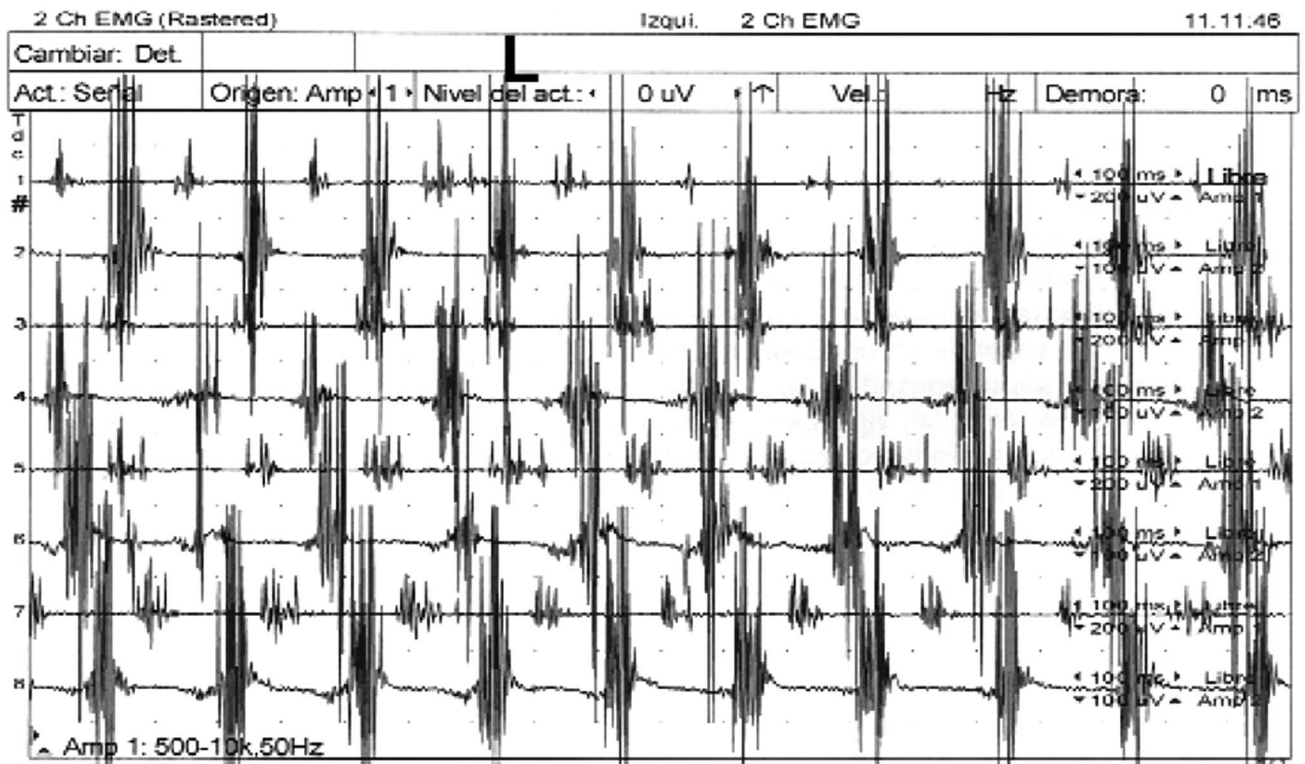
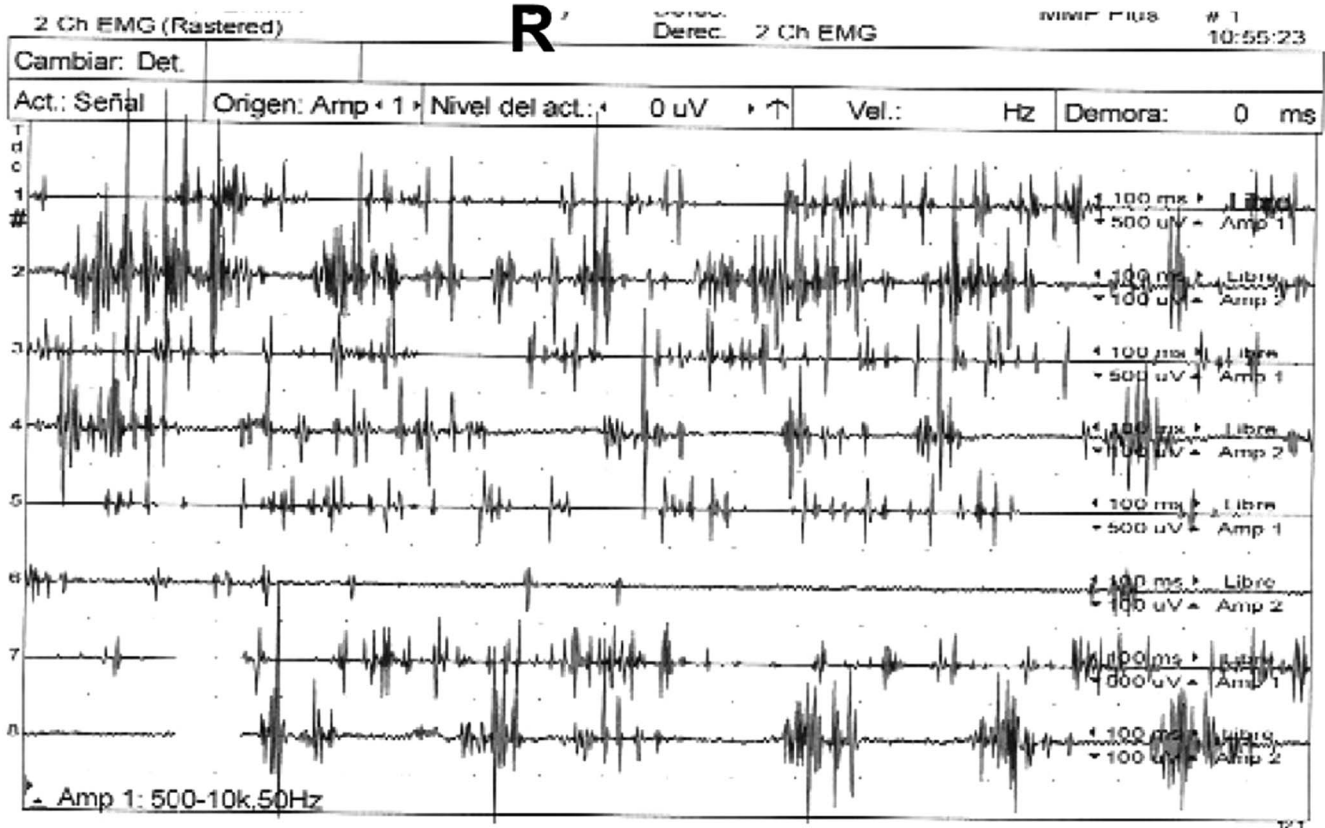


Figure 1: Electromyographic recordings of the tremor of both hands.

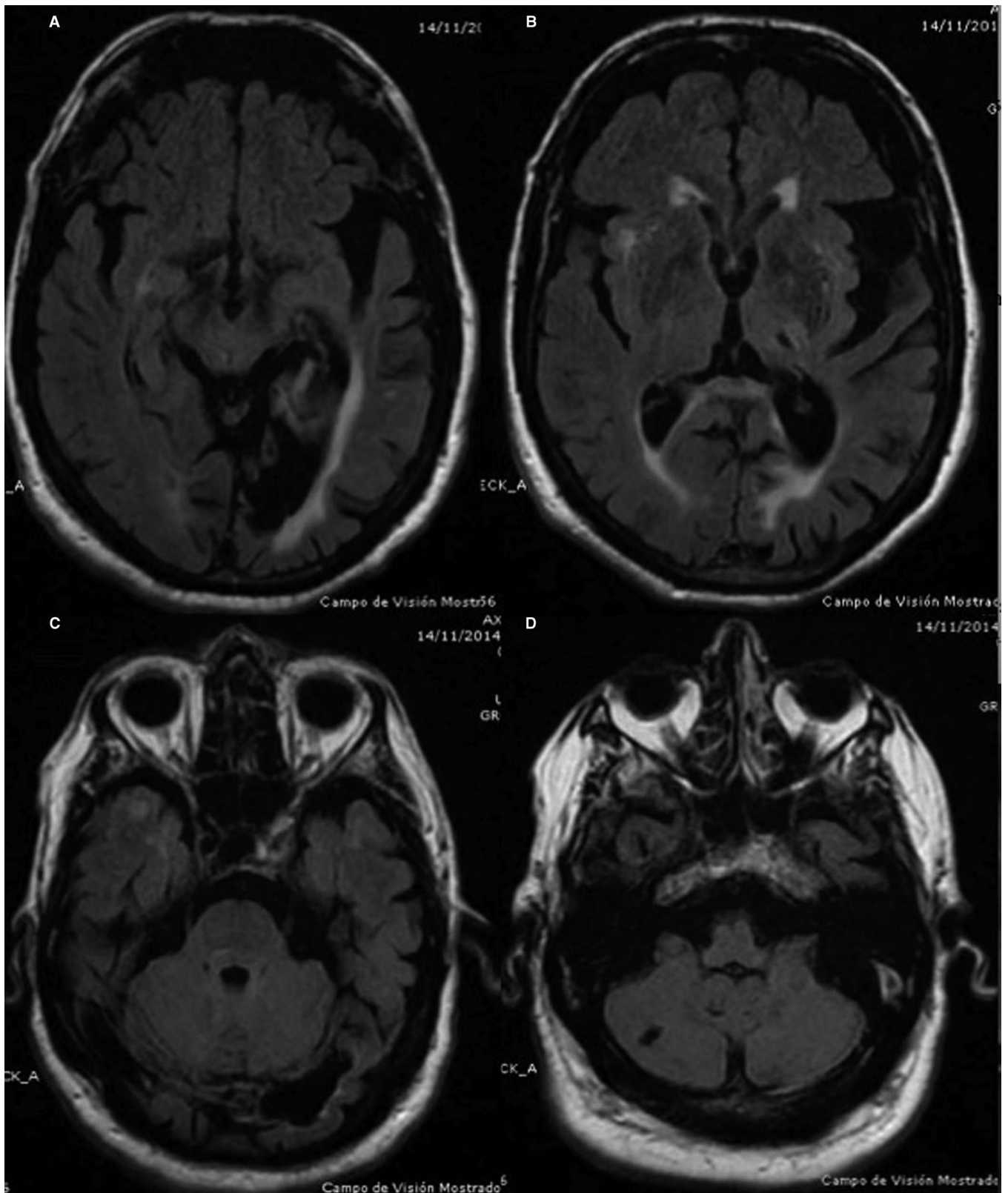


Figure 2: Axial FLAIR cranial MRI images.

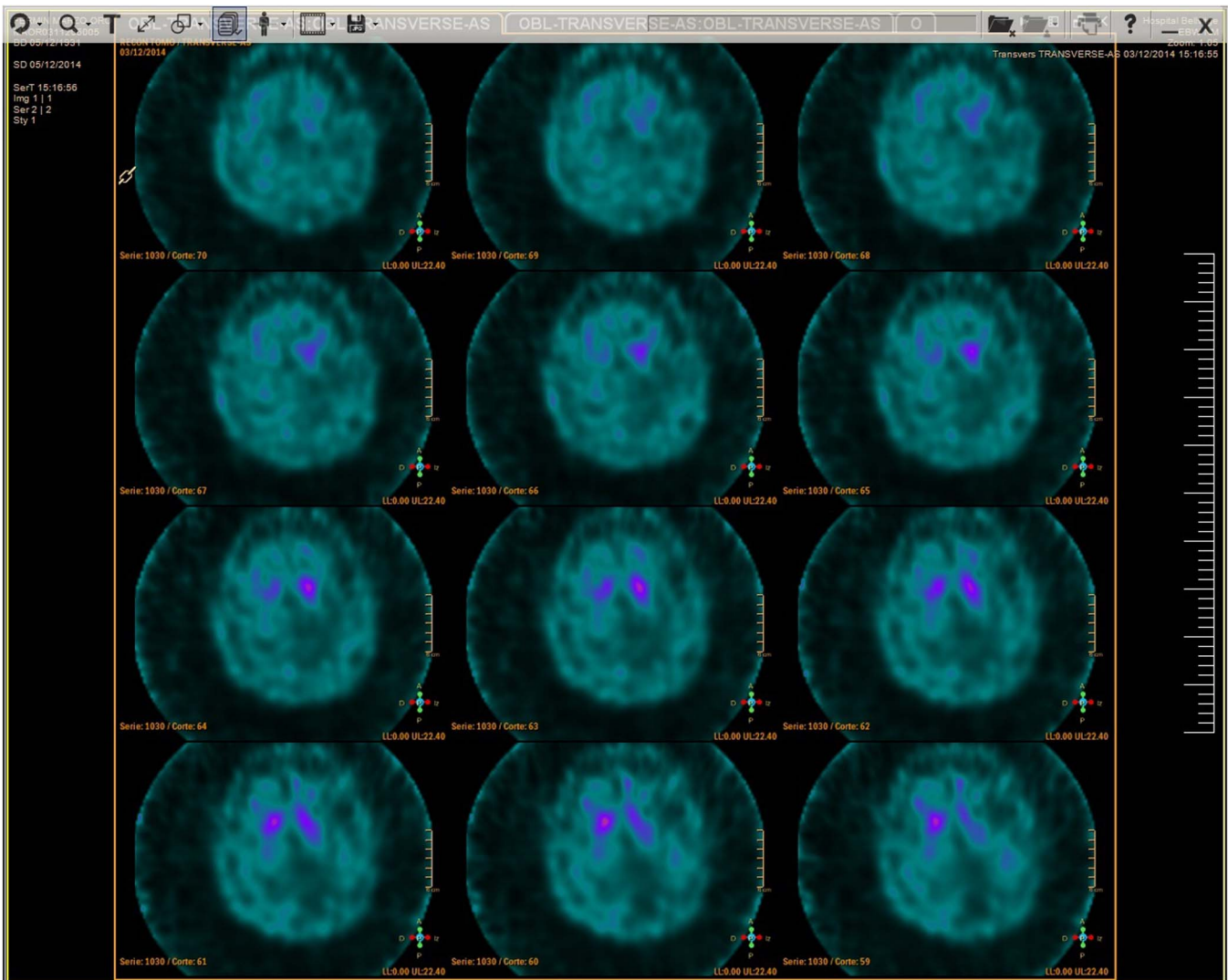


Figure 3: Single-photon emission computed tomography with ^{123}I oflupane (DaTSCAN) images.

is involved in the suppression of resting tremor during voluntary movements.

DISCLOSURES

Asunción Ávila, Nuria Caballol, and Martí Martí do not have anything to disclose.

Asunción Ávila

*Department of Neurology, Hospital General de l'Hospitalet and
Hospital Sant Joan Despí Moisès Broggi
Consorci Sanitari Integral, Barcelona, Spain
Email: aavila@csi.cat*

Nuria Caballol

*Department of Neurology, Hospital Sant Joan Despí Moisès
Broggi. Consorci Sanitari Integral, Barcelona, Spain*

Martí Martí

*Department of Neurology, Hospital Sant Joan Despí Moisès
Broggi. Consorci Sanitari Integral, Barcelona, Spain*

SUPPLEMENTARY MATERIAL

To view supplementary material for this article, please visit <https://doi.org/10.1017/cjn.2016.451>

REFERENCES

1. Deuschl G, Bain P, Brin M, an Ad Hoc Scientific Committee of the Movement Disorders Society. Consensus statement of the Movements Disorders Society on Tremor. *Mov Disord.* 1998;13(Suppl 3):2-23.
2. Gajos A, Bogucki A, Schinwelski M, et al. The clinical and neuroimaging studies in Holmes tremor. *Acta Neurol Scand.* 2010;122:360-6.
3. Raina GB, Cersosimo MG, Folgar SS, et al. Holmes tremor. Clinical description, lesion localization, and treatment in a series of 29 cases. *Neurology.* 2016;86:1-8.

4. Deuschl G, Bergman H. Pathophysiology of nonparkinsonian tremors. *Mov Disord.* 2002;17(Suppl. 3):S41-8.
5. Mestre TA, Armstrong MJ, Walsh R, Dakheel AA, Moro E, Stoessl AJ, Lang AE. Can isolated enlarged Virchow-Robin Spaces Influence the clinical Manifestations of parkinson's disease? *Mov Disord Clin Pract.* 2014;67-9.
6. Deuschl G, Wilms H, Krack P, Wurker M, Heiss WD. Function of the cerebellum in parkinsonian rest tremor and Holmes' tremor. *Ann Neurol.* 1999;46:126-8.
7. Kim DG, Koo YH, Kim OJ, Oh SH. Development of Holmes' tremor in a patient with Parkinson's disease following acute cerebellar infarction. *Mov Disord.* 2009;24(3):463-4.
8. Helmich RC, Hallet M, Deuschl G, Toni I, Bloem BR. Cerebral causes and consequences of parkinsonian resting tremor: a tale of two circuits? *Brain.* 2012;135:3206-26.