
Neuroimaging Highlight

Editors: Richard Farb, David Pelz

Acquired Monocular Nystagmus as the Initial Presenting Sign of a Chiasmal Glioma

Submitted by: Francois Dominique Jacob, Vijay Ramaswamy, Helly R. Goetz

Can. J. Neurol. Sci. 2010; 37: 96-97

A 15-month-old male presented with a one-day history of acute onset, continuous oscillating movement of his right eye. He had received his one-year immunizations four days prior and had a four-day history of a febrile viral respiratory tract infection. Pregnancy was unremarkable. He had severe iron deficiency anemia (MCV 66, Hb 65) and was developmentally delayed, as he was unable to stand independently and was non-verbal. His head circumference was 49 cm (95th percentile) and his weight was at the 25th percentile. On physical examination, continuous horizontal large amplitude pendular nystagmus of the right eye at a frequency of 3-4 Hz was observed. No nystagmus was observed in the left eye, even on fundoscopic examination. The child could fixate targets in all four quadrants with both eyes

independently, and could fixate and track small objects with both eyes independently suggesting no significant visual field defect or visual loss. Dilated fundoscopic examination was normal, extra ocular movements were full, pupils were equal and reactive and there was no relative afferent pupillary defect. The remainder of the neurological examination was normal. There was no head bobbing or anomalous head position and no stigmata of neurofibromatosis type 1. Magnetic resonance imaging of the brain (Figure) demonstrated a 2 cm x 1.6 cm x 1.2 cm suprasellar enhancing mass involving the optic chiasm, hypothalamus, mammillary bodies and superior pituitary stalk. There was no extension into the pituitary fossa or the optic nerves and no ventricular enlargement. A biopsy of the mass was

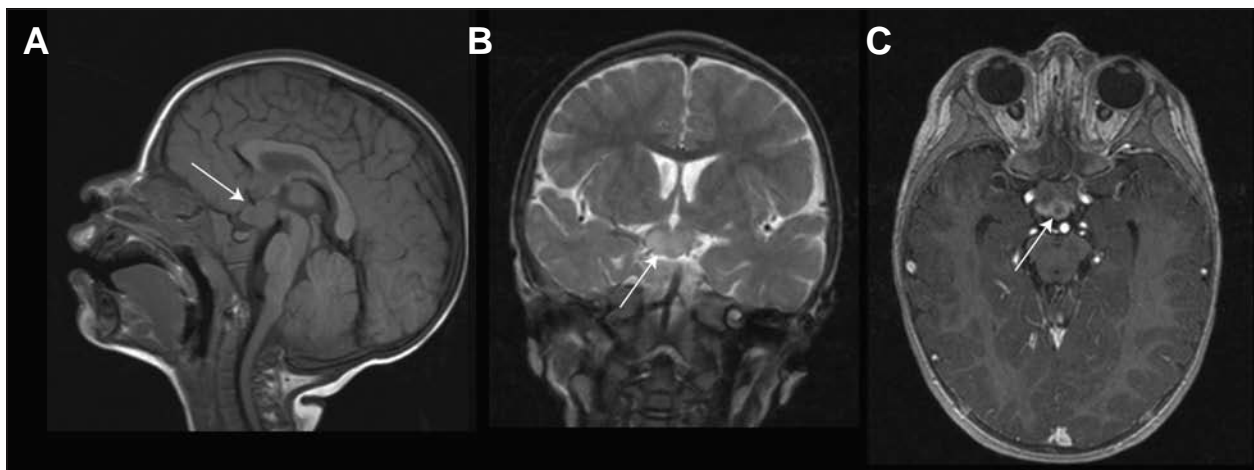


Figure: A) Sagittal T1 weighted image through the corpus callosum revealing a suprasellar mass involving the hypothalamus, mammillary bodies and superior pituitary stalk isointense to gray matter (arrow) B) Coronal T2 weighted image revealing a hyperintense chiasmal mass C) Axial contrast enhanced MP-RAGE sequence (Magnetization Prepared Rapid Acquisition Gradient Echo, T1-weighted) revealing a heterogeneously enhancing mass of the optic chiasm.

From the Division of Pediatric Neurology, University of Alberta, Edmonton, Alberta, Canada.

RECEIVED MAY 14, 2009. FINAL REVISIONS SUBMITTED JULY 20, 2009.

Correspondence to: Helly R. Goetz, Director, Division of Pediatric Neurology, Department of Pediatrics, Stollery Children's Hospital, #7319A Aberhart Centre 1, 11402 University Ave NW, Edmonton, Alberta, T6G 2J3, Canada.

obtained and revealed histology consistent with a low-grade pilocystic astrocytoma (World Health Organization (WHO) grade 1), consistent with a diagnosis of chiasmal glioma.

Acute onset acquired monocular pendular nystagmus is a rare occurrence in childhood. Multiple small case series suggest the differential diagnosis includes chiasmal, suprachiasmal or third ventricular tumours, spasmus nutans or acute visual loss.¹ In a series of 24 children with monocular nystagmus, five had chiasmal gliomas, one had a craniopharyngioma, and seven were diagnosed with spasmus nutans after normal electrophysiology, neuroimaging and ophthalmologic exam.¹ In another series monocular nystagmus was the presenting sign of a chiasmal glioma in nine out of ten patients under ten months-of-age.² The majority of optic pathway gliomas in childhood are low grade pilocytic astrocytomas and are commonly associated with neurofibromatosis type I.³ The mechanism of monocular nystagmus in chiasmal gliomas remains unclear but is likely secondary to acute visual loss, which is difficult to assess in infancy. Acquired and congenital visual loss of other etiologies have also been reported to result in monocular nystagmus.⁴ A report of unilateral nystagmus as a presenting sign of thalamic glioma suggests that monocular nystagmus can occur posterior to the optic chiasm.⁵ Vertical monocular nystagmus has also been reported to be associated with chiasmal glioma.⁶ Spasmus nutans is a benign, self-limiting rare disorder comprised of a triad of nystagmus, head nodding and a head tilt typically occurring between the ages of 6-12 months. The nystagmus is bilateral, low amplitude and pendular with horizontal, vertical or torsional component. However, it may be asymmetrical and appear monocular. Clinically it may be difficult to differentiate between spasmus nutans and an optic pathway glioma. In a series of 11 patients between 4 and 14 months-of-age, where six had chiasmal gliomas and four had spasmus nutans, there was no significant difference in clinical and ophthalmologic examination between the two groups.⁷ In older children and adults, demyelinating disease, brainstem infarction and diffuse axonal injury have been reported to cause dissociated nystagmus.⁸ This case highlights the importance of neuroimaging in all cases of acquired monocular nystagmus in infancy to rule out neoplastic etiologies.

REFERENCES

1. Shaw FS, Kriss A, Russel-Eggitt I, Taylor D, Harris C. Diagnosing children presenting with asymmetric pendular nystagmus. *Dev Med Child Neurol.* 2001 Sep;43(9):622-7.
2. Lavery M, O'Neill J, Chu F, Martyn L. Acquired nystagmus in early childhood: a presenting sign of intracranial tumor. *Ophthalmology.* 1984;91(5):425-53.
3. Jahraus CD, Tarbell NJ. Optic pathway gliomas. *Pediatr Blood Cancer.* 2006 May 1;46(5):586-96.
4. Yee RD, Jelks GW, Baloh RW, Honrubia V. Unilateral nystagmus in monocular visual loss. *Ophthalmology.* 1979 Apr;86(4):511-22.
5. Baram TZ, Tang R. Atypical spasmus nutans as an initial sign of thalamic neoplasm. *Pediatr Neurol.* 1986 Jan 1;2(6):375-6.
6. Schulman JA, Shults WT, Jones JM. Monocular vertical nystagmus as an initial sign of chiasmal glioma. *Am J Ophthalmol.* 1979 Jan 1;87(1):87-90.
7. Good WV, Koch TS, Jan JE. Monocular nystagmus caused by unilateral anterior visual-pathway disease. *Dev Med Child Neurol.* 1993 Dec 1;35(12):1106-10.
8. Ozer F, Mutlu A, Meral H, Kansu T, Carsancakli B. Wall-eyed bilateral internuclear ophthalmoplegia presenting as monocular alternating nystagmus: a non-epileptic phenomenon in a case of diffuse axonal injury. *Epileptic Disord.* 2005 Mar 1;7(1):53-6.