

Ultrastructural Pathology of Smooth Muscle Tissue Surrounding Prostatic Adenocarcinoma

H.J. Finol, * T.Gledhill,** D. Parada,** C. López,** and O. Moreira***

* Center for Electron Microscopy, Sciences Faculty, Central University of Venezuela, Apartado 47114, Caracas 1041-A, Venezuela

** Department of Pathology, Vargas Hospital, and Department of Histology and Embryology, Vargas School of Medicine, Medicine Faculty, Central University of Venezuela, Caracas, Venezuela

*** Department of Urology, Vargas Hospital, Caracas, Venezuela

It is generally accepted that both the non-invaded tissue which surrounds a primary malignant tumor and the non-invaded cells in close proximity to the tumor cells are normal [1]. However, the non-invaded skeletal muscle fibers adjacent to a malignant fibrous histiocytoma and the extraocular muscle fibers in cases of retinoblastoma exhibit a wide spectrum of abnormalities in muscle cells, axon terminals, and microvasculature [2,3]. In this work, we describe the ultrastructural alterations in non-invaded smooth muscle tissue surrounding prostatic adenocarcinoma.

Human prostatic tissue was surgically obtained from four patients admitted at the Urology Service of the Vargas Hospital of Caracas with a clinical and fine needle biopsy diagnosis of prostatic adenocarcinoma. The average age of the patients was 63.75 years with a range of 58-71 years. Urinary obstructive symptoms, enlargement of the prostatic gland, and elevation of the serum prostate specific antigen (PSA) level were present in all patients. Representative samples from the surgical specimens were processed by routine light and transmission electron microscopy techniques, and an Hitachi H-500 electron microscope was used for ultrastructural observation. All specimens were graded histologically on the basis of the Gleason scoring system: three cases showed a Gleason pattern 3 tumor (combined Gleason grade=6) and in the remaining case, a Gleason pattern 4 tumor (combined Gleason grade=9) was found.

The ultrastructural findings in smooth muscle tissue were as follows: some smooth muscle cells were atrophic and exhibited increased electron density. Other fibers showed areas with loss of myofilament alignment, cytoplasmic vacuolization, few dense bodies with variable thickness, scarce dense plaques, decreased number of caveolae, swelling of mitochondria and rough endoplasmic reticulum (RER), partial loss of polysomes, abundant myelin-like figures and other types of autophagic vacuoles (Fig. 1 and 2). In some sections, smooth muscle cells exhibited widening, interruption and even loss of the basement membrane. Capillaries also showed variable electron density and thickness of the endothelial cell cytoplasm, infoldings into the lumen, and variable degrees of lumen occlusion. In some areas, mitochondria and RER were scarce and swollen; however, other sections were nearly empty. Lipofuscin granules were also found. Caveolae number was highly reduced, and in some areas, basement membrane was thickened and laminated.

These results indicate that the non-invaded smooth muscle tissue surrounding a prostatic adenocarcinoma can be abnormal.

References

[1] R.S. Cotran et al., Robbins Pathologic Basis of Disease, 6th ed., W.B. Saunders Company, Philadelphia, 1999.

[2] H.J. Finol et al., J. Exp. Clin. Cancer Res. 13 (1994) 381.

[3] H.J. Finol et al., J. Exp. Clin. Cancer Res. 20 (2001) 281.

[4] This research was supported by a grant from the C.D.C.H of U.C.V (P.I. 03-10-4169-2000)

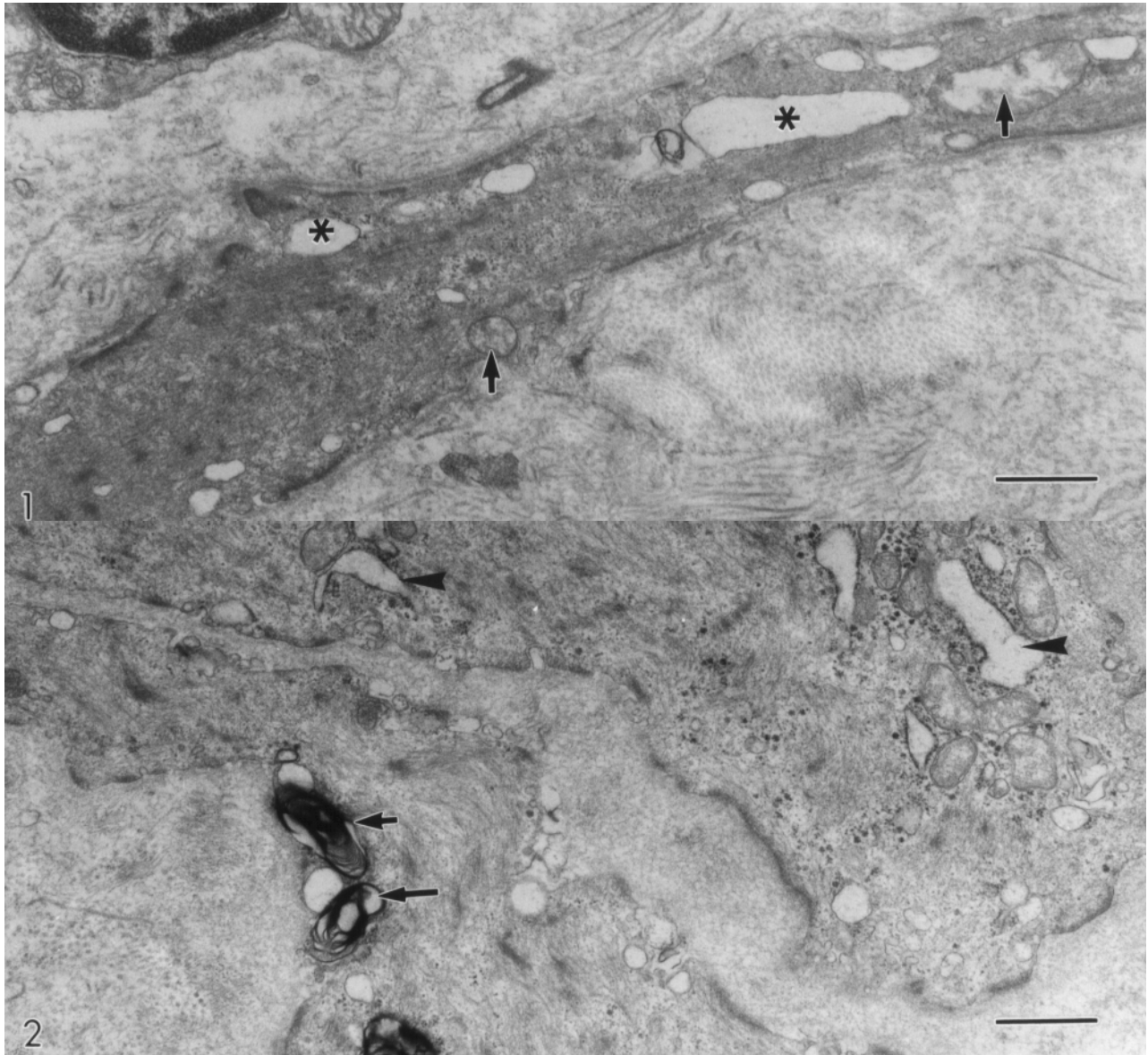


Fig.1. Atrophied smooth muscle cells showing vacuoles (asterisk) and swollen mitochondria (arrow). Bar=0.7 μ m

Fig.2. In this section observe autophagic vacuoles (arrow) and swollen RER cisternae (arrowhead). Bar=0.7 μ m

