

## **An Anatomical Perspective to Botulinum Toxin Injection of Flexor Digitorum Profundus**

Emma Stefanie Campisi<sup>1</sup>, Omar Khan<sup>2,3</sup>, Anne Marie Reet Agur<sup>1</sup>, Rajiv Reebye<sup>3,4</sup>

<sup>1</sup>Division of Anatomy, Temerty Faculty of Medicine, University of Toronto, Toronto, ON, Canada

<sup>2</sup>Hotel Dieu Shaver Health and Rehabilitation Centre, St. Catharines, ON, Canada

<sup>3</sup>Canadian Advances in Neuro-Orthopedics for Spasticity Consortium (CANOSC), Kingston, ON, Canada

<sup>4</sup>Division of Physical Medicine & Rehabilitation, University of British Columbia, Vancouver, BC, Canada

**Corresponding Author:** Emma Stefanie Campisi, Division of Anatomy, University of Toronto, Temerty Faculty of Medicine, 1 King's College Circle, Toronto, Ontario Canada M5S 1A8, Mail: [emma.campisi@mail.utoronto.ca](mailto:emma.campisi@mail.utoronto.ca)

Spasticity is a sensorimotor control disorder that results from an upper motor neuron lesion that presents as intermittent or sustained involuntary muscle activation that can have a significant impact on a patient's active or passive function [1]. The flexor digitorum profundus (FDP) is a commonly targeted muscle for botulinum toxin A (BoNT-A) in patients with spasticity due to finger in palm deformity involving the distal interphalangeal joints of digits 2-5, and wrist flexion in patients with focal spasticity. Focal dystonias of the forearm can also be treated successfully with botulinum toxin. The objective of this paper is to demonstrate how the anatomical findings of Campisi et al., [2] have been translated to a clinical setting to enhance injection protocols of BoNT-A for the management of FDP post-stroke spasticity.

Previous anatomical studies that describe the morphology of the digital bellies of FDP are scarce and primarily descriptive. In a volumetric 3D anatomical study [2], the intramuscular innervation of each of the digital bellies of FDP was mapped using cartesian coordinate data obtained from dissection and digitization of the digital bellies and intramuscular innervation as in situ. In contrast to previous descriptive 2D studies, this volumetric study found that the 3rd, 4th, and 5th digital bellies were superficial to the 2nd in all specimens (Figure 1 A, B). The 2nd digital belly

was found to be innervated by the anterior interosseus nerve (AIN), which continued intramuscularly to supply the 3rd digital belly distally in all specimens. The proximal part of the 3rd digital belly was innervated by a branch of the ulnar nerve (UN). The entire 4th digital belly received innervation from a branch of the UN that continued intramuscularly to supply the more inferiorly located 5th digital belly in approximately half of the specimens. In the remaining specimens, the 5th digital belly was supplied by a branch of the UN only (Figure 1 A, B).

Previous cadaveric studies have proposed BoNT-A injection sites based on nerve entry points into FDP, or described the sites based on injection into the muscle belly as a whole [3-6]. Campisi et al., [2], based on the findings of this volumetric study, proposed one needle entry site for BoNT-A at the junction of the proximal and middle third of the length of the forearm. Sihler's staining studies have also reported "nerve terminal dense zones" in the proximal third of the muscle belly [5, 6]. Fractional distribution of injectate into each of the digital bellies at this site could also target the nerve endings/ motor end plates.

Importantly, instrumental guidance has been recommended as standard practice for the BoNT-A injection technique. In a randomized control trial by Picelli et al., [7] stroke patients with wrist and finger spasticity were randomized to receive BoNT-A injections using manual needle placement (palpation technique), electrical stimulation guidance, or ultrasonography guidance. The groups that received injection using electrical stimulation or ultrasonography demonstrated significant improvements in Modified Ashworth Scale scores, Tardieu angle, and passive range of motion compared to patients in the manual needle placement group [7]. Furthermore, a systematic review concluded that ultrasound may lead to better visualisation of targeted muscles, and thus improve the accuracy of injection and potentially improve clinical outcomes [8]. Although electromyography and electrical stimulation can improve injection accuracy, they rely on anatomical surface landmarking, especially for initial needle insertion. Abnormal posturing of spastic limbs can lead to distortion of the associations between muscle targets and the surface landmarks, rendering the commonly held injection approaches to have lower accuracy [8]. One of the main advantages of ultrasound is to verify the approach to the target prior to needle insertion. Thus, specific structures can be avoided so that there is less change in needle position during the injection, as compared to electromyography and needle stimulation, which often

require repositioning of the needle. Ultrasonography also provides continuous visualization of the target muscles to track the path of the needle and to verify the location of injection.

Our first clinical pearl highlights the importance of the anatomical relationship of the 3<sup>rd</sup>, 4<sup>th</sup> and 5<sup>th</sup> digital bellies of FDP being superficial to the 2<sup>nd</sup> digital belly. This has implications for injection targeting and appropriate fractional distribution of BoNT-A into FDP. The authors recommend a single needle entry point at the junction of the proximal and middle third of the length of the forearm, one finger's breadth anterior to the ulna (Figure 1). First, the needle is directed in a slightly deeper angle to inject the 2<sup>nd</sup> digital belly, and then drawn back and redirected more superficially to inject the 3<sup>rd</sup> and then 4<sup>th</sup> and 5<sup>th</sup> digital bellies as the needle is drawn back towards exiting (Figure 1 C). The ulnar artery and nerve are located just superficial to the 3<sup>rd</sup> digital belly and should be avoided along with flexor carpi ulnaris (Figure 1 C). The proposed injection approach could be further guided by electromyography and/or electrical stimulation to verify individual muscle belly needle entry. However, the authors suggest direct visualization under ultrasound guidance could provide a more targeted injection, particularly for patients in which surface landmarks are difficult to verify.

Our second clinical pearl focuses on the authors' recommendation of fractional distribution of injection into the FDP muscle. Although a single large injection volume into the FDP muscle could in theory be used, it would be unlikely to distribute BoNT-A evenly or adequately throughout the entire muscle. Rather, it may be more effective to inject into each digital belly by placing the needle tip into each belly to deliver the appropriately desired dose/volume of neurotoxin. Thus, the practitioner could more effectively distribute the injectate throughout the muscle or into specific individual bellies to optimize outcomes for difficult to treat flexed spastic hand deformity, or in cases of functional spastic or dystonic hand in which sparing of certain digits for function would be of paramount importance.

In conclusion, the authors suggest the recommended needle entry site and injection pattern (Figure 1), ideally paired with ultrasound guidance, could serve to optimize BoNT-A delivery and avoid misplacement of the injection(s). We plan to further study the injection accuracy of this recommended injection approach and report on the findings in future publications.

## Statement of Authorship

ESC, investigation, data curation, visualization, original draft preparation, review, editing; OK, original draft preparation, review, editing; AMRA, original draft preparation, conceptualization, investigation, review, editing; RR, original draft preparation, conceptualization, investigation, review and editing.

## Conflicts of Interest

All authors declare no conflicts of interest.

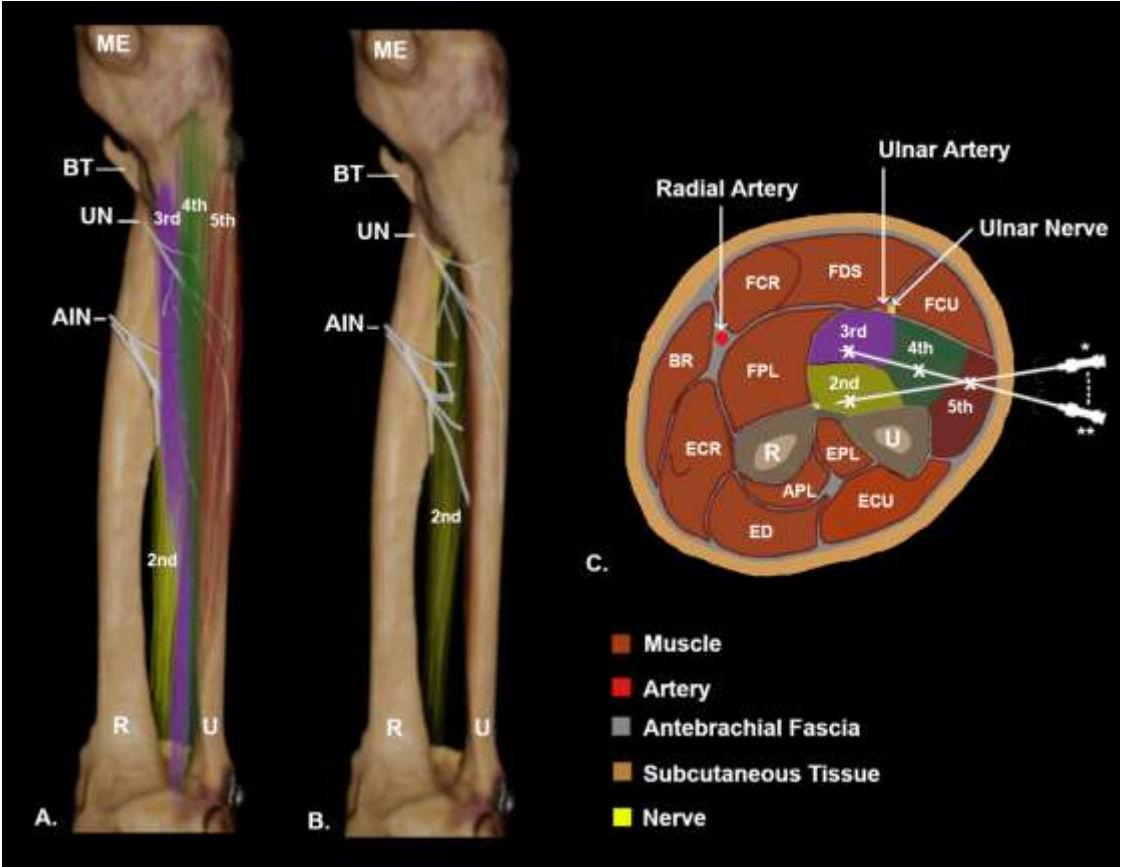
## Funding

The authors did not receive support from any organization for the submitted work.

## References

1. Pandyan AD, Gregoric M, Barnes MP, et al. Spasticity: Clinical perceptions, neurological realities and meaningful measurement. *Disabil Rehabil.* 2005;27:2-6. doi: 10.1080/09638280400014576
2. Campisi ES, Tran J, Amara CE, Switzer-McIntyre S, Agur AMR. The 3D muscle morphology and intramuscular innervation of the digital bellies of flexor digitorum profundus: Clinical implications for botulinum toxin injection sites. *J Anat.* 2023;00:1-10. doi: 10.1111/joa.13986
3. Hwang K, Jin S, Hwang SH, Lee KM, Han SH. Location of nerve entry points of flexor digitorum profundus. *Surg Radiol Anat.* 2007;29:617-621.
4. Lepage D, Parratte B, Tatu L, Vuiller F, Monnier G. Extra- and intramuscular nerve supply of the muscles of the anterior antebrachial compartment: applications for selective neurotomy and for botulinum toxin injection. *Surg Radiol Anat.* 2005;27:420-430. doi: 10.1007/s00276-005-0012-9
5. Won SY, Hur MS, Rha DW, et al. Extra- and intramuscular nerve distribution patterns of the muscles of the ventral compartment of the forearm. *Am J Phys Med Rehabil.* 2010;89:644-652. doi: 10.1097/PHM.0b013e3181d8a116
6. Yang F, Zhang X, Xie X, Yang S, Xu Y, Xie P. Intramuscular nerve distribution patterns of anterior forearm muscles in children: a guide for botulinum toxin injection. *Am J Transl Res.* 2016;8:5485-5493.

- 114 7. Picelli A, Lobba D, Midiri A, et al. Botulinum toxin injection into the forearm muscles  
115 for wrist and fingers spastic overactivity in adults with chronic stroke: A randomized  
116 controlled trial comparing three injection techniques. Clin Rehabil. 2013;28:232-242. doi:  
117 10.1177/0269215513497735
- 118 8. Chan AK, Finlayson H, Mills PB. Does the method of botulinum neurotoxin injection for  
119 limb spasticity affect outcomes? A systematic review. Clin Rehabil. 2016;31:713-721.  
120 doi:10.1177/0269215516655589



122

123

124

125

126

127

128

129

130

131

132

133

134

**Figure 1.** 3D Mapping of the intramuscular innervation of the digital bellies of flexor digitorum profundus for botulinum toxin injection. A. 3D model of the digital bellies and their intramuscular innervation. Note the 3<sup>rd</sup>, 4<sup>th</sup> and 5<sup>th</sup> digital bellies lie superficial to the 2<sup>nd</sup> belly, proximally. B. 3D model of the intramuscular innervation of the 2<sup>nd</sup> digital belly. C. Targeting of each digital belly for botulinum toxin injection. Transverse section at the level of the junction of the proximal and middle third of the length of the forearm. First, the needle is directed in a slightly deeper angle to inject the 2<sup>nd</sup> digital belly (\*) and then drawn back and redirected more superficially to inject the 3<sup>rd</sup>, 4<sup>th</sup>, and 5<sup>th</sup> digital bellies (\*\*). AIN, anterior interosseus nerve; APL, abductor pollicis longus; BR, brachioradialis, BT, biceps tendon; ECR, extensor carpi radialis; ECU, extensor carpi ulnaris; ED, extensor digitorum; EPL, extensor pollicis longus; FCR, flexor carpi radialis; FCU, flexor carpi ulnaris; FDS, flexor digitorum superficialis; FPL, flexor pollicis longus; ME, medial epicondyle; R, radius; U, ulna; UN, ulnar nerve.