

Young lady with chest pain

George W. King, MD;* Jessie McGowan, MLIS;† Kevin Pottie, MD‡

Case report

A 20-year-old woman presented to the emergency department at 0730 hrs with a 3-hour history of sharp right-sided chest pain without radiation. She denied having shortness of breath, cough or fever. She had not sustained any trauma or undergone any surgical procedure recently. Although a smoker, she had no other significant past medical or family history. At the time, she was not on any prescription or non-prescription medications, nor was she allergic to any medications.

In the emergency department, her colour was normal and she conversed easily. Vital signs included a heart rate of 108 beats/min, a blood pressure of 113/79 mm Hg, respiratory rate of 22 breaths/min, a temperature of 36.9°C and a room air oxygen saturation of 98%. She appeared in to be in mild distress and was massaging her right chest wall. The chest was normal to percussion but slightly tender to palpation on the right side. The trachea was not deviated. Auscultation demonstrated good air entry bilaterally with louder breath sounds on the right. No adventitious breath sounds were heard. Upon closer examination the loud breath sounds on the right could be described as tracheal or large airway in character — unlike the normal vesicular sounds heard on the left side.

Results of her chest x-ray are shown in Figure 1. The correct diagnosis is:

- A. Pleural effusion
- B. 100% pneumothorax with atypical sound transmission

- C. Multilobar consolidation with delayed x-ray changes
- D. Pulmonary infarction

For the Answer to this Challenge, see page 296.

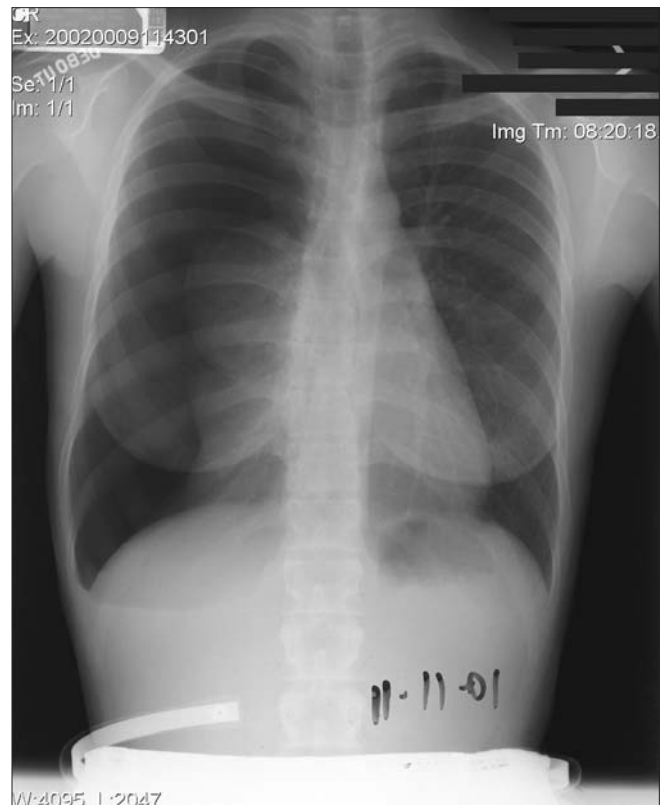


Fig. 1. Chest x-ray of 20-year-old patient with sharp right-sided chest pain without radiation.

*Department of Emergency Medicine, Hawkesbury General Hospital, Hawkesbury, Ont.

†Institute of Population Health, University of Ottawa, Ottawa Health Research Institute, Ottawa, Ont.

‡Faculty of Family Medicine, University of Ottawa, Ottawa, Ont.

Received: Jan. 17, 2003; final submission: Jan. 13, 2004; accepted: Feb. 2, 2004

This article has been peer reviewed.

Can J Emerg Med 2004;6(4):290