



# Life-threatening pulmonary haemorrhage treated with coil embolisation followed by lobectomy in a patient with *KCNT1* mutation

## Brief Report

**Cite this article:** Chauhan D, Verhoeven PA, Kohli U, Udassi JP, and Mascio CE (2024) Life-threatening pulmonary haemorrhage treated with coil embolisation followed by lobectomy in a patient with *KCNT1* mutation. *Cardiology in the Young* **34**: 701–703. doi: [10.1017/S104795112300447X](https://doi.org/10.1017/S104795112300447X)


Received: 14 August 2023  
Revised: 13 November 2023  
Accepted: 22 December 2023  
First published online: 17 January 2024

### Keywords:

*KCNT1*; lobectomy; pulmonary haemorrhage

### Corresponding author:

Dhaval Chauhan;  
Email: [dhavalchauhan86@gmail.com](mailto:dhavalchauhan86@gmail.com)

Dhaval Chauhan<sup>1</sup> , Pieter Alexander Verhoeven<sup>2</sup>, Utkarsh Kohli<sup>2</sup>, Jai P. Udassi<sup>2</sup> and Christopher E. Mascio<sup>1</sup>

<sup>1</sup>Division of Pediatric Cardiothoracic Surgery, Department of Cardiovascular and Thoracic Surgery, West Virginia University Medicine Children's Hospital, Morgantown, WV, USA and <sup>2</sup>Division of Pediatric Cardiology, Department of Pediatrics, West Virginia University Medicine Children's Hospital, Morgantown, WV, USA

### Abstract

*KCNT1* mutations are associated with childhood epilepsy, developmental delay, and vascular malformations. We report a child with a likely pathogenic *KCNT1* mutation (c.1885A>C, p.Lys629Glu) with recurrent pulmonary haemorrhage due to aortopulmonary collaterals successfully managed with coil embolisation followed by right upper lobectomy.

### Introduction

*KCNT1* encodes a sodium-activated potassium channel (Slack K<sup>+</sup> (K<sub>Na</sub>1.1)) in the human central nervous system. Pathogenic *KCNT1* mutations are associated with epileptic syndromes such as infantile epileptic encephalopathy and nocturnal frontal lobe epilepsy.<sup>1,2</sup> Other phenotypic manifestations in *KCNT1* mutation carriers include development of systemic-to-pulmonary artery collaterals, intermittent corrected QT interval prolongation, and severe developmental delay.<sup>3</sup> The systemic-to-pulmonary artery collaterals may result in high output cardiac failure, or severe pulmonary haemorrhage, and are known to recur despite multiple catheter-based interventions.<sup>4</sup> We present a case of a child with a likely pathogenic *KCNT1* mutation (c.1885A>C, p.Lys629Glu) presenting with severe pulmonary haemorrhage, treated with coil embolisation of systemic-to-pulmonary artery collaterals followed by right upper lobectomy.

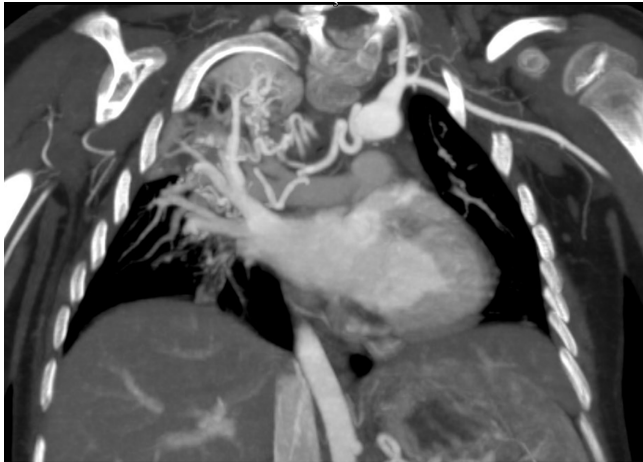
### Case report

A 3-year-old female carrier of a likely pathogenic *KCNT1* mutation with intractable epilepsy and gross developmental delay presented to the emergency department with an acute episode of bleeding from the nose and oropharynx and prolonged seizure episodes. Her other medical problems included a history of prolonged corrected QT interval and torsade de pointes following quinidine administration, a patent foramen ovale, congenital hydronephrosis, respiratory distress, persistent pulmonary hypertension in the newborn period, and feeding difficulties resulting in gastrostomy tube placement. Of note, she had a previous pulmonary haemorrhage 2 years prior to this admission which self-resolved.

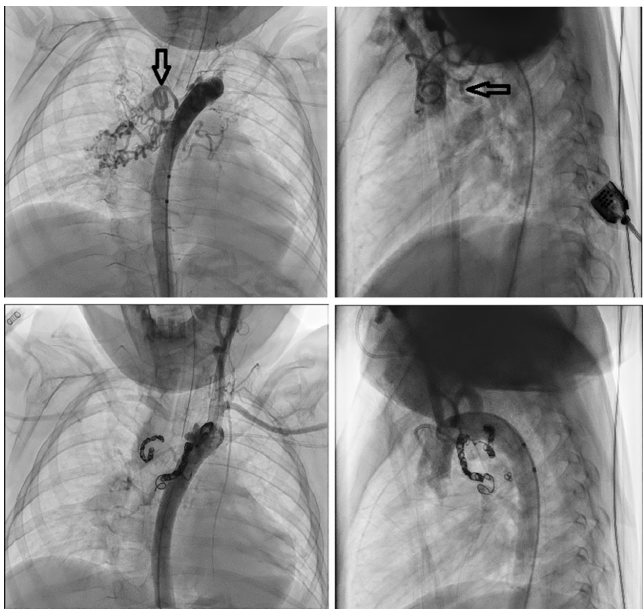
On presentation, her vitals were stable except for intermittent episodes of desaturation to 80% on room air. She had mild tachypnoea with coarse breath sounds bilaterally on auscultation. She had a small laceration on her tongue. Her labs were normal with haemoglobin of 12 g/dl. The chest X-ray in the emergency department initially showed collapse of the right lung, which showed improved aeration and multifocal right lung infiltrates after non-invasive positive pressure ventilation, suggesting either aspiration of blood or atelectasis. She was admitted to the cardiac intensive care unit and underwent a direct laryngoscopy and upper gastrointestinal endoscopy, both of which did not show any significant abnormality. The patient continued to have desaturation episodes requiring escalation of non-invasive positive pressure ventilation and was noted to have bloody secretions from her mouth and nose. A CT angiogram of chest/abdomen was performed to identify the source of persistent bleeding.

The CT angiogram revealed complete right upper lobe opacification and a remarkable burden of systemic-to-pulmonary artery collaterals supplying the right upper lobe (Fig 1). The rest of the lung segments did not have extensive collateral burden. An echocardiogram showed normal left ventricular size and function and no signs of pulmonary hypertension. After a multidisciplinary discussion, decision was made to perform coil embolisation of collaterals followed by a right upper lobectomy as definitive treatment. Informed consent was obtained from the parents explaining the pathology, a high likelihood of recurrence

© The Author(s), 2024. Published by Cambridge University Press. This is an Open Access article, distributed under the terms of the Creative Commons Attribution licence (<http://creativecommons.org/licenses/by/4.0/>), which permits unrestricted re-use, distribution and reproduction, provided the original article is properly cited.



**Figure 1.** CT angiogram of chest/abdomen showing extensive systemic-to-pulmonary collaterals and right upper lobe infiltrate.



Hollow black arrows mark large collaterals in anteroposterior and lateral views.

**Figure 2.** Catheterisation and embolization of systemic-to-pulmonary arterial collaterals. Hollow black arrows mark large collaterals in anteroposterior and lateral views.

with only catheter-based interventions, and possibility of pulmonary haemorrhage originating from other areas of either lung in the future.

Three distinct systemic-to-pulmonary collaterals were embolized in the cardiac catheterisation lab in preparation for the surgery (Fig 2). The patient was taken to the operating room four days after the embolization. A right upper lobectomy was performed through a right thoracotomy. Intra-operative findings included evidence of haemorrhage in the right upper lobe and significantly dilated and tortuous vessels running along the bronchi. The patient was extubated in the operating room and returned to the cardiac ICU. Her post-operative course was uneventful except for a post-chest tube removal pneumothorax, which required percutaneous pigtail catheter placement. The pathology showed areas of atelectasis with

increased haemosiderin deposition suggestive of old haemorrhage and abnormally hypertrophied arterial vessels characteristics of systemic-to-pulmonary arterial malformations.

## Discussion

Severe pulmonary haemorrhage is a life-threatening manifestation of systemic-to-pulmonary artery collaterals in *KCNT1* mutation carriers. Even after multiple catheter-based interventions, these patients can have recalcitrant pulmonary haemorrhage, which may result in repeated hospitalizations or death.<sup>4,5</sup> In a young child with developmental delay, pulmonary haemorrhage may masquerade as epistaxis or haematemesis. A high index of suspicion is required to diagnose and treat pulmonary haemorrhage in these patients. A CT angiogram of chest is an excellent study to locate the source of haemorrhage in these patients.

Even though embolization has been described as first-line treatment, the recurrence of pulmonary haemorrhage in *KCNT1* mutation carriers after several catheter-based interventions mandates more definitive intervention. Pulmonary haemorrhage arises from bronchial arteries and systemic-to-pulmonary artery collaterals. In various lung pathologies causing pulmonary haemorrhage, it is well established that lobectomy offers definitive treatment. However, it has not been reported as a treatment option in *KCNT1* mutation carriers. In this case report, we present lobectomy as a definitive treatment option for pulmonary haemorrhage in *KCNT1* mutation carriers, particularly those with pathology localised to a single pulmonary lobe.

We performed pre-operative embolization of the collaterals to decrease the risk of significant haemorrhage during the lobectomy. Despite large collaterals, we were able to keep the blood loss at a minimum. The patient had an uncomplicated post-operative course except for post-chest tube removal pneumothorax and went home on room air. Lobectomy was well tolerated in this patient. After 3 months of follow-up, the patient continues to do well and has not had another further episode of haemoptysis.

## Conclusion

Pulmonary haemorrhage due to aortopulmonary collaterals is a life-threatening complication in a subset of *KCNT1* mutation carriers. Although catheter-based interventions may temporise the pathology, recurrence is common and can potentially be fatal. In recurrent cases, particularly those with a majority of aortopulmonary collaterals limited to a single lung lobe, pulmonary lobectomy could be the definitive treatment option and can be lifesaving.

**Acknowledgements.** None.

**Financial support.** This research received no specific grant from any funding agency, commercial, or not-for-profit sectors.

**Competing interests.** None.

**Ethical standard.** This research does not involve human and/or animal experimentation.

## References

1. Quraishi IH, Stern S, Mangan KP, et al. An epilepsy-associated *KCNT1* mutation enhances excitability of human iPSC-derived neurons by increasing slack K Na currents. *J Neurosci* 2019; 39: 7438–7449.

2. Lim CX, Ricos MG, Dibbens LM, Heron SE. *KCNT1* mutations in seizure disorders: the phenotypic spectrum and functional effects. *J Med Genet* 2016; 53: 217–225.
3. Kohli U, Ravishankar C, Nordli D. Cardiac phenotypic spectrum of *KCNT1* mutations. *Cardiol Young* 2020; 30: 1935–1939.
4. Kawasaki Y, Kuki I, Ehara E, et al. Three cases of *KCNT1* mutations: malignant migrating partial seizures in infancy with massive systemic to pulmonary collateral arteries. *J Pediatr* 2017; 191: 270–274.
5. Ikeda A, Ueda H, Matsui K, Iai M, Goto T. Recurrent pulmonary hemorrhage in juvenile patients with *KCNT1* mutation. *Pediatr Int* 2021; 63: 352–354.