

# Neuroimaging Highlight

Editor: David Pelz

## Bilateral Type II Persistent Proatlantal Intersegmental Arteries

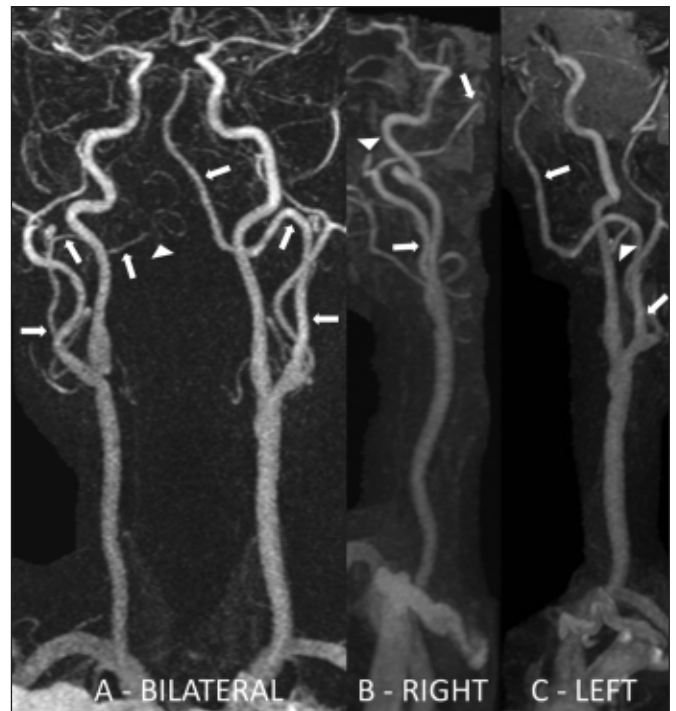
Submitted by: Ranjith K. Menon, Rick H. Swartz, Richard I. Aviv, Sean P. Symons

Can J Neurol Sci. 2013; 40: 873-874

A 64-year-old man with treated hypertension presented with acute left arm and leg weakness. A brain magnetic resonance imaging (MRI) and neck magnetic resonance angiography (MRA) were performed. There was restricted diffusion in the right internal capsule posterior limb consistent with an acute lacunar infarct. The MRA demonstrated aplastic bilateral cervical vertebral arteries (V1 and V2 segments). Bilaterally, a variant artery arose from the external carotid just above its origin, extended superiorly then medially, and forming the vertebral artery (V3 and V4 segments). Bilaterally, the occipital artery arose from the variant artery at the juncture where it turned medially. The right variant artery terminated intracranially in the right posterior inferior cerebellar artery. The left variant artery continued intracranially to supply the basilar. The appearance was consistent with bilateral persistent proatlantal intersegmental arteries (PPIA) type II.

### DISCUSSION

In the 4 mm embryo, the carotid and basilar circulations anastomose through transitory interconnecting segmental vessels. These serve as anastomoses between the primitive carotid arteries and bilateral longitudinal neural arterial plexus which are precursors to the basilar artery.<sup>1</sup> The intracranial segmental arteries are named according to the cranial nerves they correspond with (trigeminal, otic, and hypoglossal).<sup>2</sup> When the posterior communicating arteries form, these intracranial carotid-basilar anastomoses regress. There are eight extracranial anastomosing segments. As the vertebral bodies develop, these arteries become intersegmental and are numbered to their corresponding vertebral bodies. The first intersegmental artery corresponds to the proatlans (a rudimentary vertebral structure found occasionally in man located between the atlas and occipital bone), and is called the proatlantal intersegmental artery. The next seven cervical intersegmental arteries arise from the dorsal aorta, with the first intersegmental artery arising from below the C1 vertebral body. The vertebral arteries arise between seven to eight weeks when the intersegmental arteries anastomose longitudinally. The distal part of the proatlantal



**Figure:** (A) Bilateral coronal MRA of the neck. No vertebral arteries are seen arising from the subclavian arteries. Bilaterally, a variant artery (arrows) arises from the external carotid just above its origin, extends superiorly, turns medially, and forms the vertebral artery (V3 and V4 segments). The right variant artery terminates intracranially in the right posterior inferior cerebellar artery (arrowhead). The left variant artery continues intracranially to supply the basilar. (B) Right oblique MRA of the neck. The variant artery (arrows) is again seen arising from the external carotid artery, extending superiorly, turns medially, and forms the vertebral artery. The right occipital artery (arrowhead) can be seen arising from this variant artery as it curves medially. (C) Left oblique MRA of the neck. The variant artery (arrows) is again seen arising from the external carotid artery, extending superiorly, turns medially, forms the vertebral artery, and continues on to supply the basilar artery. The left occipital artery (arrowhead) can be seen arising from this variant artery as it curves medially.

From the Division of Neurology, Department of Medicine (RKM, RHS), Division of Neuroradiology, Department of Medical Imaging (RIA, SPS), Department of Otolaryngology – Head & Neck Surgery (SPS), Sunnybrook Health Sciences Centre, University of Toronto, Toronto, Ontario, Canada.

RECEIVED FEBRUARY 13, 2013. FINAL REVISIONS SUBMITTED MAY 31, 2013.

Correspondence to: Sean Symons, Division of Neuroradiology, Department of Medical Imaging, Sunnybrook Health Sciences Centre, Departments of Medical Imaging and Otolaryngology - Head & Neck Surgery, University of Toronto, 2075 Bayview Avenue, AG31D, Toronto, Ontario, M4N 3M5, Canada. Email: sean.symons@sunnybrook.ca.

intersegmental artery forms the distal segment of the vertebral artery. The horizontal segments of the first six cervical intersegmental arteries disappear. The seventh intersegmental arteries form the subclavian arteries.

Persistent fetal carotid-basilar anastomoses are rare. The incidence of a persistent trigeminal artery is 0.03% to 2.2%, and that of a hypoglossal artery is 0.027% to 0.26%.<sup>3</sup> There are no published data available on the incidence of a PPIA. There is controversy as to whether otic arteries actually exist.<sup>4,5</sup>

There are two types of PPIA. Type I arises from the internal carotid artery at the level of C2-3, avoids the transverse foramen of cervical vertebrae and courses directly upward into the occipitoatlantal space. It then travels intracranially through the foramen magnum and joins the ipsilateral vertebral artery. Type II arises laterally from the external carotid artery, joins with the ipsilateral vertebral artery between the first and second cervical vertebrae, and travels through the transverse foramen of atlas. Either may give rise to the occipital artery. When persistent, there is hypoplasia of one or both vertebral arteries in 50% of cases.<sup>6</sup> Unilateral PPIA is commoner than bilateral.

Persistent carotid-basilar anastomoses are most often incidental and benign.<sup>7</sup> Carotid atherosclerotic disease could lead to posterior circulation ischemia. Awareness of this variant is clinically important to surgeons. PPIA are potentially at risk for injury during carotid endarterectomy (particularly type I), C1-2 fixations, external carotid ligations, and other head and neck surgeries. It is important that diagnostic neuroradiologists detect and report this variant; and that endovascular neuroradiologists and neurosurgeons are aware of this variant before intervening. Anomalies associated with PPIA include intracranial aneurysm, arteriovenous malformation, other persistent carotid-basilar anastomoses, and vein of Galen malformation.

Differentiating a PPIA from a persistent hypoglossal artery can be radiologically challenging. The hypoglossal artery arises from the internal carotid artery at C1 but lacks the suboccipital horizontal path which the PPIA takes.

To our knowledge, seven cases of bilateral PPIA have been reported; two cases of type I<sup>6,8</sup>, and five cases of type II<sup>9-13</sup>. One case of bilateral type II was associated with a vein of Galen malformation<sup>12</sup>, and another with a ruptured intracranial aneurysm<sup>11</sup>.

## REFERENCES

1. Vasović L, Arsić S, Vljaković S, et al. Otic artery: a review of normal and pathological features. *Med Sci Monit.* 2010;16(5): RA101-9.
2. Caldemeyer KS, Carrico JB, Mathews VP. The radiology and embryology of anomalous arteries of the head and neck. *AJR Am J Roentgenol.* 1998;170(1):197-203.
3. Vasović L, Jovanović I, Ugrenović S, Vljaković S, Jovanović P, Stojanović V. Trigeminal artery: a review of normal and pathological features. *Childs Nerv Syst.* 2012;28(1):33-46.
4. Tubbs RS, Verma K, Riech S, et al. Persistent fetal intracranial arteries: a comprehensive review of anatomical and clinical significance. *J Neurosurg.* 2011 Apr;114(4):1127-34.
5. Bhattacharya JJ, Lamin S, Thammaroj J. Otic or mythic? *AJNR Am J Neuroradiol.* 2004 Jan;25(1):160-2; author reply 162.
6. Gumus T, Onal B, Ilgit ET. Bilateral persistence of type 1 proatlantal arteries: report of a case and review of the literature. *AJNR Am J Neuroradiol.* 2004;25(9):1622-4.
7. Tanaka Y, Hara H, Momose G, Kobayashi S, Kobayashi S, Sugita K. Proatlantal intersegmental artery and trigeminal artery associated with an aneurysm. *J Neurosurg.* 1983;59(3):520-3.
8. Woodcock RJ, Cloft HJ, Dion JE. Bilateral type 1 proatlantal arteries with absence of vertebral arteries. *AJNR Am J Neuroradiol.* 2001;22(2):418-20.
9. Lode I. Persistence of both proatlantal arteries with occlusion of the internal carotid arteries. A case report. *Acta Radiol.* 2000;41(5): 410-1.
10. Lui CC, Lui YH, Wai YY, Tsai CC. Persistence of both proatlantal arteries with absence of vertebral arteries. *Neuroradiology.* 1987; 29(3):304-5.
11. Kurose K, Kishi H, Nishijima Y. Type 2 proatlantal artery associated with a ruptured aneurysm - case report. *Neurol Med Chir (Tokyo).* 1990;30(3):191-3.
12. Purkayastha S, Gupta AK, Varma R, Kapilamoorthy TR. Proatlantal intersegmental arteries of external carotid artery origin associated with Galen's vein malformation. *AJNR Am J Neuroradiol.* 2005;26(9):2378-83.
13. Zarghouni M, Marichal D. Persistent bilateral proatlantal type II artery. *Proc (Bayl Univ Med Cent).* 2013;26(1):50-1.