

general quality indicators for Emergency Medicine, applicable to all countries and health care systems.

It then remains to be seen whether the institution of Emergency Medicine as a separate medical specialty is the way to go to achieve the aforementioned goals. This may be the case for some countries in Europe, but not for others, depending on many factors.

Like for Intensive Care Medicine, the multidisciplinary input from various specialties is considered essential to achieve high-quality care in Emergency Medicine. This multidisciplinary input threatens to be lost by the institution of a separate specialty. We do agree with the authors of the correspondence: let us not forget the history of medicine. Too widespread a specialization in medicine has created barriers in the past, which have not served well for the quality of care for our patients. However, mutual stimulation, mutual respect, communication and cooperation are characteristics which we do have!

E. De Robertis
Department of Anaesthesia and Intensive Care Medicine
University of Napoli Federico II
Napoli, Italy

J. T. A. Knafe
Department of Anesthesiology
University Medical Center Utrecht
Utrecht, The Netherlands

J. McAdoo
Department of Anaesthesia and Intensive Care Medicine
Cork University Hospital
Cork, Ireland

R. Pagni
Department of Anaesthesia and Intensive Care Medicine
Salesi Children's Hospital
Ancona, Italy

A benign cause for a unilateral dilated pupil in a critical care patient

doi:10.1017/S0265021508003840

EDITOR:

'Anisocoria' (a unilateral dilated pupil) in critical care patients is a point of concern, which warrants a thorough examination and often, also, costly investigations to rule out a serious cause. We however, encountered a patient in our intensive therapy unit who had a more benign reason.

Case report

A 38-yr-old female patient presented to hospital with acute severe asthma. She was subsequently admitted to the critical care unit requiring intubation and positive pressure ventilation, back-to-back salbutamol and ipratropium nebulizers along with intravenous aminophylline and hydrocortisone. After 8 h of the above treatment her bronchospasm settled and she was extubated uneventfully. A few minutes later though, her nurse noticed that whilst her right pupil was both normal in size and in responsiveness to light, her left pupil was fully dilated. A prompt central and

peripheral nervous system examination was unremarkable. But a further detailed examination revealed that the patient was receiving her salbutamol and ipratropium through an in-circuit nebulizer system, which not only was closer to the left side of her face but also had a small leak in it.

Discussion

Ipratropium bromide is known to cause 'mydriasis' (pupillary dilation) due to its antagonizing acetylcholine at the cholinergic receptors in the eye [1]. Furthermore, the effects of ipratropium on pupils are usually due to local and not systemic absorption. Anisocoria caused by ipratropium nebulizers given via poorly fitting face masks were described in previous case reports [2]. In our case the cause of the leak of ipratropium was from an in-circuit nebulizer system. A quick and thorough bedside examination and early detection of the source of the problem saved us from performing more invasive and costly investigations.

H. P. Krovvidi, A. Thillaivasan
Anaesthetics
Russells Hall Hospital
Dudley, UK

Correspondence to: Hari Prasad Krovvidi, Anaesthetics, Russells Hall Hospital, Dudley, DY1 2HQ, UK. E-mail: haridoc6@gmail.com; Tel: +44 121 6940449; Fax: +44 1384 2244051

Accepted for publication 18 January 2008 EJA 4914
First published online 13 March 2008

References

1. Jannun DR, Mickel SF. Anisocoria and aerosolised anti-cholinergics. *Chest* 1986; 90: 148–149.
2. Helprin GA, Clarke GM. Unilateral fixed dilated pupil associated with nebulised ipratropium bromide. *Lancet* 1986; 2: 1469.

Pitfall in interpretation of TEG results

doi:10.1017/S0265021508004146

EDITOR:

Thromboelastograph (TEG) displays the viscoelastic properties [1] of the clot formed, which in turn reflects the functions of different factors involved in the coagulation process [2] and also the interaction between these factors. TEG is considered to be better than the conventional coagulation tests

[3] and is becoming more popular among peri-operative clinicians in managing coagulopathies. TEG machines are often located away from the theatre where surgery takes place (often placed near cardiac/vascular theatre or cardiac ICU). When TEG is performed away from where patients are treated, results are often conveyed to treating clinicians by

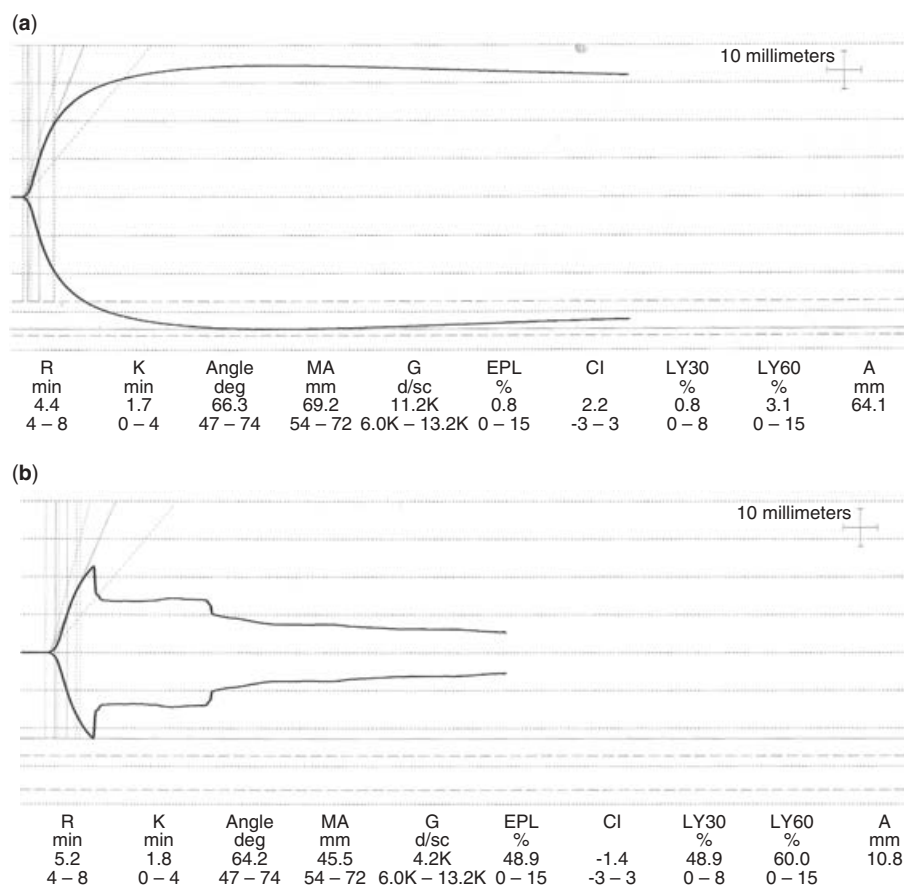


Figure 1.

TEG graphs: (a) normal – heparinase cup (b) abnormal – plain cup.

Correspondence to: Ravish Jeeji, 8 Rotherhead close, Horwich, BL6 5UG, UK. E-mail: ravishjeeji@hotmail.com; Tel/Fax: +1 204 669883

Accepted for publication 24 February 2008 EJA 4925

First published online 10 April 2008