

improves identification; to investigate and manage identified cases of SD; to make recommendations about identification and monitoring of SD in this patient population.

**Methods:** A 12-month retrospective audit of patients with psychosis prescribed a long-acting injectable (LAI) antipsychotic (n=36) to identify sexual symptoms was completed. The ASEX was subsequently issued to screen for SD.

**Results:** Audit: 3/36 (8%) patients had documented sexual symptoms. Of the 18/36 patients that completed the ASEX: 10 (56%) exhibited SD. 4 consented to further investigation. 5 patients experienced significant difficulties with the language used in the ASEX. At the end of the project we revised the ASEX with simpler, colloquial language.

**Conclusions:** Implementation of the ASEX results in clear improvements in identification and monitoring of SD. Maudsley Practice Guidelines can inform investigation and management of SD. We suggest a review of NICE guidance to incorporate the above into clinical practice. Further work is needed to establish whether the revised ASEX can be developed and validated.

**Disclosure of Interest:** None Declared

## EPV0946

### Male gynecomastia linked to antipsychotics: a case report

O. Martin-Santiago<sup>1\*</sup>, P. Martinez.Gimeno<sup>1</sup>, M. Calvo-Valcarcel<sup>1</sup>, C. Alario-Ruiz<sup>1</sup> and B. Arribas-Simon<sup>1</sup>

<sup>1</sup>Hospital Clinico Universitario, Valladolid, Spain

\*Corresponding author.

doi: 10.1192/j.eurpsy.2024.1537

**Introduction:** Gynecomastia refers to the abnormal development of breast tissue in males, often posing a concerning symptom. Often, gynecomastia is associated with multiple factors, including the use of various drugs, notably certain atypical antipsychotics. Gynecomastia is a significant side effect that affects the quality of life of male patients taking antipsychotic medications. Among these, risperidone and paliperidone have been identified as the most prone to causing gynecomastia, although aripiprazole has garnered attention for its superior profile in controlling prolactin and gynecomastia. The relationship between these drugs and the development of gynecomastia lies in their ability to elevate prolactin levels, a hormone that regulates reproductive function and is involved in milk production. Several studies have shown that prolactin levels are more commonly elevated with risperidone and paliperidone prescription, thus triggering gynecomastia.

**Objectives:** The study aims to investigate the management of gynecomastia in male patients receiving antipsychotic medications.

**Methods:** This research employs a retrospective analysis of patient records to examine the association between specific antipsychotic drugs, prolactin levels, and the development of gynecomastia, while also evaluating the effectiveness of aripiprazole as an alternative treatment.

**Results:** We present the case of a 21-year-old male with no prior medical history who initiated treatment with oral paliperidone and later switched to 100 mg of long-acting injectable paliperidone once

monthly during his initial admission for psychotic symptoms. After six months, he developed gynecomastia, which was ruled out as breast tissue and was determined to be an increase in adipose tissue. Since his hospital discharge, he has gained 25 kg (30%) in body weight, and his baseline prolactin level has decreased. This weight gain, a common side effect of several antipsychotics, was linked to gynecomastia. However, a promising approach for gynecomastia antipsychotic-associated treatment is aripiprazole, which has a milder impact on prolactin levels. In this case, during the next appointment, a switch to 400 mg of long-acting injectable aripiprazole once-monthly was made, which led to weight loss, a reduction in breast size and blood prolactin levels in the following weeks.

**Conclusions:** The detection and management of gynecomastia in these patients are crucial to improving their quality of life and treatment adherence. This management encompasses changes in medication, hormonal therapy, or surgery in severe cases. Physicians must be aware of this potential complication when prescribing antipsychotics and closely monitor at-risk patients. In summary, antipsychotic-associated gynecomastia in men represents a medical challenge that requires careful attention and an individualized treatment strategy for each affected patient.

**Disclosure of Interest:** None Declared

## EPV0947

### The role of cannabis and salience alterations in determining the severity of psychotic symptoms: a multi-centric, cross-sectional study on adolescent and adult cohorts

O. Baccaredda Boy<sup>1</sup>, G. P. Merola<sup>1</sup>, A. Patti<sup>1</sup>, I. Fascina<sup>1</sup>, B. Bozza<sup>1</sup>, D. Flaccomio<sup>1</sup>, M. Faldi<sup>1</sup>, G. Pitt<sup>1</sup>, I. Noschese<sup>1</sup>, L. Papini<sup>1</sup>, D. Brugnolo<sup>1</sup>, C. Ricci<sup>1\*</sup>, V. Pecoraro<sup>1</sup>, A. Ballerini<sup>1</sup>, V. Ricca<sup>1</sup>, F. Mauceri<sup>1</sup>, G. Peroni<sup>1</sup>, S. Tavano<sup>1</sup>, T. Pisano<sup>1</sup>, F. De Cesaris<sup>1</sup>, S. Gori<sup>1</sup> and D. Cohen<sup>2</sup>

<sup>1</sup>University of Florence, Florence, Italy and <sup>2</sup>Department of Pitié Salpêtrière, University of Sorbonne, Paris, France

\*Corresponding author.

doi: 10.1192/j.eurpsy.2024.1538

**Introduction:** The aim of this project is to study to which extent salience alterations influence the severity of psychotic symptoms. However, rather than studying them individually, we decided to focus on their interplay with two additional variables, that is: observing their effect in a vulnerability phase (adolescence) and with another added, well-recognized risk factor (cannabis use).

The reason for this study design lies in the fact that, in our opinion, it is fundamental to observe the trajectory of psychotic symptoms over a continuum; however, rather than adopting a longitudinal approach, we decided to structure it as a cross-sectional study confronting patients from two age brackets - adolescence and adulthood.

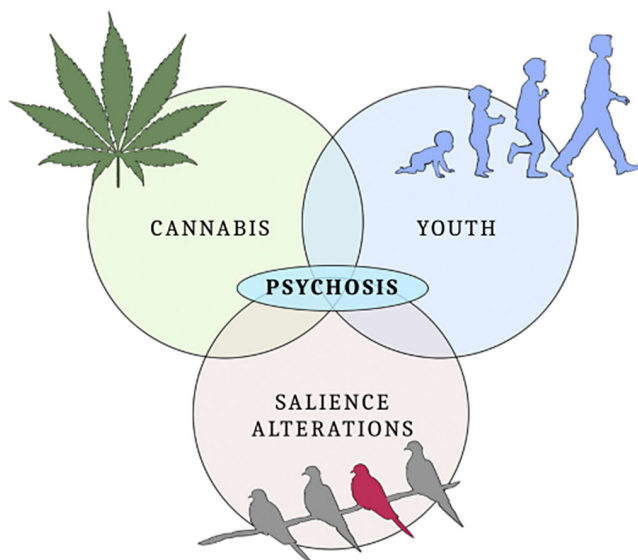
**Objectives:** The primary purpose of this study was to assess a difference between THC-abusing and non-abusing patients in adolescent and adult cohorts, using the Italian version of the psychometric scale "Aberrant Salience Inventory" (ASI), and the possible

correlation with more severe psychotic symptoms. The employment of several different psychometric scales and the inclusion of a variegated cohort allowed to pursue multiple secondary objectives.

**Methods:** We recruited 192 patients, subsequently divided into six subgroups based on age and department of recruitment (whether adolescent or adult psychiatric or neurologic units - the latter serving as controls). Each individual was administered a set of questionnaires and a socio-demographic survey; the set included: Aberrant Salience Inventory (ASI), Community Assessment of Psychic Experiences (CAPE), Positive and Negative Syndrome Scale (PANSS), Montgomery-Asberg Depression Rating Scale (MADRS), Mania Rating Scale (MRS), Hamilton Anxiety Scale (HAM-A), Association for Methodology and Documentation in Psychiatry (AMDP) and Cannabis Experience Questionnaire (CEQ).

**Results:** The data analysis showed statistically significant ( $p < 0.05$ ) differences between adolescents and adults with psychotic symptoms in all of the three scales of PANSS and in MADRS. These two groups were homogenous for both cannabis use and ASI score. The intra-group comparison (either adolescent or adult) showed a hierarchical pattern in the scores of psychometric scales according to the diagnostic subgroup of allocation: patients with psychotic symptoms showed a higher level of psychopathology in all measures when compared to patients from the psychiatric unit without psychotic symptoms, which in turn scored higher than the patients from the neurologic unit.

**Image:**



**Conclusions:** The results of the present study may suggest that when salience alterations occur in adolescents with cannabis exposure, we might observe worsened positive and negative psychotic symptoms; their influence might be relevant also in other domains, especially regarding the depressive and anxiety spectrums.

**Disclosure of Interest:** None Declared

## EPV0948

### “God speaks to me through a dove”. The evidence of clozapine in treatment-refractory psychosis

B. Rodríguez Rodríguez<sup>1</sup>, P. Marqués Cabezas<sup>1\*</sup>, M. Queipo de Llano de La Viuda<sup>1</sup>, N. Navarro Barriga<sup>1</sup>, G. Guerra Valera<sup>1</sup>, M. B. Arribas Simón<sup>1</sup>, C. Alario Ruiz<sup>1</sup>, M. J. Mateos Sexmero<sup>1</sup>, M. Fernández Lozano<sup>1</sup>, P. Marínez Gimeno<sup>1</sup>, M. Calvo Valcárcel<sup>1</sup>, M. A. Andreo Vidal<sup>1</sup>, M. P. Pando Fernández<sup>1</sup>, A. Monllor Lazarraga<sup>1</sup>, M. Ríos Vaquero<sup>1</sup>, G. Lorenzo Chapate<sup>1</sup>, L. Rojas Vázquez<sup>1</sup>, C. De Andrés Lobo<sup>1</sup>, T. Jiménez Aparicio<sup>2</sup> and M. D. C. Vallecillo Adame<sup>1</sup>

<sup>1</sup>Psiquiatría, Hospital Clínico Universitario de Valladolid, Valladolid and <sup>2</sup>Psiquiatría, Hospital Clínico Universitario de Valladolid, Valladolid<sup>o</sup>, Spain

\*Corresponding author.

doi: 10.1192/j.eurpsy.2024.1539

**Introduction:** Clozapine is an atypical antipsychotic synthesised in 1958. It was withdrawn from the market in the 1970s due to the appearance of agranulocytosis, but was reintroduced due to strong evidence of its efficacy and superiority over other antipsychotics in treatment-resistant schizophrenia.

**Objectives:** To describe the adequate response to clozapine in treatment-refractory psychosis.

**Methods:** Review of the scientific literature based on a relevant clinical case.

**Results:** A 16-year-old woman was admitted to a psychiatric inpatient unit for psychotic symptoms and behavioural disorders. She lives with her father and older sister; she has not been in contact with her mother, who lives in another country, for several years. She attends secondary school, with poor academic performance. Maternal diagnosis of schizophrenia. She started using cannabis two years ago, with a progressive increase up to 20 grams per week. He reports the onset of a feeling of strangeness a year ago, with progressive isolation in his room, referring to delirious ideation of harm towards classmates and people from his town, self-referentiality and delirious interpretations of religious mystical content (“God speaks to me through a dove”). He comments on the phenomenon of theft and thought-reading. Soliloquies and unmotivated laughter are observed.

**Conclusions:** Treatment was started with risperidone, progressively increasing the dose up to optimisation, without achieving a decrease in positive symptoms, but with the appearance of excessive sedation and sialorrhoea. It was combined with aripiprazole up to 20mg, maintained for a couple of weeks, without significant clinical improvement. Given the failure of two lines of therapy, it was decided to change to clozapine up to a dose of 75mg, with adequate tolerance and response, achieving a distancing of the delirious ideation. Regular haematological controls were performed, with no alterations in haemogram or troponins.

**Disclosure of Interest:** None Declared