

Research Article

Cite this article: Vanstreels RET *et al* (2023). *Haemoproteus jenniae* (Haemoproteidae, Haemosporida) infects gulls (*Larus* spp.) in South Africa, with redescription of *Haemoproteus skuae*. *Parasitology* **150**, 1286–1295. <https://doi.org/10.1017/S003118202300029X>

Received: 17 November 2022

Revised: 6 March 2023

Accepted: 10 March 2023

First published online: 23 March 2023

Keywords:




Blood parasite; *Haemoproteus*; Hippoboscidae; *Larus*; seabird; vector-borne pathogen

Author for correspondence:

Ralph E. T. Vanstreels,

E-mail: ralph_vanstreels@yahoo.com.br

Haemoproteus jenniae (Haemoproteidae, Haemosporida) infects gulls (*Larus* spp.) in South Africa, with redescription of *Haemoproteus skuae*

Ralph E. T. Vanstreels¹ , Carolina R. F. Chagas² , Gediminas Valkiūnas², Carolina C. dos Anjos³, Nola J. Parsons⁴, David G. Roberts⁴, Albert Snyman⁴, Renata Hurtado⁴, Karin Kirchgatter^{3,5} , Katrin Ludynia⁴ and Pierre A. Pistorius¹

¹Marine Apex Predator Research Unit (MAPRU), Department of Zoology, Nelson Mandela University, Gqeberha, South Africa; ²Nature Research Centre, Institute of Ecology, Vilnius, Lithuania; ³Faculdade de Medicina, Instituto de Medicina Tropical, Universidade de São Paulo, São Paulo, Brazil; ⁴Southern African Foundation for the Conservation of Coastal Birds (SANCCOB), Cape Town, South Africa and ⁵Instituto Pasteur, São Paulo, Brazil

Abstract

Haemoproteus spp. are dipteran-borne protozoa that infect erythrocytes and reticulo-endothelial cells of birds. These parasites are not usually transmitted between birds belonging to different orders. The suborder Lari (order Charadriiformes) comprises ~170 avian species, the majority of which are aquatic, including gulls, terns, auklets, murres and skuas, among others. In spite of the diversity of this avian group, there is limited known diversity of haemosporidian parasites, with only 4 recorded *Haemoproteus* morphospecies thus far. We examined the blood smears of 21 kelp gulls (*Larus dominicanus*) captured at a breeding colony in South Africa, as well as *Haemoproteus*-positive archival blood smears of 15 kelp gulls and 1 Hartlaub's gull (*Larus hartlaubii*) sampled while under care at seabird rehabilitation facilities in South Africa. *Haemoproteus* sp. infection was detected in 19% of wild-caught kelp gulls. All parasites from the gulls were morphologically identified as *Haemoproteus jenniae*, a species previously recorded in Lari birds at the Galapagos Islands (Ecuador), Rocas Atoll (Brazil) and Poland. Gene sequencing uncovered a new cytochrome *b* lineage, LARDOM01, which was closely related to the previously reported *H. jenniae* lineage CREFUR01. Additionally, we evaluated a hapantotype blood smear of *Haemoproteus skuae*, which had been described infecting a brown skua (*Catharacta antarctica*) in South Africa. We provide a redescription of *H. skuae* and discuss the morphological characters distinguishing it from *H. jenniae*. Further research is necessary to improve our knowledge about the host and geographic distribution, health effects and phylogeny of *H. jenniae* and *H. skuae*.

Introduction

Avian haemosporidian parasites comprise species of the genera *Haemoproteus*, *Plasmodium*, *Leucocytozoon* and *Fallisia* (Valkiūnas, 2005; Perkins, 2014). *Haemoproteus* spp. are parasites of avian erythrocytes and reticulo-endothelial cells of numerous internal organs. These parasites can be distinguished from other avian haemosporidians by the presence of malarial pigment granules (haemozoin) in blood stages and the absence of asexual reproduction (merogony) in circulating blood cells (Valkiūnas, 2005). Species of this genus are classified into 2 subgenera according to the differences in their sporogony and dipteran vectors. Representatives of the subgenus *Haemoproteus* are transmitted by louse flies (Hippoboscidae) and produce large-size oocysts containing numerous germinative centres. Representatives of the subgenus *Parahaemoproteus* are transmitted by biting midges (Ceratopogonidae) and produce tiny oocysts containing only 1 germinative centre (Valkiūnas, 2005). *Haemoproteus* species are generally presumed to be host-specific. They are not usually transmitted between birds belonging to different orders, and there is limited evidence that some species are host-specific to the family level (Valkiūnas, 2005). However, there are some notable exceptions to this rule, as demonstrated by penguins (Sphenisciformes: Spheniscidae) infected by *Haemoproteus larae*, which is a common parasite of gulls (Charadriiformes: Laridae) (Inumaru *et al.*, 2020).

Charadriiformes is a diverse order of birds, comprising nearly 400 species distributed in 19 families (Gill *et al.*, 2022). The suborder Lari comprises 6 families, including aquatic birds in the families Laridae (gulls, terns, noddies, skimmers; 103 species), Alcidae (auklets, murres, puffins; 25 species), Stercorariidae (skuas; 7 species) and Dromadidae (crab-plover; 1 species), as well as terrestrial birds in the families Turnicidae (buttonquails; 18 species) and Glareolidae (coursers, pranticoles; 17 species) (Cracraft *et al.*, 2003; Ericson *et al.*, 2003; Gill *et al.*, 2022). In spite of the species diversity of the suborder Lari, a relatively small diversity of haemosporidian parasites has been recorded infecting these birds (Valkiūnas, 2005; Quillfeldt *et al.*, 2011; Clark *et al.*, 2014). This may be related to a smaller sampling effort compared to other more

© The Author(s), 2023. Published by Cambridge University Press. This is an Open Access article, distributed under the terms of the Creative Commons Attribution-NonCommercial-ShareAlike licence (<http://creativecommons.org/licenses/by-nc-sa/4.0/>), which permits non-commercial re-use, distribution, and reproduction in any medium, provided the same Creative Commons licence is used to distribute the re-used or adapted article and the original article is properly cited. The written permission of Cambridge University Press must be obtained prior to any commercial use.

extensively studied avian groups (e.g. Passeriformes and Galliformes), but it could also relate to the fact that Lari bird species often inhabit either saltwater/brackish or arid environments where the insect vectors of haemosporidian parasites are often less abundant (Jovani *et al.*, 2001; Martínez-Abraín *et al.*, 2004; Quillfeldt *et al.*, 2011).

Four morphospecies of *Haemoproteus* have been detected infecting birds of the suborder Lari, in addition to several unidentified genetic lineages (Table 1). *Haemoproteus* (*Parahaemoproteus*) *larae* is a frequent parasite of several species of gulls (*Larus* spp.) and terns (*Sterna* spp.) in the Palearctic region (Kairullaev, 1986; Quillfeldt *et al.*, 2011; Inumaru *et al.*, 2017, 2020). *Haemoproteus* (*Haemoproteus*) *jenniae* infects swallow-tailed gulls (*Creagrus furcatus*) at the Galapagos Islands, Ecuador (Levin *et al.*, 2012), and its DNA was detected in the blood of brown noddies (*Anous stolidus*) at Rocas Atoll, Brazil (Quillfeldt *et al.*, 2014), and in the blood of black-headed gulls (*Larus ridibundus*) in Poland (Włodarczyk *et al.*, 2022). *Haemoproteus skuae*, for which the subgeneric position has not yet been determined, was described from a brown skua (*Catharacta antarctica*) sampled while under care at a rehabilitation facility in Cape Town, South Africa (Parsons *et al.*, 2010, 2017), and has not been recorded since its original description. Additionally, DNA from *Haemoproteus* (*Parahaemoproteus*) *macrovacuolatus* was detected in the blood of black skimmers (*Rynchops niger*) in Brazilian Amazon (Roos *et al.*, 2015); however, considering that *H. macrovacuolatus* is a frequent parasite of black-bellied whistling-ducks (*Dendrocygna autumnalis*) (Matta *et al.*, 2014), its occurrence in black skimmers could represent an abortive spill-over infection.

Although the blood parasites of Lari birds have been extensively studied in Eurasia and the Americas, the African continent remains understudied in this regard (Quillfeldt *et al.*, 2011; Parsons *et al.*, 2017). A recent study reported the detection of *Haemoproteus* sp. in the blood smears from kelp gulls (*Larus dominicanus*) at various breeding colonies in South Africa, with an average prevalence of 1.6% in chicks ($N = 121$) and 39.3% in adults ($N = 211$), however the parasite species was not identified (Reusch *et al.*, 2022). In this study, we report on the occurrence of *H. jenniae* in kelp gulls and Hartlaub's gull (*Larus hartlaubii*) in South Africa and complement the original description of *H. skuae* based on its type specimens. Blood stages of *H. jenniae* and *H. skuae* have similarities in morphology, and the characters that can be used to distinguish between these parasites are discussed.

Materials and methods

On 15 September 2012, adult kelp gulls were captured and blood samples were sampled at the breeding colony on Robben Island ($N = 21$; Western Cape, South Africa, 33°47'37"S, 18°21'47"E). The sampled individuals were selected at random and appeared to be healthy (good body condition, no injuries or deformities, normal behaviour and breathing). Additionally, we analysed archival blood samples collected in 2011–2018 from adult kelp gulls under care at rehabilitation facilities of the Southern African Foundation for the Conservation of Coastal Birds (SANCCOB) in Cape Town ($N = 13$; Western Cape, South Africa, 33°50'01"S, 18°29'29"E) and Port Elizabeth/Gqeberha ($N = 2$; Eastern Cape, South Africa, 34°00'48"S, 25°41'26"E), and 1 archival blood sample from an adult Hartlaub's gull collected in 2018 at the SANCCOB rehabilitation facility in Cape Town.

For all individuals, blood samples (<1% body mass) were collected from the medial metatarsal or brachial vein. Thin blood smears were freshly prepared, air dried, fixed with absolute methanol, stained with an eosin–methylene blue stain (Kyro-Quick stain set, Kyron Laboratories Pty Ltd, Benrose,

South Africa). Blood smears were examined under light microscopy. To estimate parasite prevalence, blood smears from the kelp gulls sampled at Robben Island were screened by examining 200 fields under 1000× magnification (minimum 50 000 erythrocytes).

Blood parasites were morphologically identified using published keys and descriptions (Valkiūnas, 2005; Parsons *et al.*, 2010; Levin *et al.*, 2012; Inumaru *et al.*, 2020) and were quantified with the assistance of digital image analysis to count 1000 erythrocytes (Gering and Atkinson, 2004). A high-resolution digital camera (AmScope MU1803-HS, United Scope LLC, Irvine, CA, USA) coupled to a light microscope was used to obtain photographs of parasites, and ImageJ 1.53a (Schneider *et al.*, 2012) was used to obtain measurements from uninfected erythrocytes ($n = 30$), macrogametocytes and their infected cells ($n = 30$), and microgametocytes and their infected cells ($n = 20$). The nucleus displacement ratio (NDR) was calculated (Bennett and Campbell, 1972). Mann–Whitney tests were conducted to compare the measurements of the parasites from kelp and Hartlaub's gulls. In order to perform proper morphological identification of the parasite found in the gulls, a hapantotype blood smear of *H. skuae*, deposited at the International Reference Centre for Avian Haematozoa (IRCAH), Queensland Museum (accession number G465379) (Parsons *et al.*, 2010), was analysed.

One archival sample from a kelp gull (identification number K035/2018, admitted for rehabilitation on 7 March 2018 from Saldanha Bay, 33°04'2"S, 17°56'34"E, and sampled on 26 March 2018 at the Cape Town facility) was selected for parasite measurements and molecular analysis. This sample was selected because the blood smears were of excellent quality and did not present co-infection by other blood parasites (as confirmed through the microscopic examination of 150 000 erythrocytes); a voucher blood smear from this sample was deposited at the collection of IRCAH under accession number G466232.

Total blood was stored at -20°C , and then was transferred to 100% ethanol. Approximately 10 μL of blood was transferred to a 1.5 mL microtube and dried at 37°C for subsequent DNA extraction using the phenol–chloroform method with isopropanol precipitation (Sambrook and Russell, 2001). A nested polymerase chain reaction (PCR) test targeting the mitochondrial cytochrome *b* (*cytb*) gene of *Haemoproteus* and *Plasmodium* was employed (Hellgren *et al.*, 2004). Amplification products of the *cytb* PCR were purified with polyethylene glycol 8000 (Sambrook and Russell, 2001), and sequenced (bi-directional Sanger sequencing with dye-terminator fluorescent labelling). The resulting DNA sequence was deposited in GenBank (accession number OL906299) and MalAvi (lineage code LARDOM01) and compared to publicly available *Haemoproteus* sequences from the MalAvi database (Bensch *et al.*, 2009).

Phylogenetic relationships were evaluated through a Bayesian phylogenetic tree produced using MrBayes 3.2.7 (Ronquist *et al.*, 2012) with the GTR + I + G model of nucleotide evolution as recommended by jModelTest 2 (Darriba *et al.*, 2012) and using reference *cytb* lineages from public databases (Supplementary File S1). Two Markov chains were run simultaneously for 5 million generations that were sampled every 1000 generations, and the first 1250 trees (25%) were discarded as a burn-in step. The tree was rooted with *Leucocytozoon* as an outgroup as recommended by multi-gene phylogenetic analyses (Borner *et al.*, 2016).

Due to the host's small body size, the archival sample from Hartlaub's gull (identification number H230/2018, admitted for rehabilitation on 7 June 2018 from Eden on the Bay, 33°47'35"S, 18°27'22"E, and sampled on 18 June 2018 at the Cape Town facility) did not have a corresponding aliquot of total blood that could be used for molecular analysis. DNA extraction

Table 1. Summary of *Haemoproteus* morphospecies and *cytb* lineages recorded in birds of the suborder Lari

Morphospecies	Lineage	Host	References
<i>Haemoproteus (Haemoproteus) jenniae</i>	CREFUR01	<i>Anous stolidus</i>	Quillfeldt <i>et al.</i> (2014)
		<i>Creagrus furcatus</i>	Levin <i>et al.</i> (2012)
		<i>Larus ridibundus</i>	Włodarczyk <i>et al.</i> (2022)
	LARDOM01	<i>Larus dominicanus</i>	This study
	Not determined	<i>Larus hartlaubii</i>	This study
<i>Haemoproteus (Haemoproteus) sp.^a</i>	JF833066 ^b	<i>C. furcatus</i>	Levin <i>et al.</i> (2011)
<i>Haemoproteus (Parahaemoproteus) larae</i>	LARCRA01 ^c	<i>Larus canus</i>	Inumaru <i>et al.</i> (2017)
		<i>Larus crassirostris</i>	Ishtiaq <i>et al.</i> (2007), Inumaru <i>et al.</i> (2017)
		<i>L. ridibundus</i>	Włodarczyk <i>et al.</i> (2022)
	LARCRA02	<i>L. crassirostris</i>	Inumaru <i>et al.</i> (2017)
	SPMAG12 ^d	<i>L. crassirostris</i>	Inumaru <i>et al.</i> (2020)
	Not determined	<i>Larus argentatus</i>	Valkiūnas (2005)
		<i>Larus audouinii</i>	Ruiz <i>et al.</i> (1995)
		<i>Larus cachinnans</i>	Bosch <i>et al.</i> (1997)
		<i>L. canus</i>	Krams <i>et al.</i> (2012)
		<i>Larus fuscus</i>	Peirce (1981)
		<i>L. ridibundus</i>	Franchini (1924), Yakunin (1972), Peirce (1981), Krams <i>et al.</i> (2012)
		<i>Sterna albifrons</i>	Kairullaev (1986)
	<i>Sterna hirundo</i>	Kairullaev (1986)	
<i>Haemoproteus (Parahaemoproteus) macrovacuolatus</i>	DENAUT01 ^e	<i>Rynchops niger</i>	Roos <i>et al.</i> (2015)
<i>Haemoproteus (Parahaemoproteus) sp.</i>	CYGNUS01 ^e	<i>Larosterna inca</i>	Spottiswoode <i>et al.</i> (2020)
	LARCAC01	<i>L. cachinnans</i>	Ricklefs and Fallon (2002)
	LARSCO01	<i>Leucophaeus scoresbii</i>	Quillfeldt <i>et al.</i> (2010)
<i>Haemoproteus skuae</i>	Not determined	<i>Catharacta antarctica</i>	Parsons <i>et al.</i> (2010), this study
<i>Haemoproteus sp.</i>	Not determined	<i>A. stolidus</i>	Lowery (1971)
		<i>C. furcatus</i>	Padilla <i>et al.</i> (2006)
		<i>L. cachinnans</i>	Martínez-Abraín <i>et al.</i> (2002)
		<i>L. ridibundus</i>	Berdyev (1979), Kairullaev (1986)
		<i>L. dominicanus</i>	Reusch <i>et al.</i> (2022)

^aPhylogenetic analysis suggests this lineage corresponds to the morphospecies *Haemoproteus (Haemoproteus) multipigmentatus*.

^bAlso recorded in Columbiformes.

^cAlso recorded in Falconiformes.

^dAlso recorded in Sphenisciformes.

^eAlso recorded in Anseriformes.

from the blood smear was not considered feasible due to the low parasitaemia. Instead, the blood smear from this sample was deposited at the collection of the IRCAH under accession number G466252.

Results

Haemoproteus sp. infection was detected in the blood smears of 4 of 21 (19.0%) wild kelp gulls sampled at Robben Island. The archived blood smears from 15 kelp gulls and 1 Hartlaub's gull under care at the rehabilitation facilities had been pre-selected for further study on the basis that they had *Haemoproteus sp.* infections, and therefore prevalence cannot be estimated for this cohort.

The blood smears of all 15 kelp gulls sampled at the rehabilitation facilities showed the presence of a single morphospecies, *H. jenniae* (Fig. 1). The Hartlaub's gull was also infected by *H. jenniae* (Fig. 2). The morphological identification of *H. jenniae* in both hosts was confirmed in blood smears due to the presence of the following diagnostic characteristics: (i) young gametocytes can be seen anywhere in the infected cells, but mainly on erythrocyte poles (Figs 1A and 2A) and can have a wavy to amoeboid outline (Figs 1B–G, Q and 2B, C, E, F); (ii) the presence of unstained spaces in the cytoplasm of young gametocytes (Figs 1D, E and 2D), even though they are less frequently seen in *H. jenniae* from Hartlaub's gull; (iii) the presence of 1 large vacuole in mature or nearly mature gametocytes (Figs 1D, E, N and 2J, M), also less frequent in *H. jenniae* from Hartlaub's

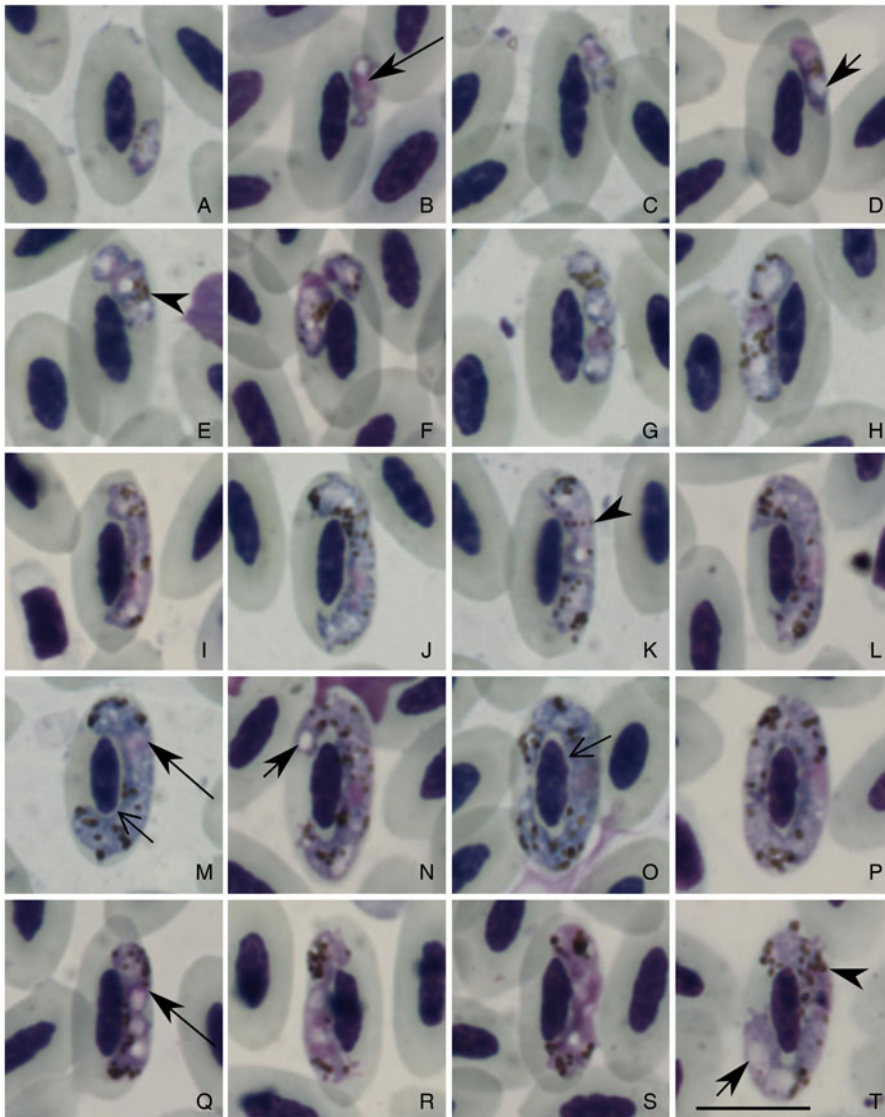


Fig. 1. *Haemoproteus jenniae* *cytb* lineage LARDOM1 from the blood of a kelp gull (*Larus dominicanus*). All images from the voucher specimen IRCAH accession number G466232. Young gametocytes (A–D), macrogametocytes (E–P) and microgametocytes (Q–T). Simple arrowhead, pigment granules; long simple arrow, parasite nucleus; short simple arrow, vacuole; long simple wide arrow, cleft between parasite and erythrocyte nucleus. Sample K035/2018, eosin–methylene blue stain. Scale bar = 10 μ m.

gull; (iv) growing gametocytes can slightly touch the parasite nucleus in several points (Figs 1I, K and 2C, F) or not touch it, forming thin clefts (Figs 1M, O and 2E); (v) fully grown gametocytes are circumnuclear, they occupy the entire cytoplasm of the infected cells (Figs 1P and 2K, L) and can slightly rotate the erythrocyte nuclei (Figs 1T and 2G, P); (vi) fully grown gametocytes contain predominantly roundish or slightly oval, of approximately uniform size pigment granules (elongate rod-like pigment granules usually are absent) (Figs 1P, T and 2L, O) and (vii) nuclei are diffuse in microgametocytes (Figs 1Q–T and 2M–P).

A detailed description of macrogametocytes and microgametocytes of *H. jenniae* (*cytb* lineage CREFUR01) was provided by Levin *et al.* (2012) and is not repeated here. However, it is necessary to mention that *H. jenniae* CREFUR01 induces hypertrophy of the infected erythrocytes in width, which is neither the case for the new *H. jenniae* LARDOM01 nor for the *H. jenniae* from Hartlaub's gull (Table 2). It is also noteworthy that the *H. jenniae* from Hartlaub's gull had generally smaller gametocytes and its macrogametocytes had more numerous pigment granules than those of *H. jenniae* LARDOM01 and *H. jenniae* CREFUR01 (Table 2). Mann–Whitney tests detected significant differences ($P < 0.05$) in the following measurements of *H. jenniae* LARDOM01 compared to *H. jenniae* from Hartlaub's gull: macrogametocyte length ($W = 703$, $P = 0.002$), area ($W = 733$, $P = 0.007$), pigment granules ($W = 1137$, $P = 0.001$) and NDR

($W = 1245$, $P < 0.001$), and microgametocyte width ($W = 284$, $P < 0.001$) and NDR ($W = 541$, $P < 0.001$). The slight differences seen between *H. jenniae* LARDOM01 from kelp gulls and the *H. jenniae* from the Hartlaub's gull might indicate that they belong to different parasite lineages.

The morphology of the parasites from the kelp gulls sampled at Robben Island could not be thoroughly characterized due to low parasitaemia (<10 parasites per blood film), but all parasite forms seen were consistent with *H. jenniae* as seen in the gulls sampled at rehabilitation facilities. One kelp gull (not K035/2018) and the Hartlaub's gull, both sampled at the Cape Town rehabilitation facility, had co-infection by *Babesia* sp.; morphological and molecular analyses to characterize these parasites are under way and will be presented elsewhere.

Phylogenetic analysis of a partial sequence of the *cytb* gene (Fig. 3) revealed that the studied parasite is a part of the clade consisting of *Haemoproteus* subgenus species, and it is most closely related to *H. jenniae* (CREFUR01). The *cytb* lineages LARDOM01 and CREFUR01 differed by 3 nucleotides (sequence identity = 476/479 or 99.37%). Both lineages clustered with *Haemoproteus iwa* (FREM01) from frigatebirds (*Fregata* spp.) (Fig. 3).

Redescription of Haemoproteus skuae Parsons, Peirce and Strauss, 2010.

Type host: *Catharacta antarctica* (Lesson, 1831).

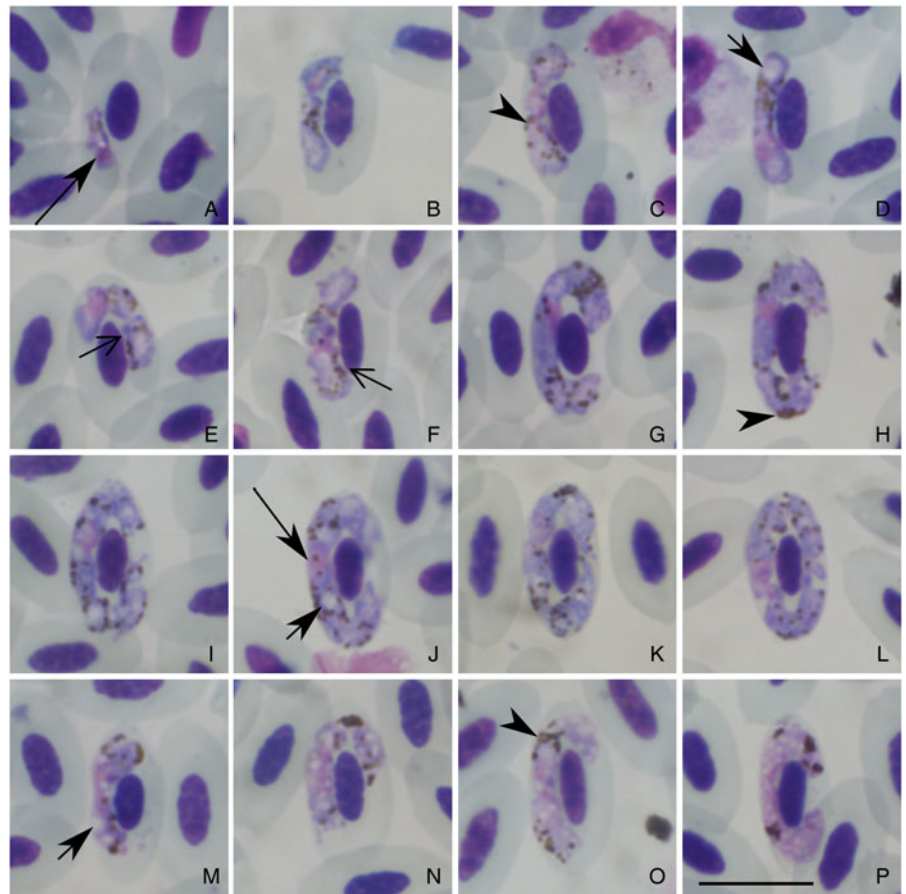


Fig. 2. *Haemoproteus jenniae* cytb lineage unknown from the blood of a Hartlaub's gull (*Larus hartlaubi*). All images from the voucher specimen IRCAH accession number G466252. Young gametocytes (A–D), macrogametocytes (E–L) and microgametocytes (M–P). Simple arrowhead, pigment granules; long simple arrow, parasite nucleus; short simple arrow, vacuole; long simple wide arrow, cleft between parasite and erythrocyte nucleus. Sample H230/2018, eosin–methylene blue stain. Scale bar = 10 μm .

Type locality: SANCCOB, Bloubaerg, South Africa.

Vector: Unknown.

Description (Fig. 4 and Table 2): The hapantotype of *H. skuae* was examined, and the following diagnostic characters were observed and complement the original description of this species.

Young gametocytes (Fig. 4A): elongated, predominantly located in a sub-polar position in the infected erythrocytes (Fig. 4A); outline is even or slightly amoeboid (Fig. 4A); they neither touch the nucleus nor the envelope of infected erythrocytes (Fig. 4A).

Macrogametocytes (Fig. 4B–L): growing forms have an even or slightly amoeboid outline (Fig. 4D–F); they extend longitudinally along the erythrocyte nuclei touching the envelope of erythrocytes but not the erythrocyte nuclei (Fig. 4B–F), forming thick distinct lateral 'clefts' (Fig. 4E, I) – a characteristic feature of this species growth; parasite nucleus is small and frequently seen in a subcentral to subterminal position (Fig. 4C). Readily visible large unfilled spaces ('clefts') are usually present between ends of advanced gametocytes and poles of erythrocyte nuclei (Fig. 4F, G, I) – also a distinctive feature of this species development. Fully grown macrogametocytes have a cytoplasm with a granular appearance (Fig. 4H); their outline varies from even to wavy (Fig. 4G, H). Nucleus is usually of central position (Fig. 4J, K), but sometimes in a subcentral position (Fig. 4H, L). Frequently seen touching or slightly touching erythrocyte nucleus (Fig. 4G, J); however, a more or less evident space between the parasites and erythrocyte nuclei was usually visible even in the largest parasites (Fig. 4K, L). Advanced forms grow around infected cell nuclei (Fig. 4J, K) and can enclose it completely (Fig. 4K–L), but often not touching the poles of erythrocytes nucleus (Fig. 4L). A single vacuole (Fig. 4K) was seen occasionally in mature macrogametocytes, but the cytoplasm was not markedly vacuolated in most gametocytes. Pigment granules were mainly of small (<0.5 μm) and

medium (0.5–1 μm) size, markedly variable in form; the roundish, oval and elongate (rod-like) granules occur; the later form is common (Fig. 4L).

Microgametocytes (Fig. 4M–P): growing forms extend longitudinally along the erythrocyte nuclei (Fig. 4M), outline is even or slightly amoeboid (Fig. 4M); the parasite does not touch the envelope or the nucleus of the host cell. Pigment granules are small (<0.5 μm) and medium (0.5–1 μm) size, mainly in roundish forms (Fig. 4M). Outline of advanced microgametocytes varies from highly amoeboid (Fig. 4N) to even (Fig. 4O–P); a single vacuole was seen in some microgametocytes (Fig. 4N, P), but the cytoplasm is not markedly vacuolated. Microgametocytes have nuclei with a highly condensed chromatin (Fig. 4M–P). Fully grown gametocytes are closely appressed to the nuclei of erythrocytes, filling the cytoplasm of the infected cells up to their poles and touching the cell envelope (Fig. 4O). Fully grown microgametocytes can encircle the erythrocyte nuclei (Fig. 4P).

Discussion

This is the first record of *H. jenniae* in Africa, and the first record of this parasite in kelp gull and Hartlaub's gull. There are only 3 previous records of *H. jenniae*. The species was described from swallow-tailed gulls at Española Island, Galapagos Islands (Levin *et al.*, 2012). DNA from *H. jenniae* was also detected in the blood of brown noddies at Rocas Atoll, off northeast Brazil, but gametocytes were not seen in blood smears (Quillfeldt *et al.*, 2014), so it remains unclear if development completes in this avian host. DNA from *H. jenniae* was also detected in the blood of black-headed gulls in Poland, although blood smears were not examined (Włodarczyk *et al.*, 2022).

Table 2. Morphometry of host cells and mature gametocytes of *H. jenniae* (cytb lineage LARDOM01) from a kelp gull (*L. dominicanus*), *H. jenniae* (cytb lineage not determined) from a Hartlaub's gull (*L. hartlaubii*), *H. jenniae* (cytb lineage CREFUR01) from a swallow-tailed gull (*C. furcatus*) and *H. skuae* (cytb lineage not determined) from a brown skua (*C. antarctica*)

Parasite (host)		<i>H. jenniae</i> (LARDOM01) ^a (<i>L. dominicanus</i>)	<i>H. jenniae</i> ^a (<i>L. hartlaubii</i>)	<i>H. jenniae</i> (CREFUR01) ^b (<i>C. furcatus</i>)	<i>H. skuae</i> ^c (<i>C. antarctica</i>)
Uninfected cells					
Sample size		30	30	21	25
Host cell	Length (μm)	13.4 ± 0.6 (12.1–14.5)	12.5 ± 0.7 (11.2–13.7)	13.3 ± 0.7 (12.0–14.7)	13.4 ± 0.7 (12.2–14.8)
	Width (μm)	6.9 ± 0.4 (6.2–7.7)	6.4 ± 0.3 (5.8–6.9)	6.8 ± 0.3 (6.4–7.3)	7.4 ± 0.4 (6.6–8.4)
	Area (μm ²)	74.2 ± 4.8 (63.2–83.6)	65.0 ± 5.1 (56.2–73.9)	72.8 ± 4.0 (63.7–79.6)	78.5 ± 6.9 (66.6–93.4)
Host cell nucleus	Length (μm)	6.3 ± 0.5 (5.5–7.2)	5.3 ± 0.4 (4.5–6.0)	6.7 ± 0.5 (5.9–7.8)	6.6 ± 0.5 (5.1–7.4)
	Width (μm)	2.5 ± 0.2 (2.0–2.9)	2.3 ± 0.1 (2.0–2.6)	2.5 ± 0.2 (2.2–2.9)	3.1 ± 0.3 (2.5–3.7)
	Area (μm ²)	12.2 ± 1.0 (10–14.5)	9.2 ± 0.8 (7.9–11.6)	14.1 ± 1.0 (12.5–16.1)	16.3 ± 2.1 (12.1–20.9)
Macrogametocytes					
Sample size		30	30	21	25
Host cell	Length (μm)	14.3 ± 0.9 (12.3–16.1)	12.8 ± 0.5 (11.5–13.8)	13.1 ± 1.2 (10.7–15.8)	13.7 ± 0.8 (12.5–15.6)
	Width (μm)	6.7 ± 0.4 (5.9–7.3)	6.3 ± 0.3 (5.6–6.9)	7.9 ± 0.7 (7.0–9.8)	7.0 ± 0.4 (6.2–7.8)
	Area (μm ²)	77.0 ± 5.8 (65–85.9)	63.7 ± 4.1 (57.5–73.0)	81.1 ± 5.1 (71.6–98.0)	75.5 ± 7.4 (61.4–95.9)
Host cell nucleus	Length (μm)	6.4 ± 0.5 (5.1–7.4)	5.2 ± 0.4 (4.5–5.7)	6.6 ± 0.3 (6.2–7.4)	5.6 ± 0.8 (3.5–7.0)
	Width (μm)	2.4 ± 0.2 (1.9–2.9)	2.3 ± 0.2 (2.0–2.6)	2.5 ± 0.3 (1.9–3.0)	2.9 ± 0.4 (2.4–3.7)
	Area (μm ²)	11.8 ± 1.3 (9.6–14.2)	8.6 ± 0.6 (6.9–9.4)	14 ± 1.3 (11.1–16.2)	12.9 ± 2.4 (9.2–18.4)
Gametocyte	Length (μm)	22.0 ± 2.1 (18.6–25.2)	22.1 ± 1.1 (19.9–24.0)	23.2 ± 1.8 (18.7–26.1)	21.1 ± 3.5 (15.6–27.5)
	Width (μm)	2.2 ± 0.3 (1.6–2.7)	2.0 ± 0.2 (1.6–2.3)	2.8 ± 0.4 (2.0–3.5)	2.1 ± 0.3 (1.7–2.8)
	Area (μm ²)	48.9 ± 5.2 (38.1–61.4)	45.5 ± 2.9 (40.4–51.7)	53.7 ± 5.2 (46.2–68.8)	46.4 ± 8.5 (35.6–66.2)
	Pigment granules	27.3 ± 3.4 (21–34)	30.6 ± 4.0 (20–38)	25.0 ± 4.4 (18–32)	27.9 ± 4.1 (20–39)
	NDR	0.9 ± 0.1 (0.7–1.1)	1.0 ± 0.1 (0.9–1.1)	0.9 ± 0.1 (0.6–1.0)	0.8 ± 4.1 (0.6–1.0)
Microgametocytes					
Sample size		20	20	21	25
Host cell	Length (μm)	14.6 ± 0.9 (13.1–16.3)	12.9 ± 0.6 (11.7–14)	13 ± 0.8 (11.7–14.2)	13.1 ± 1 (11.2–15.6)
	Width (μm)	6.7 ± 0.4 (6.1–7.6)	6.2 ± 0.5 (5.5–7.4)	7.8 ± 0.8 (6.8–8.8)	6.9 ± 0.6 (6.0–8.1)
	Area (μm ²)	79.3 ± 6.3 (65.0–93.2)	59.5 ± 14.6 (6.4–77.6)	82 ± 6.3 (69.8–90.4)	71.6 ± 8.8 (57.5–90.0)
Host cell nucleus	Length (μm)	6.5 ± 0.4 (5.6–7.1)	5.2 ± 0.5 (4.3–6.0)	6.6 ± 0.3 (6.0–7.2)	5.7 ± 0.3 (5.1–6.4)
	Width (μm)	2.4 ± 0.4 (1.9–3.9)	2.4 ± 0.2 (2.0–2.7)	2.5 ± 0.2 (2.3–2.8)	2.9 ± 0.4 (2.4–4.3)
	Area (μm ²)	12.1 ± 1.7 (10.6–18.4)	9.0 ± 1.3 (7.2–13.2)	13.7 ± 0.7 (12.6–15.8)	13.3 ± 2.2 (11.0–19.3)
Gametocyte	Length (μm)	13.7 ± 1.3 (11.8–17.2)	14.8 ± 2.0 (12.2–17.9)	20.4 ± 1.8 (17.6–23.3)	14.1 ± 2.3 (11.8–22.4)
	Width (μm)	2.3 ± 0.2 (1.9–2.8)	2.0 ± 0.2 (1.5–2.3)	2.8 ± 0.4 (2.1–3.4)	2.3 ± 0.3 (1.8–3.0)
	Area (μm ²)	34.3 ± 4.1 (28.4–46.5)	32.8 ± 4.2 (25–40.3)	51.3 ± 7.9 (40.4–62.6)	32.4 ± 6.2 (25.2–45.1)
	Pigment granules	20.6 ± 2.7 (17–27)	20.0 ± 3.7 (15–29)	20.7 ± 3.6 (13–28)	19.7 ± 3.4 (15–29)
	NDR	0.9 ± 0.1 (0.6–1.1)	1.0 ± 0.1 (0.9–1.2)	0.8 ± 0.1 (0.5–1.0)	0.8 ± 0.1 (0.4–1)

Measurements are provided: mean ± s.d. (minimum–maximum).

^aThis study.

^bLevin *et al.* (2012).

^cParsons *et al.* (2010).

Haemoproteus jenniae prevalence in this study was 19% in kelp gulls sampled at Robben Island. This is consistent with a recent study reporting a prevalence of *Haemoproteus* sp. ranging between 13 and 56% in the blood smears of adult kelp gulls sampled at other breeding colonies in South Africa (Reusch *et al.*, 2022) and with the 23% prevalence of *H. jenniae* in swallow-tailed gulls at Española Island (Levin *et al.*, 2012).

Włodarczyk *et al.* (2022) reported a 44% prevalence of DNA from *Haemoproteus* spp. in black-headed gulls in Poland; however, cytb sequencing of a subset of individuals revealed that only 4% of these infections corresponded to *H. jenniae*, therefore species-specific prevalence of *H. jenniae* in that study may be estimated at 1.8%. In comparison, DNA from *H. jenniae* was detected in 8% of brown noddies at Rocas Atoll (Quillfeldt *et al.*, 2014).

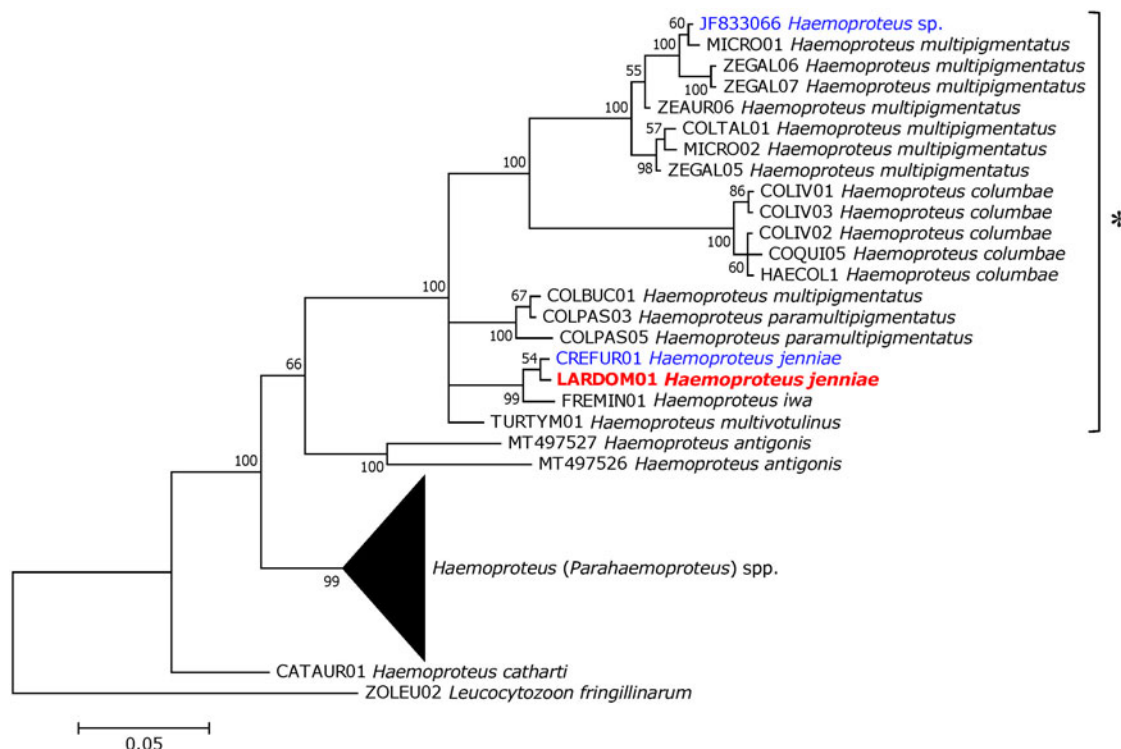


Fig. 3. Bayesian phylogenetic tree of a 479 bp fragment of the *cytb* gene of Haemosporida. Branch lengths are drawn proportionally to the extent of changes (scale bar is shown). Values adjacent to nodes represent posterior probabilities. MalAvi/GenBank accession codes are provided for each lineage. The lineage obtained in this study (red) and other *H. (Haemoproteus)* spp. lineages previously reported in seagulls (blue) are highlighted. The asterisk indicates lineages attributed to the subgenus *Haemoproteus*.

None of the free-ranging gulls or noddies infected with this parasite showed signs of illness (Levin *et al.*, 2012; Quillfeldt *et al.*, 2014). Furthermore, *Haemoproteus* sp. infection status does not have a significant effect on the body condition of kelp gulls (Reusch *et al.*, 2022), which suggests low pathogenicity at chronic infection. Because the gulls sampled at the South African rehabilitation facility in the current study had other health problems (e.g. malnutrition, botulism, trauma), it is not possible to determine the role that the infections may have played, potentially impairing their health and causing them to be brought for rehabilitation. Studies evaluating subtler signs of disease (e.g. behaviour, breeding success), physiological indicators (e.g. haematology, plasma chemistry) and tissue damage associated with tissue meronts (histopathology) will therefore be necessary to uncover the potential health effects of *H. jenniae* infections to their hosts. Additionally, it is known that some *Haemoproteus* species can cause extensive damage to organs, such as *Haemoproteus pastoris* infecting common starlings (*Sturnus vulgaris*), in which megalomeronts were reported in the brain and other organs of infected birds (Duc *et al.*, 2021). This should be taken into consideration by veterinarians in wildlife rehabilitation centres, since infected birds might present signs of disease due to the presence of *Haemoproteus* tissue stages, even if they have a low parasitaemia, or the parasitaemia is absent.

Hartlaub's gulls are endemic residents of Namibia and South Africa (BirdLife International and Handbook of the Birds of the World, 2019). Kelp gulls are widely distributed in the Southern Hemisphere, including Namibia and South Africa, and are present at the Galapagos Islands but not at Rocas Atoll (BirdLife International and Handbook of the Birds of the World, 2019). In fact, there are no records of gulls at Rocas Atoll, in contrast to the large numbers of terns and noddies that breed on the atoll (Azevedo Júnior, 1992; Schulz-Neto, 2004). The detection of DNA from *H. jenniae* in noddies at Rocas Atoll (Quillfeldt

et al., 2014) therefore suggests that this parasite is not exclusive to gulls, but probably also infects noddies and terns (which are also members of the family Laridae; Baker *et al.*, 2007). To improve our understanding of the ecology of this parasite, additional studies would be valuable to evaluate the occurrence of *H. jenniae* in other Laridae bird populations. For instance, further research is necessary to investigate whether the *Haemoproteus* sp. reported by Lowery (1971) in the blood of a brown noddy sampled at Aldabra Atoll, Indian Ocean, might have corresponded to *H. jenniae*. Further studies at sites where swallow-tailed gulls (Malpelo Island, off Colombia; BirdLife International and Handbook of the Birds of the World, 2019) and kelp gulls are present (e.g. mainland South America, Australia, New Zealand, Subantarctic islands; BirdLife International and Handbook of the Birds of the World, 2019) are of particular interest, and it would be interesting to sample other sympatric Laridae (including brown noddies) that might share this parasite. Grey-hooded gulls (*Larus cirrocephalus*) and Sabine's gulls (*Xema sabini*), whose breeding distribution overlaps with that of kelp gulls and Hartlaub's gulls in southern Africa (BirdLife International and Handbook of the Birds of the World, 2019), should also be considered as potential hosts of *H. jenniae*.

The dipteran vectors of *H. jenniae* are unknown, but hippoboscids are suspected based on its phylogenetic clustering with other species of the subgenus *Haemoproteus* (Fig. 3). This is corroborated by the fact that DNA from *H. iwa*, a parasite of frigatebirds (*Fregata* spp.) that is closely related to *H. jenniae*, was detected in *Olfersia* flies (Levin *et al.*, 2011). Species of *Olfersia* (*O. aenescens*, *O. fossulata*, *O. spinifera*) have been recorded parasitizing gulls, terns and noddies (Maa, 1969) and are plausible vectors of *H. jenniae*. Other genera of hippoboscids also known to parasitize gulls, terns and noddies comprise species of *Icosta* (*I. albipennis*, *I. americana*), *Ornithoica*

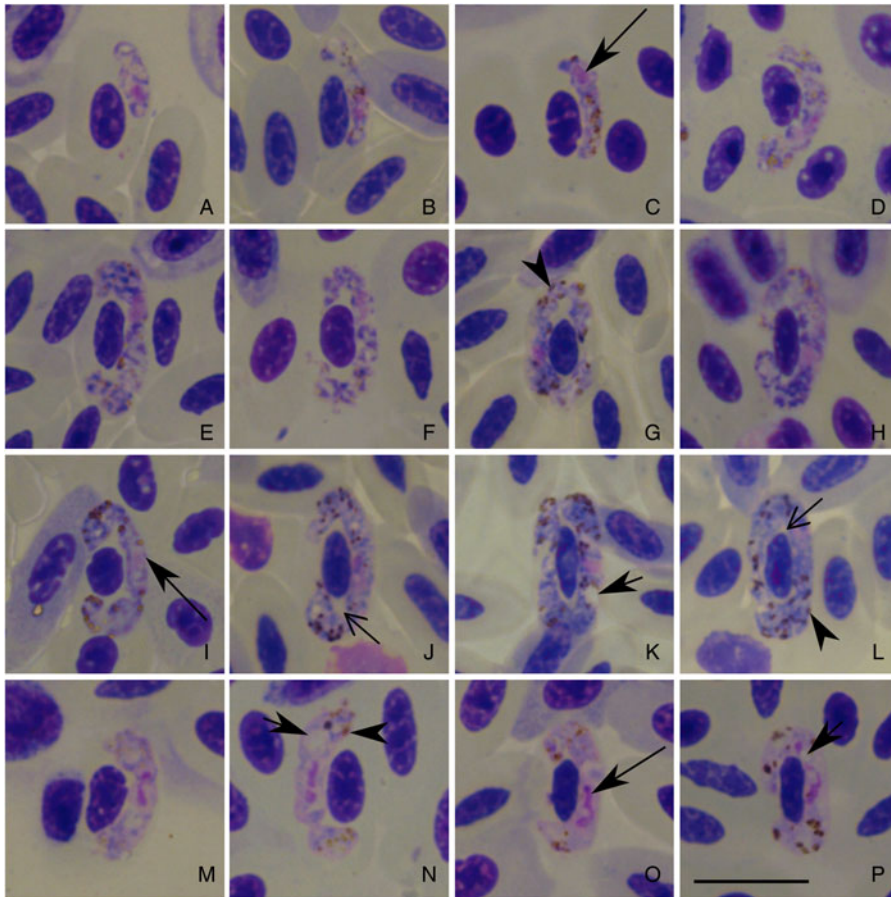


Fig. 4. *Haemoproteus skuae* from the blood of a brown skua (*Catharacta antarctica*). Young gametocyte (A), macrogametocytes (B–L) and microgametocytes (M–P). All images from the hapantotype IRCAH accession number G465379. Simple arrowhead, pigment granules; long simple arrow, parasite nucleus; short simple arrow, vacuole; long simple wide arrow, cleft between parasite and erythrocyte nucleus. Sample S02/2006, eosin-methylene blue stain. Scale bar = 10 μ m.

(*O. pusilla*), *Ornithomya* (*O. anchineuria*, *O. chloropus*) and *Ornitophila* (*O. gestroi*) (Maa, 1969; Nartshuk and Matyukhin, 2019). There is no information about the hippoboscids that parasitize gulls in South Africa, but species of *Icosta*, *Ornithoica* and *Ornithomya* have been extensively documented parasitizing South African terrestrial birds (Sychra *et al.*, 2020).

It is interesting to note that at least 5 *Haemoproteus* lineages that have been recorded in Lari birds were also detected in the blood of birds from other orders (Table 1). *Haemoproteus larvae* is a relatively common parasite of gulls and terns (Quillfeldt *et al.*, 2011; Inumaru *et al.*, 2017, 2020), and has also been demonstrated to successfully complete life cycle and develop gametocytes in the erythrocytes of penguins at a zoo (Inumaru *et al.*, 2020). There are several other instances where DNA from *Haemoproteus* sp. that infect Lari birds was detected in the blood of birds from other orders and vice versa (Ishtiaq *et al.*, 2007; Levin *et al.*, 2012; Roos *et al.*, 2015; Inumaru *et al.*, 2017; Spottiswoode *et al.*, 2020). In these instances, the detection of DNA in the blood without the demonstration of gametocyte development in erythrocytes does not necessarily indicate successful infection, as these could represent abortive infections (Valkiūnas, 2005; Moens *et al.*, 2016). Nevertheless, these instances of apparent transmission across bird orders suggest that Lari birds may be particularly susceptible to infections from *Haemoproteus* species of other avian orders and/or that the *Haemoproteus* lineages that infect Lari birds may have a particularly low host specificity.

In this context, the relationship between *H. skuae* and *H. jenniae* merits special consideration. *Haemoproteus skuae* is only known from 1 brown skua that was sampled at the same rehabilitation facility in Cape Town that was evaluated in the present study (Parsons *et al.*, 2010); the *H. skuae*-infected bird was sampled 3 days after admission to the rehabilitation facility (Parsons *et al.*, 2017), hence it seems probable that infection occurred in the wild (not while under care). There is

morphological similarity between *H. skuae* and *H. jenniae*, however, they can be readily distinguished due to several characters of their gametocytes. The following characters are worth mentioning. The cytoplasm of *H. skuae* macrogametocytes has a granular appearance (Fig. 4H), which is not the case in *H. jenniae* (Figs 1G–P and 2B–L). *Haemoproteus skuae* microgametocytes have a highly condensed chromatin (Fig. 4M–P) whereas in *H. jenniae* the chromatin is not condensed, and nuclei are diffuse (Figs 1Q–T and 2M–P). *Haemoproteus jenniae* growing gametocytes have clearly visible unstained spaces, resembling vacuoles (Figs 1D and 2A, D), but this feature is not observed in *H. skuae* (Fig. 4A, B). Additionally, growing macrogametocytes of *H. skuae* form distinct big unfilled spaces ('clefts') between parasite and the poles of erythrocyte nuclei (Fig. 4F). Even though these 'clefts' are also present in *H. jenniae* gametocytes, they are not as prominent as in *H. skuae* (cf. Figs 1N, O and 2I, K with Fig. 4F, G, I). Morphology of pigment granules is also different, with rod-like granules present in fully grown gametocytes of *H. skuae* (Fig. 4H–L), but not *H. jenniae* (Figs 1N–P and 2I–L).

Although skuas are presently considered a separate family (Stercorariidae), they were previously thought to represent a sub-family of Laridae (Olsen and Larsson, 1997), and morphological and genetic analyses show that gulls and skuas are closely related (Ericson *et al.*, 2003; Baker *et al.*, 2007; Chu *et al.*, 2009). The South African coast is home to ~17 500 kelp gulls (Whittington *et al.*, 2016) and ~16 400 Hartlaub's gulls (Du Toit *et al.*, 2003) and its coastal waters serve as important wintering grounds for brown skuas (Brooke, 1978; Ryan, 1986; Gartshore *et al.*, 1988), therefore, potentially providing opportunities for parasite transmission among these species. Furthermore, the breeding distribution of kelp gulls and brown skuas overlaps extensively in South America and at several Subantarctic islands (BirdLife International and Handbook of the Birds of the World, 2019).

It is worth noting that the hippoboscid flies *O. aenescens* and *O. chloropus* have been recorded parasitizing gulls, skuas and terns (Maa, 1968, 1969), and therefore could provide opportunities for transmission of *Haemoproteus* parasites among these hosts. It is therefore plausible that there are opportunities for cross-transmission of *H. skuae* to gulls and *H. jenniae* to skuas. Further studies on the occurrence of blood parasites in wild populations of brown skuas would be particularly valuable to provide better insight on the taxonomy and ecology of these parasites, especially considering how understudied this species is [to date, only 28 free-ranging brown skuas were examined for blood parasites (Quillfeldt *et al.*, 2011)].

In conclusion, *H. jenniae* is a relatively frequent parasite of kelp gulls in South Africa, and also infects Hartlaub's gulls. The detection of this species in South Africa represents a substantial expansion of its known distribution, and suggests it is a widely distributed parasite of Laridae seabirds. Further research is necessary to improve our knowledge about the host and geographic distribution and health effects of this species, and to clarify the taxonomic relationship between *H. jenniae* and *H. skuae*.

Supplementary material. The supplementary material for this article can be found at <https://doi.org/10.1017/S003118202300029X>.

Data availability. Voucher specimens were deposited at the International Reference Centre for Avian Haematozoa (IRCAH) of the Queensland Museum in Australia (accession codes G466232 and G466252). The *cytb* sequence produced in this study was deposited in GenBank (accession code OL906299) and MalAvi (lineage LARDOM01).

Acknowledgements. We would like to thank the staff and volunteers of SANCCOB. We also would like to thank Dr Mal Bryant from the Queensland Museum for providing access to the reference slide of *Haemoproteus skuae* that was used in this study.

Author's contribution. RETV, NJP and PAP conceived and designed the study. RETV, NJP, DGR, AS, RH and KL collected the biological samples and data. RETV, NJP, DGR, AS and RH screened blood smears. NJP, AS and KL curated the archival samples. RETV, CRFC and GV conducted morphological analyses of parasites. CCA and KK conducted molecular analyses of parasites. RETV, CRFC and GV prepared the first draft. All authors reviewed, edited and approved the final version of the manuscript.

Financial support. SANCCOB is supported by a wide range of donors, including ABAX Investments, Bristol Conservation Foundation, Cheyenne Mountain Zoo, Columbus Zoological Park, Georgia Aquarium, Hans Hoheisen Charitable Trust, International Fund for Animal Welfare, Leiden Conservation Foundation, the National Lottery Distribution Trust Fund, Sea Research Foundation (Mystic Aquarium) and SeaWorld and Busch Gardens. K. K. is a CNPq research fellow (309396/2021-2). Additionally, this study was supported by the National Research Foundation (NRF) and the South African National Antarctic Programme (SANAP).

Conflict of interest. The authors declare that they have no conflict of interest in relation to this article.

Ethical standards. This study was conducted under permits from the Department of Environmental Affairs (RES2012/61EXT, RES2016/18, RES2017/56) and CapeNature (AAA007-00047-0056, AAA004-0508-0035, AAA004-000120-0035, AAA007-00040-0035), and under the approval of the University of Cape Town Animal Ethics Committee (2014/V18/SCNP2).

References

Azevedo Júnior SM (1992) Observação de aves oceânicas e limícolas na Reserva Biológica do Atol das Rocas. *Cadernos Ômega Série Ciências Aquáticas, Recife* 3, 49–58.

Baker AJ, Pereira SL and Paton TA (2007) Phylogenetic relationships and divergence times of Charadriiformes genera: multigene evidence for the Cretaceous origin of at least 14 clades of shorebirds. *Biology Letters* 3, 205–210.

Bennett GF and Campbell A (1972) Avian Haemoproteidae. I. Description of *Haemoproteus fallisi* n. sp. and a review of the haemoproteids of the family Turdididae. *Canadian Journal of Zoology* 50, 1269–1275.

Bensch S, Hellgren O and Pérez-Tris J (2009) MalAvi: a public database of malaria parasites and related haemosporidians in avian hosts based on mitochondrial cytochrome b lineages. *Molecular Ecology Resources* 9, 1353–1358.

Berdyev KS (1979) K faune kroveparazitov dikikh ptits Yuzhnogo Turkmenistana. *Razvitie Parazitologicheskoi Nauki Turkmenistane. Ashkhabad*, 156–162.

BirdLife International and Handbook of the Birds of the World (2019) Bird species distribution maps of the world. Version 2019.1. *Birdlife Data Zone*.

Borner J, Pick C, Thiede J, Kolawole OM, Kingsley MT, Schulze J, Cottontail VM, Wellinghausen N, Schmidt-Chanasit J, Bruchhaus I and Burmester T (2016) Phylogeny of haemosporidian blood parasites revealed by a multi-gene approach. *Molecular Phylogenetics and Evolution* 94, 221–231.

Bosch M, Figuerola J, Cantos FJ and Velarde R (1997) Intracolony differences in the infestation by *Haemoproteus lari* on yellow-legged gulls *Larus cachinnans*. *Ornis Fennica* 74, 102–112.

Brooke R (1978) The *Catharacta* skuas (Aves: Laridae) occurring in South African waters. *Durban Museum Novitates* 11, 295–308.

Chu PC, Eisenschek SK and Zhu S-T (2009) Skeletal morphology and the phylogeny of skuas (Aves: Charadriiformes, Stercorariidae). *Zoological Journal of the Linnean Society* 157, 612–621.

Clark NJ, Clegg SM and Lima MR (2014) A review of global diversity in avian haemosporidians (*Plasmodium* and *Haemoproteus*: Haemosporida): new insights from molecular data. *International Journal for Parasitology* 44, 329–338.

Cracraft J, Barker FK and Cibois A (2003) Avian higher-level phylogenetics and the Howard and Moore checklist of birds. In Dickinson EC, Bahr N, Dowsett R, Pearson D, Remsen V, Roselaar CS and Schodde D (eds), *The Howard and Moore Complete Checklist of Birds of the World*. Princeton: Princeton University Press, pp. 16–21.

Darriba D, Taboada GL, Doallo R and Posada D (2012) jModelTest 2: more models, new heuristics and parallel computing. *Nature Methods* 9, 772–772.

Duc M, Ilgūnas M, Kubiliūnaitė M and Valkiūnas G (2021) First report of *Haemoproteus* (Haemosporida, Haemoproteidae) megalomeres in the brain of an avian host, with description of megalomeres of *Haemoproteus pastoris*, the blood parasite of the common starling. *Animals* 11, 2824.

Du Toit M, Boere G, Cooper J, De Villiers M, Kemper J, Lenten B, Petersen S, Simmons R, Underhill L and Whittington P (2003) *Conservation Assessment and Management Plan for Southern African Coastal Seabirds*. Cape Town: Avian Demography Unit, Conservation Breeding Specialist Group.

Ericson PG, Envall I, Irestedt M and Norman JA (2003) Inter-familial relationships of the shorebirds (Aves: Charadriiformes) based on nuclear DNA sequence data. *BMC Evolutionary Biology* 3, 16.

Franchini G (1924) Observations sur les hématozoaires des oiseaux d'Italie. *Annales de l'Institut Pasteur* 38, 470–515.

Gartshore N, Cooper J and Hunter S (1988) Bird ringing at Marion and Prince Edward Islands, 1982–1987; with an analysis of movements since 1951. *South African Journal of Antarctic Research* 18, 23–29.

Gering E and Atkinson CT (2004) A rapid method for counting nucleated erythrocytes on stained blood smears by digital image analysis. *Journal of Parasitology* 90, 879–881.

Gill F, Donsker D and Rasmussen P (2022) IOC World Bird List Version 11.2. doi: 10.14344/IOC.ML.12.1.

Hellgren O, Waldenström J and Bensch S (2004) A new PCR assay for simultaneous studies of *Leucocytozoon*, *Plasmodium*, and *Haemoproteus* from avian blood. *Journal of Parasitology* 90, 797–802.

Inumaru M, Murata K and Sato Y (2017) Prevalence of avian haemosporidia among injured wild birds in Tokyo and environs, Japan. *International Journal for Parasitology: Parasites and Wildlife* 6, 299–309.

Inumaru M, Aratani S, Shimizu M, Yamamoto M, Sato Y, Murata K and Valkiūnas G (2020) Penguins are competent hosts of *Haemoproteus* parasites: the first detection of gametocytes, with molecular characterization of *Haemoproteus larvae*. *Parasites & Vectors* 13, 307.

Ishtiaq F, Gering E, Rappole JH, Rahmani AR, Jhala YV, Dove CJ, Milensky C, Olson SL, Peirce MA and Fleischer RC (2007) Prevalence of avian haemosporidia among injured wild birds in Tokyo and environs, Japan. *Journal of Wildlife Diseases* 43, 382–398.

- Jovani R, Tella JL, Forero MG, Bertellotti M, Blanco G, Ceballos O and Donázar JA (2001) Apparent absence of blood parasites in the Patagonian seabird community: is it related to the marine environment? *Waterbirds* **24**, 430–433.
- Kairullaev KK (1986) Blood parasites (*Haemoproteus* Kruse, 1890) in birds of Kazakh-SSR, USSR. *Izvestiya Akademii Nauk SSSR Seriya Biologicheskaya* **4**, 39–42.
- Krams I, Suraka V, Rattiste K, Äboliš-Äbols M, Krama T, Rantala MJ, Mierauskas P, Čirule D and Saks L (2012) Comparative analysis reveals a possible immunity-related absence of blood parasites in common gulls (*Larus canus*) and black-headed gulls (*Chroicocephalus ridibundus*). *Journal of Ornithology* **153**, 1245–1252.
- Levin II, Valkiūnas G, Santiago-Alarcon D, Cruz LL, Iezhova TA, O'Brien SL, Hailer F, Dearborn D, Schreiber EA, Fleischer RC, Ricklefs RE and Parker PG (2011) Hippoboscid-transmitted *Haemoproteus* parasites (Haemosporida) infect Galapagos Pelecaniform birds: evidence from molecular and morphological studies, with a description of *Haemoproteus iwa*. *International Journal for Parasitology* **41**, 1019–1027.
- Levin II, Valkiūnas G, Iezhova TA, O'Brien SL and Parker PG (2012) Novel *Haemoproteus* species (Haemosporida: Haemoproteidae) from the swallow-tailed gull (Lariidae), with remarks on the host range of Hippoboscid-transmitted avian Hemoproteids. *Journal of Parasitology* **98**, 847–854.
- Lowery RS (1971) Blood parasites of vertebrates on Aldabra. Philosophical Transactions of the Royal Society of London B: *Biological Sciences* **260**, 577–580.
- Maa T (1968) Records of Hippoboscidae (Diptera) from the central Pacific. *Journal of Medical Entomology* **5**, 325–328.
- Maa T (1969) A revised checklist and concise host index of Hippoboscidae (Diptera). *Pacific Insects Monographs* **20**, 261–299.
- Martínez-Abraín A, Merino S, Oro D and Esparza B (2002) Prevalence of blood parasites in two western-Mediterranean local populations of the yellow-legged gull *Larus cachinnans michahellis*. *Ornis Fennica* **79**, 34–40.
- Martínez-Abraín A, Esparza B and Oro D (2004) Lack of blood parasites in bird species: does absence of blood parasite vectors explain it all. *Ardeola* **51**, 225–232.
- Matta NE, Pacheco MA, Escalante AA, Valkiūnas G, Ayerbe-Quiñones F and Acevedo-Cendales LD (2014) Description and molecular characterization of *Haemoproteus macrovacuolatus* n. sp. (Haemosporida, Haemoproteidae), a morphologically unique blood parasite of black-bellied whistling duck (*Dendrocygna autumnalis*) from South America. *Parasitology Research* **113**, 2991–3000.
- Moens MAJ, Valkiūnas G, Paca A, Bonaccorso E, Aguirre N and Pérez-Tris J (2016) Parasite specialization in a unique habitat: hummingbirds as reservoirs of generalist blood parasites of Andean birds. *Journal of Animal Ecology* **85**, 1234–1245.
- Nartshuk EP and Matyukhin AV (2019) The louse flies *Ornithophila metallica* (Schiner, 1864) and *O. gestroi* (Rondani, 1878) (Diptera, Hippoboscidae): distribution and association with birds in the Palaearctic. *Entomological Review* **99**, 504–507.
- Olsen KM and Larsson H (1997) *Skuas and Jaegers: A Guide to the Skuas and Jaegers of the World*. New Haven: Yale University Press.
- Padilla LR, Whiteman NK, Merkel J, Huyvaert KP and Parker PG (2006) Health assessment of seabirds on Isla Genovesa, Galápagos Islands. *Ornithological Monographs* **60**, 86–97.
- Parsons NJ, Peirce MA and Strauss V (2010) New species of haematozoa in Phalacrocoracidae and Stercorariidae in South Africa. *Ostrich* **81**, 103–108.
- Parsons NJ, Voogt NM, Schaefer AM, Peirce M and Vanstreels RET (2017) Occurrence of blood parasites in seabirds admitted for rehabilitation in the Western Cape, South Africa, 2001–2013. *Veterinary Parasitology* **233**, 52–61.
- Peirce MA (1981) Haematozoa of British birds: VI. Redescription of *Haemoproteus larae* Yakunin from the lesser black-backed gull *Larus fuscus*. *Journal of Natural History* **15**, 459–462.
- Perkins SL (2014) Malaria's many mates: past, present, and future of the systematics of the order Haemosporida. *Journal of Parasitology* **100**, 11–25.
- Quillfeldt P, Martínez J, Hennie J, Ludynia K, Gladbach A, Masello JF, Riou S and Merino S (2010) Hemosporidian blood parasites in seabirds – a comparative genetic study of species from Antarctic to tropical habitats. *Naturwissenschaften* **97**, 809–817.
- Quillfeldt P, Arriero E, Martínez J, Masello JF and Merino S (2011) Prevalence of blood parasites in seabirds – a review. *Frontiers in Zoology* **8**, 26.
- Quillfeldt P, Martínez J, Bugoni L, Mancini PL and Merino S (2014) Blood parasites in noddies and boobies from Brazilian offshore islands – differences between species and influence of nesting habitat. *Parasitology* **141**, 399–410.
- Reusch K, Ryan PG and Pichegru L (2022) Health status indices of kelp gull populations in South Africa. *Emu – Austral Ornithology* **122**, 216–225.
- Ricklefs RE and Fallon SM (2002) Diversification and host switching in avian malaria parasites. *Proceedings of the Royal Society of London, Series B: Biological Sciences* **269**, 885–892.
- Ronquist F, Teslenko M, Van Der Mark P, Ayres DL, Darling A, Höhna S, Larget B, Liu L, Suchard MA and Huelsenbeck JP (2012) MrBayes 3.2: efficient Bayesian phylogenetic inference and model choice across a large model space. *Systematic Biology* **61**, 539–542.
- Roos F, Belo N, Silveira P and Braga E (2015) Prevalence and diversity of avian malaria parasites in migratory black skimmers (*Rynchops niger*, Laridae, Charadriiformes) from the Brazilian Amazon Basin. *Parasitology Research* **114**, 3903–3911.
- Ruiz X, Oro D and González-Solís J (1995) Incidence of a *Haemoproteus lari* parasitemia in a threatened gull: *Larus audouinii*. *Ornis Fennica* **72**, 159–164.
- Ryan PG (1986) Records of skuas and Sabine's gulls ashore in southern Africa. *Marine Ornithology* **13**, 107–111.
- Sambrook J and Russell D (2001) *Molecular Cloning: A Laboratory Manual*, 3rd Edn. Cold Spring Harbor, New York: Cold Spring Harbor Laboratory Press.
- Schneider CA, Rasband WS and Eliceiri KW (2012) NIH image to ImageJ: 25 years of image analysis. *Nature Methods* **9**, 671–675.
- Schulz-Neto A (2004) Aves marinhas do Atol das Rocas. In Branco JO (ed.), *Aves Marinhas e Insulares Brasileiras: Biologia e Conservação*. Itajaí: Editora da Univali, pp. 169–192.
- Spottiswoode N, Bartlett SL, Conley KJ, Seimon TA, Griffin DO and Sykes JM (2020) Analysis of *Plasmodium* lineages identified in captive penguins (Sphenisciformes spp.), eiders (*Somateria* spp.), and inca terns (*Larosterna inca*) in a North American zoological collection. *Journal of Zoo and Wildlife Medicine* **51**, 140.
- Sychra O, Halajian A, Engelbrecht D, Symes CT, Oschadleus HD, de Swardt DH and Papoušek I (2020) Louse-flies (Diptera: Hippoboscidae) of birds from South Africa: prevalence and diversity. *African Entomology* **28**, 249–261.
- Valkiūnas G (2005) *Avian Malaria Parasites and Other Haemosporidia*. Boca Raton: CRC Press.
- Whittington PA, Crawford RJM, Martin AP, Randall RM, Brown M, Ryan PG, Dyer BM, Harrison KHB, Huisamen J, Makhado AB, Upfold L, Waller LJ and Witteveen M (2016) Recent trends of the kelp gull (*Larus dominicanus*) in South Africa. *Waterbirds* **39**, 99–113.
- Włodarczyk R, Bouwhuis S, Bichet C, Podlaskczuk P, Chyb A, Indykiewicz P, Dulisz B, Betleja J, Janiszewski T and Minias P (2022) Contrasting haemoparasite prevalence in larid species with divergent ecological niches and migration patterns. *Parasitology* **149**, 1479–1486.
- Yakunin MP (1972) Blood parasites of wild birds of south-east Kazakhstan. *Trudy Instituta Zoologii Akademii Nauk Kazakhskoi SSR* **33**, 69–79.