

LETTER TO THE EDITOR**TO THE EDITOR****Always in Tune: The Unforgettable Memory for Music in Alzheimer's Disease**

Keywords: Alzheimer's disease, memory, clinical neurology, music

Musical creativity is a complex skill that is dependent upon auditory and visual processing, fine motor skills and memory for music. It is likely distinct from verbal and visual memory.¹ Studies on music and cognition suggest that language and music share contiguous neural substrates; however, they also report cases of selective impairment between the forms of communication.² Although these forms of communication are distinct and inherently challenging to compare, the dissociation between the two functions is an interesting one to investigate, as it may have implications for our understanding of cognitive reserve in neurodegeneration.

In our previous study on a professional pianist with Alzheimer's disease (AD), we observed intact episodic memory for music and an ability to learn music despite severe disturbances in logical memory of verbal information.³ We also investigated whether the amateur musical competence in two patients with AD is sufficient to replicate these findings.

An 87-year-old male right-handed retired lawyer, fluent in four languages and with 10 years of formal music training starting in middle school and who regularly plays the piano, was evaluated for possible dementia. At age 84, he began to develop memory impairment for names, objects and places, and he had visuospatial disorientation and executive dysfunction. During our study, his speech was fluent with normal prosody. He had anosmia, but the rest of his neurological exam was normal. His Montreal Cognitive Assessment (MoCA) score was 10/30, and his Mini-Mental Status Examination (MMSE) was 13/30, with deficits in multiple areas (see Table 1 for a breakdown of the scores). A brain CT scan revealed moderate to severe generalized atrophy (Figure 1).

His diagnosis was probable AD of moderate severity, and donepezil was prescribed.

An 82 year-old female right-handed bilingual retired pharmacist with five years of piano lessons starting in high school came to our clinic after her family noticed that she had developed progressive forgetfulness, word-finding problems, visuospatial disorientation and problems performing everyday tasks since the age of 78. The patient was unaware of her difficulties. Her speech and prosody were normal. Apart from anosmia, there were no other neurological abnormalities. A brain CT scan revealed diffuse generalized atrophy (Figure 1). During our study, both her MoCA and MMSE scores were 19/30 (see Table 1 for a breakdown of scores). Her diagnosis was probable AD, and donepezil was prescribed.

Both patients were submitted to a single-blinded study in their homes for seven consecutive days upon receiving St. Michael's Hospital Research Ethics Board approval and written informed consent. Each day, we assessed their capacity to learn and memorize verbal information from the Anna Thompson story from the Wechsler Memory Scale⁴ and eight bars of music from a grade 5 conservatory-level piece entitled "The Winter Scene." The patients denied ever having heard or played this piece prior to our study, and the caregivers confirmed that they had never witnessed the patients listening to or playing the piece. The patients were first allowed to read the story silently and listen to the story being dictated. After 1 and 15 minutes, we prompted a verbal recall of the story. Patients were given a composite raw score, which allocated a point for every story element in both the immediate and delayed recalls. Likewise, patients were asked to listen to a live performance of eight bars of "The Winter Scene" and then asked to sightread the material, which involved reading and playing the music with both hands for the first time (an innate step in becoming accustomed to a piece in classical training). Although this step is different from the verbal stimulus presentation, it was

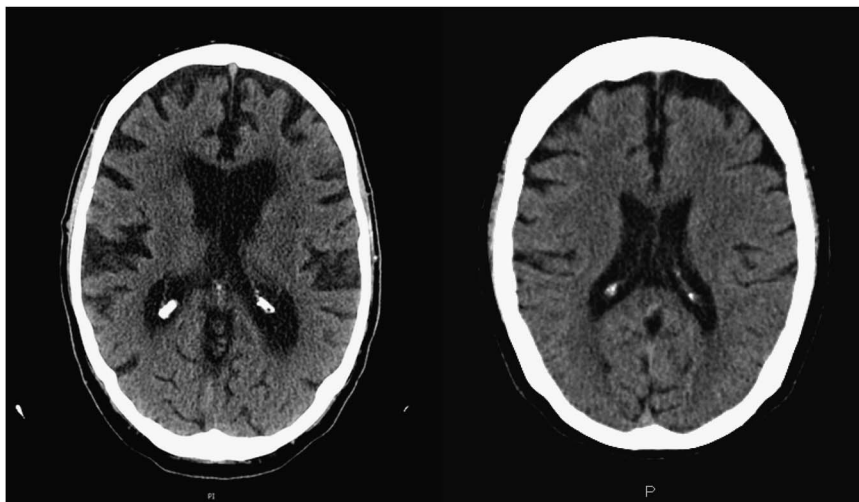


Figure 1: Mid-axial brain CT for Patient 1 (left) and Patient 2 (right).

(a) Original

With grace and delicacy $\text{♩} = 50 - 54$

p cantabile

a tempo

rit.

mp

a tempo

rit.

p espressivo

ritro. 1
meno emotivo

Right hand

Left hand

1 bar

(b) Day 1- Patient 1 delayed recall

p

(c) Day 7- Patient 1 delayed recall

p

(d) Day 7- Patient 2 delayed recall

Figure 2: Musical material learned over a 7-day period: original, 15-minute recall (patient 1, day 1), 15-minute recall (patient 1, day 7), and 15-minute recall (patient 2, day 7).

necessary as classically trained amateur musicians only learn how to be acquainted with their music through sightreading, not through auditory “playback” learning. Patients were brought into another room between exposure to the story or piece and its recollection in order to prevent them from practicing the stimulus. We again prompted recall of the music after 1 and 15 minutes. The testing order was counterbalanced, and caregivers ensured that no repetition of the material was taking place between sessions.

Both patients exhibited poor logical memory performance at the onset that failed to improve. In contrast, both had intact music sightreading skills and improvement in their delayed memory for music, both in terms of number of hands and the number of bars recalled (Figure 2). The first patient, with more experience, learned to recall four musical bars with both hands by the seventh day. He was aware of his musical errors and, when improvising, maintained the key of the piece, thereby demonstrating proficient understanding of the musical parameters. The second patient had no musical recollection on the first day but was able to recall four bars of music with her right hand by the last day.

As in previous publications on professional musicians,³ our two amateur pianists showed marked dissociations in memory preservation for music and verbal information. Despite differences in methodology, neuroimaging and lesion studies conducted on memory for music report bilateral activation within the auditory association areas of the superior temporal gyrus, and in the inferior and middle frontal regions.^{2,5} While AD initially targets temporal areas, bilateral frontal brain region activity might be compensating for these functions. We propose that the multimodal nature of musical performance recruits a broad neural network involving primary sensory and motor regions with complex interactions involving association areas, frontal regions and emotional networks. Through practice, these interactions may become more efficient⁶ and resist or compensate for deficits from neurodegeneration. While both patients are multilingual and highly educated, factors that foster increased cognitive reserve,⁶ they do not explain the selective preservation of memory for music.

We adopted a sightreading approach for music learning, which is the standard practice in the field of music. To further dissociate

Table 1A: Breakdown of MoCA scores for both patients

Patient	Visuospatial/ executive	Naming	Attention	Language	Abstraction	Delayed recall	Orientation
1	2/5	2/3	1/6	0/3	1/2	0/5	4/6
2	4/5	2/3	6/6	1/3	1/2	0/5	5/6

Table 1B: Breakdown of MMSE scores for both patients

Patient	Orientation	Registration	Attention	Recall	Language
1	5/10	0/3	1/5	2/3	2/9
2	8/10	1/3	4/5	0/3	6/9

the effects of visual and auditory exposure on memory, future studies might benefit from replicating our study with amateur musicians who are trained “by ear,” meaning that they can play music by listening to a tune without the need for sightreading. This will improve the comparison between the two types of memory. Nevertheless, our pilot study does highlight some interesting findings in amateur musicians with AD.

Understanding the effects of neurodegenerative processes on creative output has been an evolving area of interest, showing a wide range of associations—from an increase in creativity in the famous case of an artist with frontal temporal dementia,⁷ to preservation of creativity in AD, and diminished divergent thinking in dementia.⁸ Future studies using neuroimaging should help to further elucidate the neural substrates involved in retention of creativity in amateur musicians or artists with dementia.

ACKNOWLEDGEMENTS

We would like to acknowledge the Eric and Heather Donnelly Endowment for funding our research.

FUNDING

St. Michael’s Hospital Foundation, and the Eric and Heather Donnelly Endowment.

DISCLOSURES

Ann Mansur has the following disclosures: St. Michael’s Hospital Foundation, the Heather and Eric Donnelly Endowment, endowment recipient. Kevin O.M Acuna, Tom Schweizer, Corinne Fischer and Luis Fornazzari have nothing to disclose.

STATEMENT OF AUTHORSHIP

AM and KO conducted the study, analyzed the data and wrote the manuscript. TS, CF and LF inspired the concept, established the protocol, analyzed the data and critically evaluated the manuscript. CF and LF conducted the clinical history and patient evaluations.

Luis Fornazzari

*The Keenan Research Centre for Biomedical Science
The Li Ka Shing Knowledge Institute at St. Michael’s Hospital*

30 Bond Street, Toronto, Ontario, Canada, M5B 1W8

Email: forna@rogers.com

Ann Mansur

*The Keenan Research Centre for Biomedical Science
The Li Ka Shing Knowledge Institute at St. Michael’s Hospital
Toronto, Ontario, Canada*

Kevin O.M Acuna

*The Keenan Research Centre for Biomedical Science
The Li Ka Shing Knowledge Institute at St. Michael’s Hospital
Toronto, Ontario, Canada*

Tom A. Schweizer

*The Keenan Research Centre for Biomedical Science
The Li Ka Shing Knowledge Institute at St. Michael’s Hospital
Toronto, Ontario, Canada*

Corinne E. Fischer

*The Keenan Research Centre for Biomedical Science
The Li Ka Shing Knowledge Institute at St. Michael’s Hospital
Toronto, Ontario, Canada*

REFERENCES

- Baird A, Samson S. Memory for music in Alzheimer’s disease: unforgettable? *Neuropsychol Rev.* 2009;19(1):85-101; Epub ahead of print Feb 13.
- Sergent J, Zuck E, Terriah S, MacDonald B. Distributed neural network underlying musical sight-reading and keyboard performance. *Science.* 1992;257(5066):106-9.
- Fornazzari L, Castle T, Nadkarni S, Ambrose M, Miranda D, Apanasiewicz N, et al. Preservation of episodic musical memory in a patient with Alzheimer’s disease. *Neurology.* 2006;66(4):610-1.
- Wechsler D. *Wechsler Memory Scale, 3rd ed.* New York: The Psychological Corporation; 1997.
- Platel H, Baron JC, Desgranges B, Bernard F, Eustache F. Semantic and episodic memory of music are subserved by distinct neural networks. *NeuroImage.* 2003;20(1):244-56.
- Schweizer TA, Ware J, Fischer CE, Craik FIM, Bialystok E. Bilingualism as a contributor to cognitive reserve: evidence from brain atrophy in Alzheimer’s disease. *Cortex.* 2012;48:991-6; Epub ahead of print Apr 27, 2011.
- Seeley WW, Matthews BR, Crawford RK, Gorno-Tempini ML, Foti D, Mackenzie IR, et al. Unravelling Bolero: progressive aphasia, transmodal creativity and the right posterior neocortex. *Brain.* 2008;131(Pt 1):39-49; Available at: <http://brain.oxfordjournals.org/content/brain/131/1/39.full.pdf>.
- Palmiero M, Giacomo DD, Passafiume D. Creativity and dementia: a review. *Cogn Process.* 2012;13(3):193-209; Epub ahead of print Mar 22.