

MALFORMATIONS OF THE UMBILICAL CORD

BL. KONSTANTINOVA

Central Laboratory of Teratology, Medical Academy, Sofia, Bulgaria

In 184 autopsies of death newborns, stillborn infants and aborted fetuses (mostly with congenital malformations), 57 (30.98%) umbilical cord anomalies were discovered (38 M and 19 F): 19 cases with knots (10.32%), 17 with arterial agenesis (9.2%), 8 with focal fibrosis of Wharton's jelly (4.34%), 7 with varices and thrombosis (3.8%), and 6 (3.25%) with other anomalies. Thirtyone of the fetuses were born from first pregnancy, 32 were stillborn and 26 premature.

INTRODUCTION

Whenever umbilical cord malformations are discussed, usually reference is made to false and rare true knots, as well as abnormally long or short umbilical cord, leading to marginal or velamentous insertion. Usually, the false knots and marginal insertion are being overlooked, unlike the true knots and velamentous insertion which may occasionally exert a deleterious effect on fetal circulation. Teratologists who are supposed to be aware of all variations in congenital malformation cases should be interested not merely in the above mentioned umbilical cord malformations, but also in varices and absence of vessels, and in the histomorphological character of Wharton's jelly as well, similar to those discovered in our series.

MATERIAL AND METHODS

In the reviewed case material comprising 184 autopsied death newborns, stillborn and aborted fetuses (mostly with heavy malformations), a total of 57 cases with umbilical cord defects (30.98%) were discovered. Both congenital developmental malformations of the fetus and umbilical cord defects were recorded more frequently in boys (39) than in girls (19).

Material for histological investigation was obtained from three umbilical cord zones. After staying, usually for 10 days, in 7% neutral formalin, parafin sections were prepared, stained with Hemalaun-eosin for microscope study. Whenever the cadavers were available, chromosomal analysis was also performed.

RESULTS

Umbilical cord defects in the series under study were assigned to five distinct groups: (1) Umbilical artery agenesis (SUA); (2) Umbilical cord knots (true and false) (UCK); (3) Varices of umbilical vessels (VUV); (4) Focal noninflammatory fibrosis of Wharton's jelly (FUW), and (5) Special group. The latter comprises 6 cases: giant umbilical cord with four umbilical arteries, detected in anencephaly; umbilical cord in ischiopagus containing two arteries and two veins (Fig. 6); two giant umbilical cords found in anencephalus and

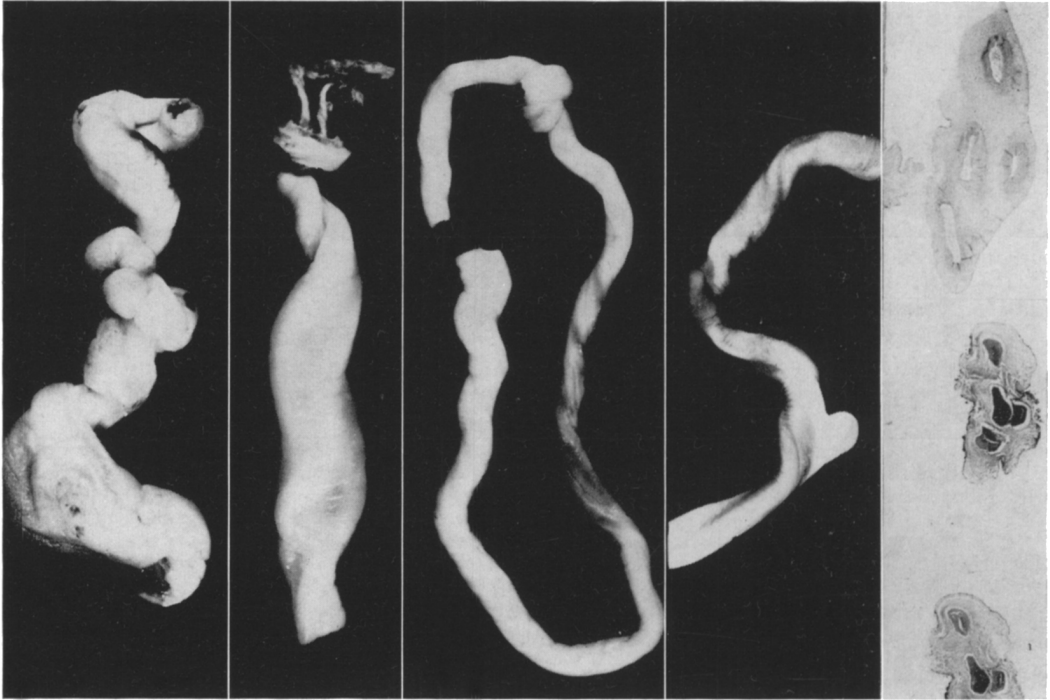


Fig. 1

Fig. 2

Fig. 3

Fig. 4

Fig 5 and 6

Fig. 1. Giant umbilical cord with a single artery, varices and thrombosis of the vessels. – Fig. 2. Giant umbilical cord. – Fig. 3. Umbilical cord with a true knot. – Fig. 4. Umbilical cord, flattened, with a single artery and false knot. – Fig. 5. Umbilical cord with four blood vessels. – Fig. 6. Umbilical cord (ischio-pagus) with two arteries and two veins, running a course in a common bed, close to each other.

hydrocephalus; two cases with long and wide abdominal umbilical vessels, discovered in porencephalia and inherited affection; inadequately built up umbilical cord wall, found in heavy malformations and chromosomal mosaicism (46,XY/47,XY,+16), and short umbilical cord adherent to the amnion along its full length, observed in severe monstrosity associated with three-type chromosomal mosaicism (46,XX/47,XX,+16/45,XO) (Fig. 7).

Umbilical artery agenesis (SUA) (Figs. 1, 4 and 10). Although more than four centuries have passed since the publication of the first observation and description of agenesis of the umbilical artery (Gabriele Falloppio and Caspar Bauhini), it continues to be the subject of researches because of the complexity of the numerous problems it raises, such as incidence, familial character and etiology, sex dependence and maternal age, congenital malformations and prematurity, perinatal lethality, whether or not it should be considered as a trait not manifested at birth, and the like.

According to the various authors, SUA is met in 1.1% (Vleitnick et al. 1972) or in 0.72% (Brayan and Kohler 1974) of newborns; it is more frequent in males (Hyrtl 1870, Konstantinova 1961, Vleitnick et al. 1972); has a 14% incidence in severe congenital malformations (Vleitnick et al. 1972), or even of 17.5% (Brayan and Kohler 1974), which is in line with

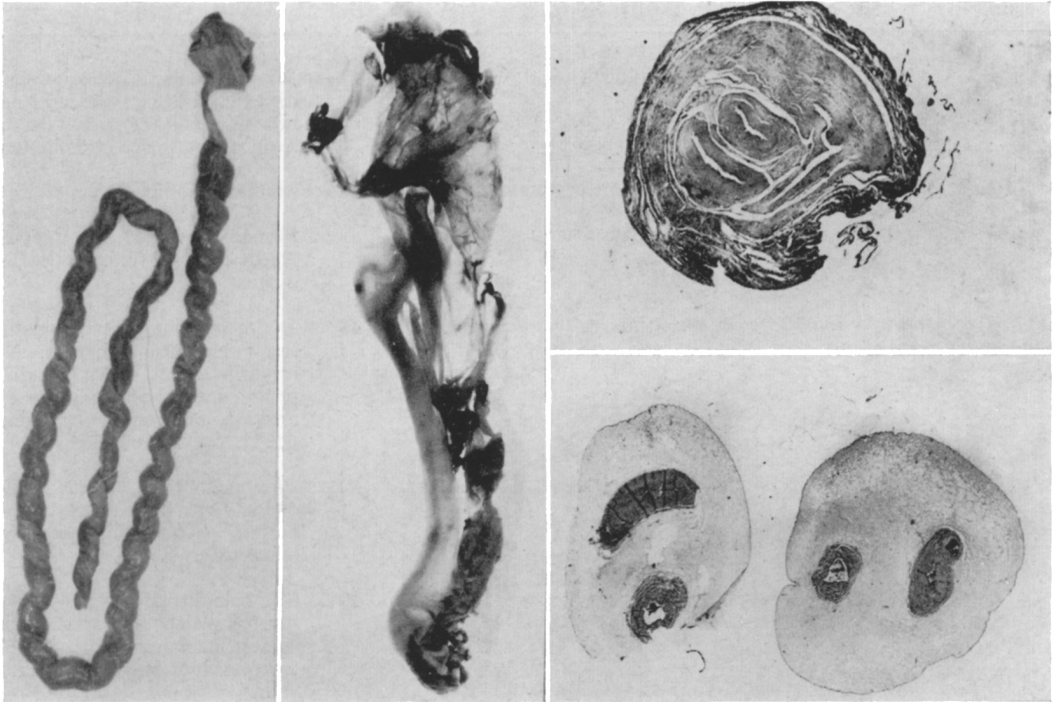


Fig. 7

Fig. 8

Fig. 9 and 10

Fig. 7. A long umbilical cord with focal noninflammatory fibrosis of Wharton's jelly. – Fig. 8. Short umbilical cord (16.5 cm) adherent to the amnion along its full length. – Fig. 9. Histological (macro-micro) section from the fibrous area of No. 7. – Fig. 10. Histological (macro-micro) section from umbilical cord with single artery.

our results. Sirenoform fetuses, according to literature and personal data, are invariably associated with SUA.

Table 1 shows that 1/2 of SUA cases under study are born from first pregnancy, 2/3 are still-born, and almost all of them are premature infants.

Varices and thrombosis of umbilical cord vessels (VUV) (Fig. 1). Table 2 shows that all instances of varices and thrombosis of umbilical vessels result in heavy malformations and stillborn infants.

Focal, noninflammatory fibrosis of Wharton's jelly (FUW) (Figs. 8 and 9). Table 3 shows that all such instances result in premature, stillborn infants with advanced maceration. Five of the mothers have undergone retention treatment.

Umbilical cord knots (false and true) (UCK) (Figs. 3 and 4). Table IV shows that, in 6 cases with heavy malformations, false and true knots are present. The remainder (14) are found in saline-aborted fetuses.

The problems of intrauterine and perinatal lethality in congenital malformations and prematurity require thorough investigation of the umbilical cord in each fetus.

Table 1. Malformations found in infants with umbilical artery agenesis (SUA)

Case no.	Sex	Gestat. age (wk)	Age at death	Weight (g)	Length (cm)	Malformations
1	F	34	Stillbirth	2000	47	Microcephalia. Cheilognatopalatoschisis manducatoria cum agenesiam septi nasi. Anophthalmia bilateralis. Polydactylia mani utriusque. Truncus arteriosus communis. Uterus duplex
2	M	24	Stillbirth	1200	28	Malformationes extremitatum
3	M	39	5 days	2700	49	Mongoloidism (47,XY,+21). Palatum fissum. Agnesia septi interventriculorum. Ren duplex
4	M	35	Stillbirth	3200	48	Hydrocephalus. Agnesia radii et pollicis dextri. Polycystosis renarum. Agnesia vesicae urinariae, scroti et hypospadias. Atresia oesophagi, ani et intestini. Agnesia rami dexteri arteriae pulmonalis et agnesia pulmonis dextri. Agonadismus.
5	M	28	Stillbirth	1100	40	Monopedius. Agnesia radii sinistri et digiti duam mani. Atresia ani. Agnesia vesicae urinariae et organorum genitalium externarum.
6	M	30	3 hours	1500	45	Mongoloidism (47,XY,+21). Agnesia vesicae urinariae et vesicae urinariae. Transpositio ventriculorum principales cordis et defectus septi interventriculorum. Pes valgus
7	M	16	Stillbirth	950	24	Anencephalus. Eventratio hepatis
8	M	38	Stillbirth	2000	46	Anencephalus
9	M	40	2 days	3100	48	Exencephalia. Agnesia penis
10	M	40	Stillbirth	5000	51	Twin conjoined
11	F	40	2 days	3730	51	Cheilognatopalatoschisis superior bilateralis. Vitium cordis
12	M	28	Stillbirth	1850	37	Anencephalia et rachischisis. Anophthalmia sinistra
13	F	37	Stillbirth	2100	43	Microcephalia et agnesia partis cerebri superioris. Palatoschisis. Atresia ani. Ren polycystosus utriusque. Agnesia septi interventriculorum
14	M	19	Stillbirth	1200	38	Monobrachius (agnesia brachii sinistri). Anencephalia cum cyclopiam. Eventratio organorum omnia. Cheilognatopalatoschisis inferior. Agnesia lienis et atresia ani
15	F	24	Stillbirth	1500	32	Anencephalia et rachischisis
16	F	40	16 days	2900	49	Truncus arteriosus communis. Aplasia glandulae thymi et parathyreoideae
17	M	28	Stillbirth	1500	38	Monopedius. Atresia ani et intestini. Agnesia renarum, vesicae urinariae et organorum genitalium externarum

Remarks	Age of mother	Pregnancy	Notes on mother's history
	26	First	
	22	First	Antitetanic vaccine administered in the beginning of pregnancy
Hydramnion	36	Second	Nephropathia gravidarum
	22	First	Throughout the full course of pregnancy she received Validol and Disepan, and later Biseptol and Hexacitron in addition
Hydramnion	27	First	She was given Tetraolean and other drugs
	26	Second	Works in environment with proved ionizing radiation. She was in contact with a rubeola patient
Hydramnion	24	First	
Hydramnion	28	First	
Hydramnion	Uncertain		
	18	First	Subjected to treatment because of epilepsy
Hydramnion	23	Fourth	
Hydramnion	36	Fourth	Works with crude oil products
Hydramnion	28	Second	Nephropathia gravidarum. Intimate contact with a rubeola child
	24	First	Cholera vaccine, and influenza with respective treatment in the past history
	25	Fifth	High doses of Aspirin and Analgin
	42	Third	
Hydramnion	25	Second	Since the age 2 years she suffers from diabetes mellitus and was subjected to insulin treatment. Retention treatment

Table 2. *Malformations found in infants with varices and thrombosis (VUV)*

Case no.	Sex	Gestat. age (wk)	Age at death	Weight (g)	Length (cm)	Malformations
1	F	40	Stillbirth	3500	52	Hydrocephalia
2	M	40	Stillbirth	3600	50	Hydrocephalus. Spina bifida aperta. Atresia ani et recti. Eventratio
3	M	40	Stillbirth	2670	50	Anencephalus
4	M	36	Stillbirth	2800	48	Cheilognatopalatoschisis mediana. Cor tunculare. Pes valgus. Pterigium coli
5	M	36	Stillbirth	2800	50	Hydrocephalus. Agenesia vermi et hemisphaerae sinistrae cerebelli. Focomelia et amputatio intrauterina mani sinistri et agenesia digitorum II pedis sinistri
6	M	38	19 days	3350	50	Mongoloidism (47,XY,+21/46,XY) Morbus Roget. Agenesia glandulae thymi et parathyreoideae
7	F	40	Stillbirth	3150	50	Hydrocephalia. Agenesia vermi et hypoplasia hemisphaerae sinistrae cerebelli. Atresia ani. Pes valgus. Spina bifida
8	F	37	Stillbirth	2200	48	Sans cou. Agenesia renis dextri

Table 3. *Malformations found in fetus with fibrosis circumscripta (FUW)*

Case no.	Sex	Gestat. age (wk)	Age at death	Weight (g)	Length (cm)	Malformations
1	F	30	Stillbirth	1000	35	Anencephalia. Maceratio foeti
2	M	24	Stillbirth	850	30	Maceratio foeti
3	M	20	Stillbirth	720	28	Atresia cardiacae. Agenesia glandulae thymi. Pes valgus. Maceratio foeti
4	M	28	Stillbirth	900	32	Maceratio foeti
5	F	29	Stillbirth	1100	30	Anophthalmia sinistra et exophthalmus dextri. Maceratio foeti
6	M	24	Stillbirth	800	28	Maceratio foeti
7	F	9	Stillbirth	Uncertain		Maceratio foeti

Table 4. *Malformations found in infants with knots (UCK)*

Case no.	Sex	Gestat. age (wk)	Age at death	Weight (g)	Length (cm)	Malformations
1	M	33	Stillbirth	1600	39	Atresia oesophagii et uretrae. Hydrocephalus bilateralis. Morbus Roget. Pes valgus
2	F	40	Stillbirth	1100	30	Anencephalia et rachischisis. Magna coarctatio umbilicalis cum true knot et 5 vasa
3	F	24	Stillbirth	1500	30	Anencephalia. Malformatio nasi
4	F	14	Stillbirth	Uncertain		Maceratio foeti. True knot cordae umbilicalis
5	F	40	Stillbirth	3000	45	Anencephalia et rachischisis
6	M	35	Stillbirth	1800	40	Hydrocephalus. Spina bifida cystica. Pes valgus
7	M	40	Living	3800	50	Knot true cordae umbilicalis

Remarks	Age of mother	Pregnancy	Notes on mother's history
	33	Second	Retention treatment
	32	Third	Works in environment saturated with ionizing radiation
Hydramnion	25	Second	
	23	First	
	29	First	
	25	Third	
	20	First	
Hydramnion	22	First	Pregnancy period under conditions of intensive noise – at the airport. Both she and her husband underwent treatment

Remarks	Age of mother	Pregnancy	Notes on mother's history
	25	Second	
	34	Sixth	
	21	Fourth	Retention treatment
	22	First	Retention treatment
	38	Second	
	33	Second	
	20	First	

Remarks	Age of mother	Pregnancy	Notes on mother's history
Hydramnion	26	Second	Retention treatment
Hydramnion	Uncertain		
Hydramnion	17	First	
	24	Fourth	
	20	First	
	27	First	
	23	First	

REFERENCES

- Brayan E.M., Kohler H.G. 1974. The missing umbilical artery. *Arc. Dis. Child.*, 49: 844-852.
- Hyrtil Y. 1870. Die Blutgefäße der menschlichen Nachgeburt in normalen und abnormalen Verhältnissen. Vienna: Braumüller.
- Konstantinova Bl.P. 1961. Zur Frage des Zusammenhanges zwischen der Fehlentwicklung der Nabelgefäße und der Entwicklung angeborener Missbildungen. *Zentralbl. Allg. Pathol. Pathol. Anat.*, 103: 61.
- Vleitnick R.F., Thiery M., Orye E., De Clercq A., Van Vaerinbergh P. 1972. Significance of the single umbilical artery. A clinical, radiological, chromosomes and dermatoglyphic study. *Arch. Dis. Child.*, 47: 639.

RIASSUNTO

Malformazioni del Cordone Ombelicale

Su di un totale di 184 autopsie di neonati morti, nati-morti ed aborti (per lo più con malformazioni congenite), sono state riscontrate 57 (30.98%) anomalie del cordone ombelicale (38 M e 19 F): 19 casi con nodi (10.32%), 17 con agenesia delle arterie (9.2%), 8 con infiammazione della gelatina di Wharton (4.34%), 7 con varici e trombosi (3.8%) e 6 con altre anomalie (3.25%). Dei feti, 31 erano primi nati, 32 nati-morti e 26 prematuri.

RÉSUMÉ

Malformations du Cordon Ombilical

Sur un total de 184 autopsies de nouveaux-nés morts, morts-nés et avortements (généralement avec des malformations congénitales), 57 (30.98%) anomalies du cordon ombilical (38 M et 19 F) ont été trouvées: 19 cas avec nœuds (10.32%), 17 avec agénésie artérielle (9.2%), 8 avec inflammation de la gélatine de Wharton (4.34%), 7 avec varices et thromboses (3.8%) et 6 avec d'autres anomalies (3.25%). Trente et un fœtus étaient premiers-nés, 32 morts-nés et 26 prématurés.

ZUSAMMENFASSUNG

Mißbildungen der Nabelschnur

Die Autopsie von insgesamt 184 gestorbenen Neugeborenen, Totgeburten oder Aborten (meist mit angeborenen Mißbildungen) ergab bei 57 (30,98%) Fällen Anomalien der Nabelschnur (38 M und 19 W) und zwar: 19 (= 10,32%) Knoten, 17 (= 9,2%) Arterienagenesien, 8 (= 4,34%) Entzündungen der wharton'schen Sulze, 7 (= 3,8%) Varizen oder Thrombosen, und 6 (= 3,25%) andere Anomalien. 31 Foeten waren Erst-, 32 Tot- und 26 Frühgeburten.

Prof. Bl. Konstantinova, Belo More St. 8, Sofia-1527, Bulgaria.