

Magnetic resonance imaging abnormalities in young euthymic patients with bipolar affective disorder

SELIM M. EL-BADRI, DAVID A. COUSINS, SEAN PARKER,
HEATHER C. ASHTON, VICTOR L. McALLISTER, I. NICOL FERRIER
and P. BRIAN MOORE

Summary Temporal lobe and limbic structures may be abnormal in bipolar disorder. T2-weighted magnetic resonance imaging (MRI) scans frequently show deep white matter lesions. MRI was performed on 50 young (19–39 years) euthymic patients with bipolar disorder and 26 controls. Mean temporal lobe volumes were reduced in patients (right, 9.42 cm³; left, 6.33 cm³) but this could not be ascribed to a specific structure. Deep white matter lesions were present in 5 patients but no controls raising questions of their aetiological significance.

Declaration of interest None.

Support from Stanley Medical Research, Bethesda, MD, USA.

Despite many magnetic resonance imaging (MRI) studies of the temporal lobe in bipolar disorder, consistent findings are yet to emerge. Early findings of reduced temporal lobe volumes remain unconfirmed (Swayze *et al*, 1992; Altshuler *et al*, 2000). Deep and periventricular white matter lesions observed on T2-weighted MRI scans are 3.3 times more prevalent in bipolar disorder (Altshuler *et al*, 1995), although they are present in only a minority of patients. Here we compare temporal lobe and ventricular volumes and deep white matter lesions in young, physically healthy euthymic patients with bipolar disorder and controls.

METHOD

We invited 121 patients with bipolar I disorder attending clinics in north-east England to participate in the study. After assessment and explanation of the study's aims and methods, 53 gave written informed consent. Three were excluded because of scanning difficulties, leaving 50 (15 males; mean age 30.2 years (s.d.=6.2,

range 20–39); mean illness duration 8.9 years (s.d.=3.3)) to complete the study. We recruited 26 controls (13 males, 13 females; mean age 30.2 years (s.d.=6.2, range 20–39), with no current or past psychiatric disorder matched for mean age and premorbid IQ (NART; Nelson, 1982).

Patients met DSM-IV criteria (American Psychiatric Association, 1994) for bipolar I disorder only and had experienced at least two episodes of illness. Exclusion criteria (Moore *et al*, 2001a) designed to eliminate white matter abnormalities unrelated to bipolar disorder were applied to patients and controls. Both groups were euthymic at the time of scanning; this was confirmed by a mental state examination supplemented by the Beck Depression Inventory (Beck *et al*, 1961).

Axial T2-weighted, coronal inversion recovery and sagittal, coronal and axial T1 scans were recorded using a General Electrics (Slough, UK) MR max plus 0.5 tesla scanner. Details of volumetric measurements from coronal inversion recovery scans have been published previously (Moore *et al*, 2001a). The rostral limit of the temporal lobe was taken to be the last slice showing the Sylvian fissure.

Intracranial volumes could not be measured directly. Head size was measured as the product of three mutually perpendicular skull diameters, the posterior–anterior diameter, the left–right diameter and the vertical height of the skull above the sella. White matter hyperintensities on MRI were evaluated independently by two investigators. Only hyperintensities present on both T2 and proton density scans and, for deep white matter lesions at least 3 mm in diameter, were included. Investigators were in complete agreement about whether an individual scan showed deep or periventricular white matter lesions. Scans were rated using the scale of Fazekas *et al* (1993).

Data were analysed using the statistical package Minitab 10.2 for Windows (Minitab Inc., Pennsylvania, USA). Data that were

normally distributed were analysed using ANOVA and Student's *t*-test. A Bonferroni correction was applied, making $P \leq 0.007$ significant and $0.05 > P > 0.007$ a trend.

RESULTS

Patients had smaller temporal lobe volumes than controls (left, mean 54.9 cm³ (s.d.=9.9) *v.* 61.3 (s.d.=8.3), $F=7.7$, $P=0.007$ and right, mean 59.5 cm³ (s.d.=10.8) *v.* 68.1 (s.d.=8.2), $F=12.55$, $P=0.001$) with right volumes being greater than left (paired $t=7.28$, $P<0.001$) (Fig. 1). Lateral ventricle volumes did not differ between patients and controls (left, mean 8.7 cm³ (s.d.=4.3) *v.* 8.0 (s.d.=2.8) and right, mean 8.21 cm³ (s.d.=4.4) *v.* 7.3 (s.d.=2.4). Illness ($F=9.81$, $P=0.003$) and gender ($F=7.37$, $P=0.008$) contributed significantly to differences in temporal lobe volume. *Post hoc* pairwise comparisons of temporal lobe volumes in males, females, patients and controls found significantly ($F=9.3$, $P=0.003$) smaller left volumes (mean 52.2 cm³ (s.d.=8.8)) in female than male (mean 61.0 cm³ (s.d.=9.6)) patients. There were trends ($0.05 > P > 0.007$) for female patients to have smaller temporal lobes (left or right) than controls, and for the right temporal lobes of female patients to be smaller than those of males ($F=4.99$, $P=0.03$).

Age and skull volume may be confounding variables. Age was similar in patient and control groups and was not a significant confounder. When temporal lobe volumes were analysed using a general linear model with illness presence and gender as categorical variables and head size as covariate (with interactions allowed), the adjusted left mean temporal lobe volumes of patients (55.7 cm³ (s.d.=1.6)) and controls (61.7 cm³ (s.d.=1.6)) differed significantly ($F=13.8$, $P<0.001$). An interaction between illness group and head size contributed significantly ($F=12.4$, $P=0.001$) to the left temporal lobe volume variance.

Similarly, the adjusted right mean temporal lobe volume in patients (60.0 cm³ (s.d.=1.7)) was smaller ($F=10.6$, $P=0.002$) than in controls (68.5 (s.d.=1.8)). Again an interaction between illness group and head size parameter was observed ($F=10.6$, $P=0.002$). No other group/covariate interactions significantly contributed to the variance of left or right temporal lobe volumes.

Deep white matter lesions were observed in 5 out of 50 patients (10%) but

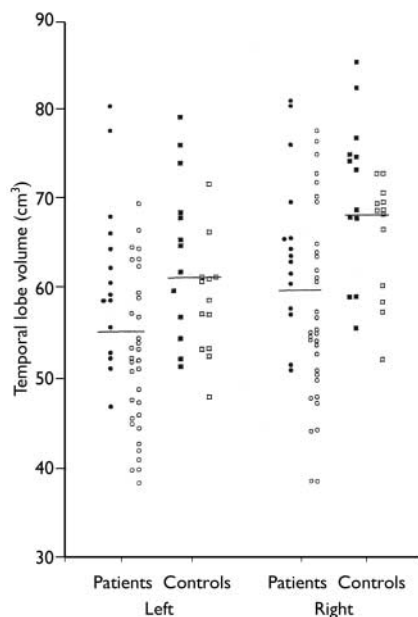


Fig. 1 Left and right temporal lobe volumes in patients and controls. ●, male patient; ■, male control; ○, female patient; □, female control.

no controls (Fisher's exact test, two-tailed, $P=0.115$). Two were graded as 2 (moderate severity) and three were graded as 1 (mild) on the Fazekas scale. Two patients with deep white matter lesions had periventricular white matter lesions (Fazekas grade 3 and 1). No controls exhibited white matter abnormalities.

DISCUSSION

Patients with bipolar disorder had significantly reduced right and left temporal lobe volumes even after controlling for skull volumes. Our mean temporal lobe volume in males (125.6 cm^3 (s.d.=18.9)) agrees well with a recently published value (139.5 cm^3 (s.d.=15.5)) despite differences in MRI methods and problems defining the temporal lobe rostral boundary (Altshuler *et al*, 2000).

Published, mixed-gender studies of bipolar disorder have reported smaller (Swayze *et al*, 1992), unchanged (Hauser *et al*, 2000) or increased (Harvey *et al*, 1994) temporal lobe volumes. Altshuler *et al* (2000) were unable to replicate an earlier finding of reduced temporal lobe volume in males. We found temporal lobe volume reductions predominantly in females, which may explain differences in male only and mixed-gender studies.

Generalised or specific structural atrophy, changes in grey/white matter

SELIM M. EL-BADRI, MD, DAVID A. COUSINS, MRCP, MRCPsych, SEAN PARKER, MRCP, HEATHER C. ASHTON, FRCP, Department of Psychiatry, University of Newcastle upon Tyne, Royal Victoria Infirmary, Newcastle upon Tyne; VICTOR L. McALLISTER, FRCP, Department of Neuroradiology, Newcastle General Hospital; I. NICOL FERRIER, MD, FRCP, FRCPsych, P. BRIAN MOORE, PhD, FRCPsych, Department of Psychiatry, University of Newcastle upon Tyne, UK

Correspondence: Dr P. B. Moore, Department of Psychiatry, University of Newcastle upon Tyne, Royal Victoria Infirmary, Queen Victoria Road, Newcastle upon Tyne NE1 4LP, UK. Email: P.B.Moore@ncl.ac.uk

(First received 16 March 2005, accepted 5 May 2005)

density, or abnormal temporal lobe neurodevelopment could cause reduced temporal lobe volumes. Measured mean hippocampal and amygdala volumes lie in the ranges of $2.0\text{--}3.8 \text{ cm}^3$ and $1.3\text{--}3.4 \text{ cm}^3$, respectively (Swayze *et al*, 1992; Altshuler *et al*, 2000). As these are much less than our measured reductions in temporal lobe volumes, such reductions could not result solely from hypoplasticity of the amygdala and hippocampus. Although patients exhibited minimally enlarged lateral ventricles, this was not statistically significant. Thus, there was little evidence of generalised cerebral atrophy in young patients with bipolar disorder, adding to the consensus of negative studies (Soares & Mann, 1997). Grey matter density may be reduced by up to 9.6% and might contribute to reduced temporal lobe volume (Lim *et al*, 1999).

We are confident that the deep white matter lesions observed in 10% ($P=0.115$) of patients are linked to bipolar disorder. In this and an earlier study with similar exclusion criteria (Moore *et al*, 2001a), deep white matter lesions were absent in controls under 50 years, reinforcing the association, albeit weak, between the lesions observed here and bipolar disorder. Furthermore, studies of younger (or first-episode) patients (Swayze *et al*, 1992; Strakowski *et al*, 1993) also showed a non-significant 10% frequency of deep white matter lesions. Supporting these observations, post-mortem studies have reported microtubule protein and oligodendrocyte abnormalities in bipolar disorder (for review see Harrison, 2002), which may contribute to the formation of deep white matter lesions.

The low prevalence of deep white matter lesions suggests that they have a limited but unknown contribution to the pathogenesis of bipolar disorder. Associations with winter birth (Moore *et al*, 2001b), cognitive difficulties (Dupont *et al*, 1995) and especially treatment resistance (Moore *et al*, 2001a) may provide starting points for future examination of their importance.

REFERENCES

- Altshuler, L. L., Curran, J. G., Hauser, P., *et al* (1995) T_2 hyperintensities in bipolar disorder: magnetic resonance comparison and literature meta-analysis. *American Journal of Psychiatry*, **152**, 1139–1144.
- Altshuler, L. L., Bartzokis, G., Grieder, T., *et al* (2000) An MRI study of temporal lobe structures in men with bipolar disorder or schizophrenia. *Biological Psychiatry*, **48**, 147–162.
- American Psychiatric Association (1994) *Diagnostic and Statistical Manual of Mental Disorders* (4th edn) (DSM-IV). Washington, DC: APA.
- Beck, A. T., Ward, C. H., Mendelson, M., *et al* (1961) An inventory for measuring depression. *Archives of General Psychiatry*, **4**, 561–571.
- Dupont, R. M., Jernigan, T. L., Heindel, I. W., *et al* (1995) Magnetic resonance imaging and mood disorders. Localisation of white matter and other subcortical abnormalities. *Archives of General Psychiatry*, **52**, 747–755.
- Fazekas, F., Kleinert, R., Offenbacher, H., *et al* (1993) Pathologic correlates of incidental MRI white matter signal intensities. *Neurology*, **43**, 1083–1089.
- Harrison, P. J. (2002) The neuropathology of primary mood disorders. *Brain*, **125**, 1248–1449.
- Harvey, I., Persaud, R., Ron, M. A., *et al* (1994) Volumetric MRI measurements in bipolars compared with schizophrenics and healthy controls. *Psychological Medicine*, **24**, 689–699.
- Hauser, P., Matochik, J., Altshuler, L. L., *et al* (2000) MRI-based measurements of temporal lobe and ventricular structures in patients with bipolar I and bipolar II disorders. *Journal of Affective Disorders*, **60**, 25–32.
- Lim, K. O., Rosenbloom, M. J., Faustman, W. O., *et al* (1999) Cortical gray matter deficit in patients with bipolar disorder. *Schizophrenia Research*, **40**, 219–227.
- Moore, P. B., Shepherd, D. J., Eccleston, D., *et al* (2001a) Cerebral white matter lesions in bipolar affective disorder: relationship to outcome. *British Journal of Psychiatry*, **178**, 172–176.
- Moore, P. B., El-Badri, S. M., Cousins, D., *et al* (2001b) White matter lesions and season of birth of patients with bipolar affective disorder. *American Journal of Psychiatry*, **158**, 1521–1524.
- Nelson, H. E. (1982) *National Adult Reading Test (NART)*. Windsor: NFER–Nelson.
- Soares, J. G. & Mann, J. M. (1997) The anatomy of mood disorders – review of structural neuroimaging studies. *Biological Psychiatry*, **41**, 86–106.
- Strakowski, S. M., Wilson, D. R., Tohen, M., *et al* (1993) Structural brain abnormalities in first-episode mania. *Biological Psychiatry*, **33**, 602–609.
- Swayze, V. W., Andreasen, N. C., Alliger, R. J., *et al* (1992) Subcortical and temporal structures in affective disorder and schizophrenia: A magnetic resonance imaging study. *Biological Psychiatry*, **31**, 221–240.